

## Comparative Study of Lip Print between Multigender Community using Suzuki Classification

Vijayalakshmi V.<sup>1</sup>, Priyanka Verma<sup>2</sup>, Rohith M.<sup>3</sup>

### How to cite this article:

Vijayalakshmi V., Priyanka Verma, Rohith M., Comparative Study of Lip Print between Multigender Community using Suzuki Classification. Ind J Forensic Odontol 2023;16(2):47-56.

### Abstract

A crucial part of forensic investigations is personal identification. Lip prints, a unique pattern in the labial mucosa, can be studied used in chelioscopy. These prints can vary in each person, making them admissible in courts. Homosapiens can change their gender through hormone therapy, and progesterone exposure can be related to high non-heterosexual self-esteem. This study explores the interdisciplinary landscape of forensics, material science, and medicine, addressing gender identities like lesbian, gay, bisexual, non-binary gender, and gender queer using there lip traces. In chelioscopy technique lip wrinkles are to identify suspect/victim in cases of crime where clues left like lip print traces in the cases like rape, bulgarly etc... Since lip prints are distinct and even identical in twins, they are useful in the investigation of crimes. Lip print analysis is crucial since it can reroute cases because it's a sensitive shift among people.

**Aims and Objectives:** The current study's objectives were to assess the most common lip grooves among the three genders (male, female, and LGBT) and improve the effectiveness of crime solving.

**Keywords:** Gender; Lip prints; Similarity; Crime solving.

## INTRODUCTION

Chelioscopy is a method used to study the red part of the lip, known as vermilion borders and tubercles, which is anatomical. It was first

recommended by Edmond Locard and later by Le Moyne Snyder in 1950. Suzuki and Y. Tsuchihashi developed six types of lip print classification, which can be used in crime scene solving. However, crime solving becomes more complicated due to the well-vised techniques used by criminals, such as using gloves to hide fingerprints and using acid to destroy sperm traces in cases of rape. This makes crime solving more risky due to the difficulty in detecting clues and traces in crime scenes. Therefore, the use of chelioscopy remains a crucial tool in crime scene investigation.<sup>1,2</sup> Cheiloscopy can be used to view lip prints, which are identifiable creases and grooves in the region where the inner labial mucosa and outer skin meet.<sup>3</sup> Lip print is crucial evidence in crime investigations, identifying the suspect's age, gender, race, and sex. It can be found in various

**Author's Affiliations:** <sup>1,3</sup>Student, <sup>2</sup>Associatae Professor, Department of Forensic Science, University Institute of Applied Health Science, Chandigarh University, Punjab 140413, India.

**Corresponding Author:** Vijayalakshmi V., Student, Department of Forensic Science, University Institute of Applied Health Science, Chandigarh University, Punjab 140413, India.

**E-mail:** vijiveerasamy12@gmail.com

**Received on:** 18.03.2024

**Accepted on:** 20.04.2024

locations, including clothes, coffee butts, water glasses, windows, and victims' bodies, often used in postmortem and anti-mortem comparisons'. Fischer, an anthropologist,<sup>13</sup> was the first one to have this bio-optical phenomenon in 1902.

During pregnancy, distinctive cells merge to form the brain and tissues form unique face features like lips, which vary during the fourth and seventh week. Lip prints are used by the FBI and Illinois state police as a positive means of identification, similar to fingerprints, DNA, postmortems,<sup>5</sup> and recent reports, to solve crimes and obtain justice in legal proceedings. The contour of lips can also vary according to cosmetic surgery preferences. Lip prints are found on various objects, such as cutlery, letters, cigarettes, napkins, and mirrors, and can be used to show latent prints at crime scenes. They are found in murder, rape, and burglaries. These prints cannot be altered until the person recovers from trauma or an infection like herpes. Japanese scientists Kazuo Suzuki and Yasuo Tsuchihashi studied lip grooves between 1968 and 1971, and an investigation on unioocular twins in 1971. Lip print structures can be full, top heavy, wide, round, bottom heavy, thin, bow-shaped, heartshaped, or downturned. Negroes have large lips due to their adaptation to high temperatures. Large lips are particularly prevalent in tropical regions.<sup>7</sup> Lips are often categorized by thickness, with Europeans having thin lips, Asians medium or mixed, and Africans or blacks having thick or large lips. Hormonal changes can influence physical characteristics and external identities, but also interior and fundamental identities. Lips acquire grooves and finger ridge shifts, and lip print includes multiple patterns.

Lysochrome is a dye used in histochemistry to stain lipids, such as triglycerides, fatty acids, and lipoproteins, which can be used to demonstrate latent prints at crime scenes. Lip prints, often found in murder, rape, or burglary, remain permanent until the person recovers from trauma or an infectious disease. Japanese researchers Kazuo Suzuki and Yasuo Tsuchihashi used lip grooves to categorize species near the border between 1968 and 1971. Lip print structures can be full, top-heavy, wide, round, bottom-heavy, thin, bow-shaped, heart-shaped, or downturned. African-Americans have adapted to high temperatures through big lips, which are more common in the tropics. Lip thickness is a common criterion for grouping<sup>4,6</sup> lips, with Africans or (negroes) typically having thick or excessively huge lips, while Europeans and Asians are more likely to

have medium-sized or mixed-sized lips. Biometric measurement has become crucial in various fields, including schools, colleges, and workplaces. Since 1988, passports have included biometric details such as face lip and cornea nose length, name, gender, age, place of residence, date of birth, and more. Malaysia was the first country to release a biometric passport, which includes corneal size, pupil color, fingerprint, hair color, head position, and length between nose and lip. This specific measure prevents smiles and spectacles, allowing criminals and terrorists to issue biometric passports and travel to avoid fraud.<sup>8</sup>

## MATERIAL AND METHODOLOGY

The study was conducted among different genders like male, female, Lesbian, gay, bisexual and transgender of 2 geographical locations of Chandigarh and Kerala with total sample number of 170 samples which includes 50 male, 50 female, 15 each in lesbian, gay and bisexual, 25 transgender. Excluded criteria are (1) persons with lip scar, (2) person with hypersensitivity of lip (3) lip lesion (4) lip congenital deformities.

The participants in the study are given a detailed explanation of the goals and methodology, and their agreement is obtained.

*The following supplies were utilised to record the lip groove pattern:* red lipstick, white paper, cellophane tape, and magnifying glass technique of Costa Caldas.<sup>9</sup>

Before the operation, the patient's lips were cleansed with a moist tissue. Using ten evenly spaced bud tips, the lipstick was applied gently, and participants were encouraged to wiggle their lips and remain relaxed throughout the process. Additionally, the lip is pressed up against the paper, and the lip print is secured with cellophane tape. Lip groove patterns were divided into six categories: lower right, lower left, lower middle, upper left, and upper middle. According to Suzuki and Tsuchiashi's classification, the analysis was completed.<sup>11-13</sup> The following is the classification: Type I: vertically oriented, clearly carved grooves across the lips; Type II: The grooves are straight but vanish halfway through. of completely encasing the lip's breath; Type III: grooves intersect; Type II: grooves branch in their course Type IV: reticular grooves; Type V: Grooves cannot be distinguished morphologically and do not fall into any of the types I through IV.




Fig. 1: Materials for chelioscopy collection. 1-magnifying lens, 2-tissue paper, 3-ear buds, 4-lip gloss and lip stick, 5 scissors, 6-scale, 7-sample paper, 8-pen/pencil, 9-cello tape.

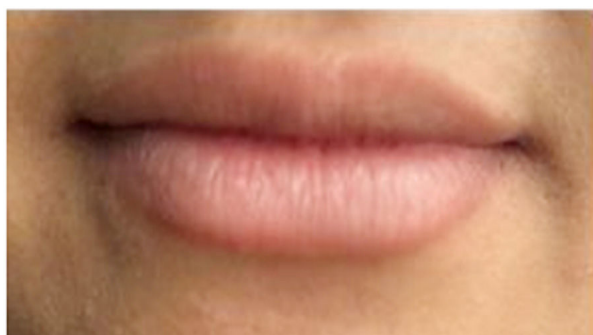


Fig. 1a: Clean the lip




Fig. 2c: Apply the lip stick and ask the to press there lip against the paper, ask them to release there lip against the paper




Fig. 2d: Lip print sample is obtained




Fig. 2b: Ask the person to apply lipstick on the lip using lip stick and using brush or buds apply the lip color in the lip evenly



Fig. 2e: Secure the lip print using lip print with tape and add personal details like name, age, sex.<sup>11</sup>

Fig. 2: Method of collection of sample

## **SCOPE OF CHELIOSCOPY**

The lip print in<sup>14</sup> the crime scene needs a systematic and narrow approach in crime scene. A person how involved in crime scene can be leaving there lip print in beverages glasses, a used mask, cigarette butts, mirrors, or windows can confirm the person who is involved in the crime these lip prints based on their permanence they are known as persistent lip prints which is invisible its lifted using dusting powders (aluminum powders), magnetic powders lip print of a person in the crime scene can make a person suspect in the crime scene. If it is a latent This can see under light microscope,

even using flashlight from an oblique angle the light print can be acquired and photograph and documented. This can say how many people are involved in the crime scene, their usage of cosmetics, age, sex determination, racial determination crime detection and DNA profiling can be taken.<sup>2,9</sup>

### ***Personal Identification***

In the field of forensic personal identification is very important because each person may have a unique identification fingerprint, DNA profiling, As same lip has a unique identification like fine creases on the lips.

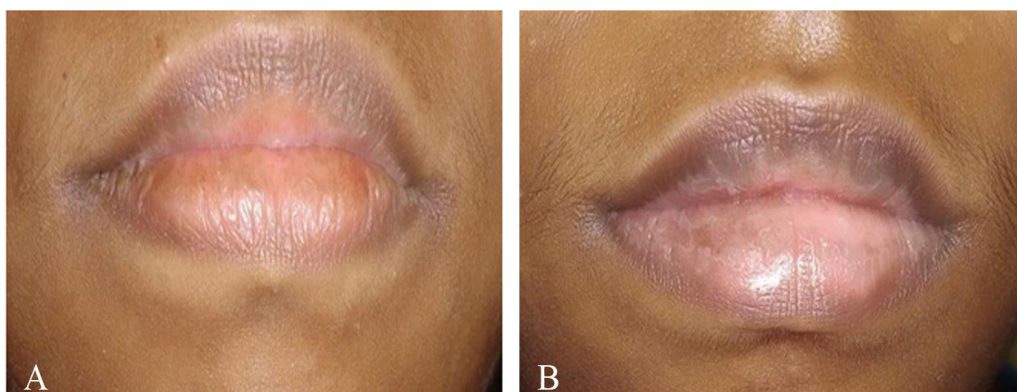

Fig. 3: A,B Lip Photo of Female Twins

### ***Age Determination***

Tonicity of the lip changes in age from birth to death it gets differ the thickness in the lip reduces

by age and at young age the lip print pattern is different and grooves are numerous the vermilion border is little thicker in young children compared to adults.

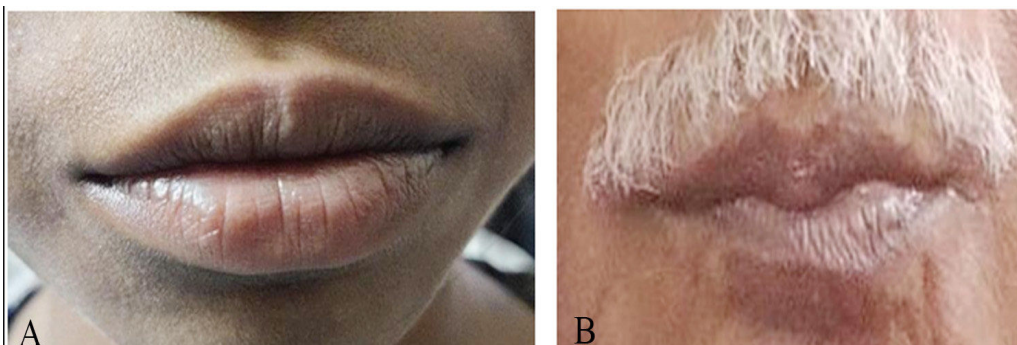

Fig. 4: A, B Lip Photo of a 8 years Old Male and 76 old Male the difference with Maturity of Lip is seen

### ***Sex Determination***

According to the findings Researchers<sup>12</sup> Archana Alzapur, Rajani S. Nagothu, and Hima B. Nalluri

discovered<sup>14</sup> that there were no appreciable commonalities between the male and female participants in their earlier work.<sup>19</sup>

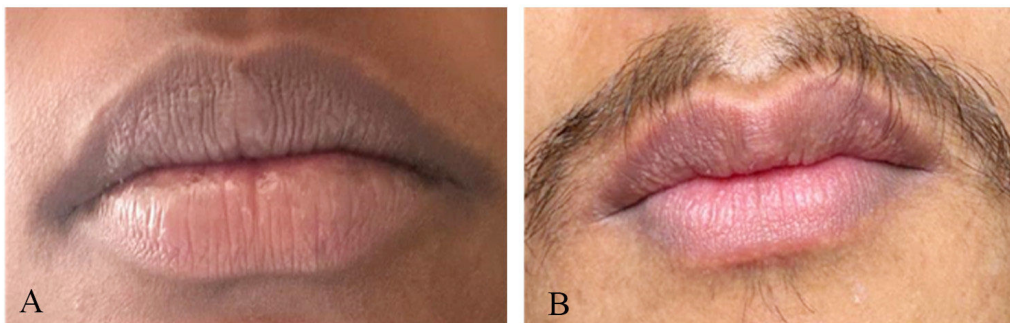

Fig. 5: A, B Female and Male Lip Photos with different of Grooves Male with Type I 'and Female with Type I

### Race Determination

Race of each lip can be identified by the color<sup>18</sup> complexion on the lip and size usually negros have

thick lip.

Asians have mixed form of lip fig. lip print of negros, Asian, causian.

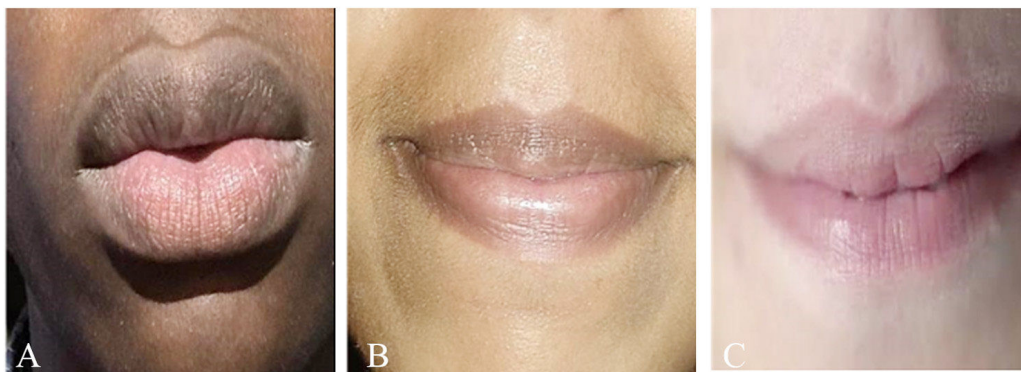


Fig. 6: A, B, C Differnce in the Lip structure based on Race Deretmination

### Crime Detection

It can be used in both criminal and civil cases.

Usually in the crime scene the lip prints may be seen in windows, doors, furnitures, cigratte butts<sup>18</sup>



Fig. 7: A, B: Photo of Latent Lip print in Mirror and Cigarette butt

Here a question can be raised that if there is no lipstick the lip prints does not get into the surface?

Still sebaceous glands and sweat glands help a lot in lip print mark.

**Scenario of Lgbt Community in India**

India is the community with peace and diversity, but there is discrimination of genders mainly in third gender is quite common. Community, which has which is facing lot of abuse, intolerance, discrimination, harsemment and violence against them this gender has lot of reconization issue in public from bathroom to travelling<sup>21</sup> in 1950-1960 people of third gender is known as homophile and in 1970 they were known as subsequently gay as the years rolled down they where known as homosexual community at this 20’s century they were started recognizing in travel,work, school, public washroom now with support of government there is lot of NGO supporting them in education, healthcare, travel etc. According to the census 2011, 4.5 lakh of people in LGBT community. This third gender is known as hijras/shiva-shakti’s, jogappas, jogtas, aradhis, kinnars etc.<sup>10</sup> According to UNESCO, 2018 report it describe children’s how go for school and college faces bullying among the peer community. Basically, in India still they have a mind set if a human being does not able to have intercourse with there opposite gender they are known as “disease of homosexuality”. But in the year 2022, as the supreme court as passed a judgment that even lgbt community can marry and avail all the rights as married couples.

**Chelioscopy in Crime Solving**

Lip prints were collected at the murder scene, occasionally from dishes, glasses, food items, windows, paint, and other materials. Salivary ingredients may be present in these traces, allowing

for DNA testing. Latent print evidence, which is frequently observed at the crime scene and is frequently regarded as essential to solving the crime.<sup>8</sup>

**OBSERVATION**

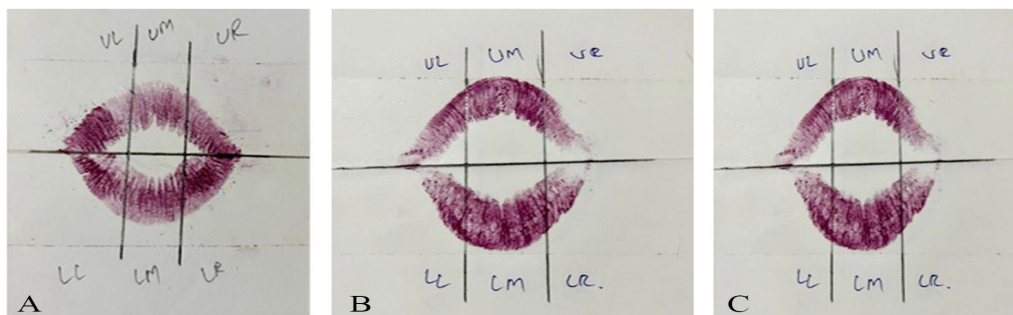
Lip print pattern is formed at 4 months in the womb of the mother and this lip prints have infinite highly sensitive grooves which<sup>19,20</sup> doesn’t change in the life time and this can be used as a evidence because the only source of evidence which can contact the person with crime scene is lip print.

**RESULT**

The result noted from the study Female lip prints in all 6 quadrants are same that is predominant and they have type I and II. Male there is difference in all four quadrants and they have type I, I’, II (its selected with the priority of grooves). Transwomen lip print has a type I, I’ and II, which is like male and this I’ is a difference, and all the 6 quadrants are similar in transwomen and same with transmen has similarity with women. Bisexual has type IV, V, III which is seen them a unique feature and some prints show type II, III. Lesbian has type IV, V. Lip print can be used as a specific identification tool if the further research is conducted so it can be a practical tool in field of forensic to prove the crime suspect involvement. Moreover lip print does not get altered as same as are fingerprint even after surgery of genders the lip print are observed same. Lip prints can be altered only in the condition of disease like cancer in oral cavity, herpes, etc.

**Table 1:** The table explains the differences in lip prints between male, female, gay, bisexual, and transgender individuals.

–	Male	Female	Lesbian	GAY	Bisexual	Transgender
Sample no.	50	50	15	15	15	25
Type	I, I’ II	I, II	IV, III	I, I’	IV, III	I, I’, II
Similarity	Transgender	Bisexual	Bisexual	Male	Female	Male



**Fig. 8 (A,B,C):** Lip print of male type I, type I’, type II

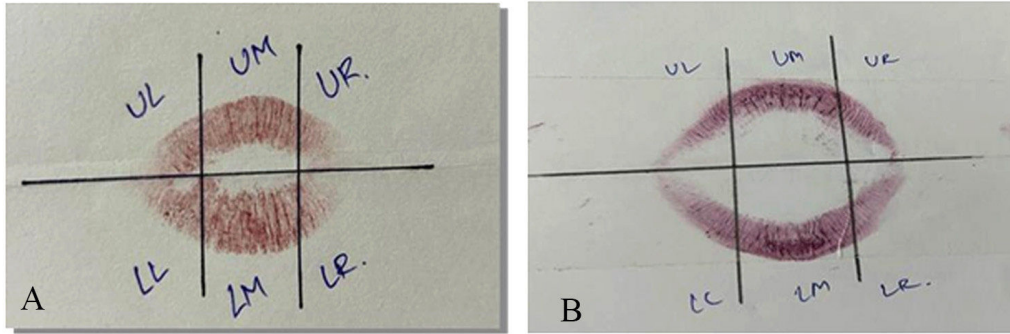


Fig. 9 (A,B): Lip Print of Female Type I, Type III

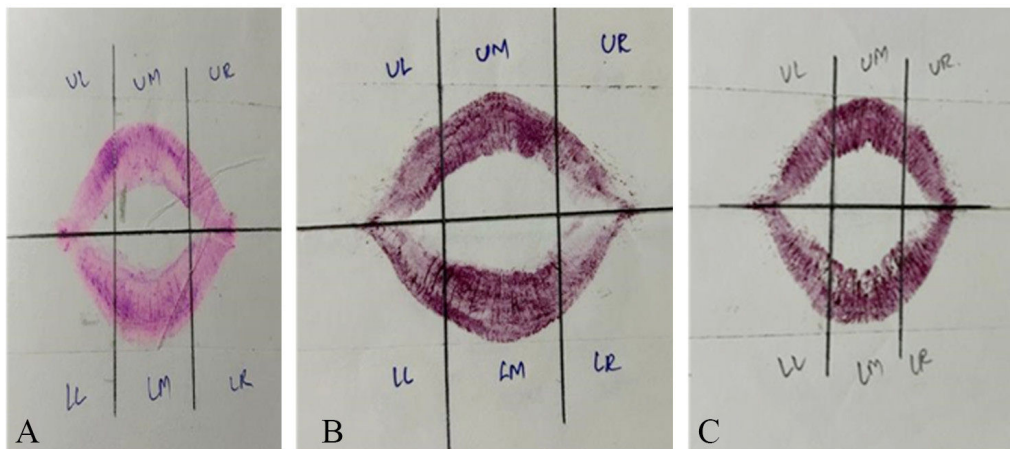


Fig. 10 (A,B,C): Lip Print of Transgender with Type I, Type II, Type

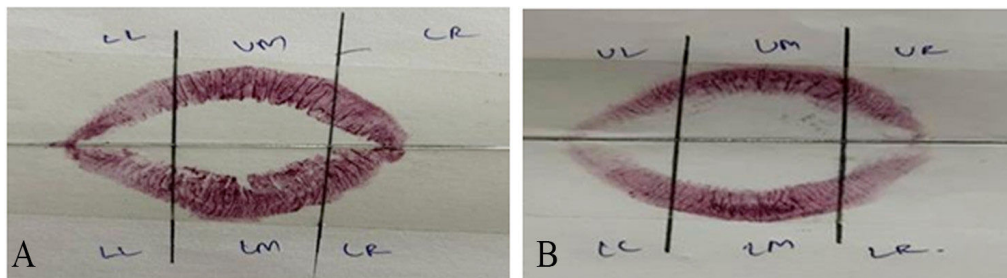


Fig. 11 (A,B): Lip print of bisexual with type III, IV

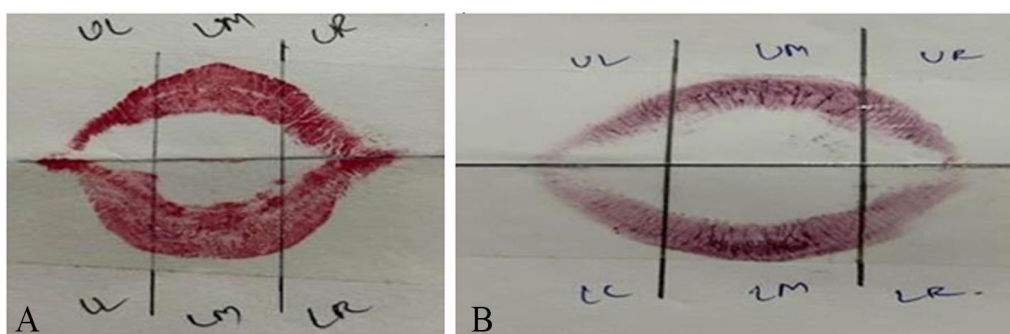


Fig. 12 (A,B): Lip Print of Lesbian with Type IV, V




Fig. 13 (A, B): Lip print of gay with type I, I'

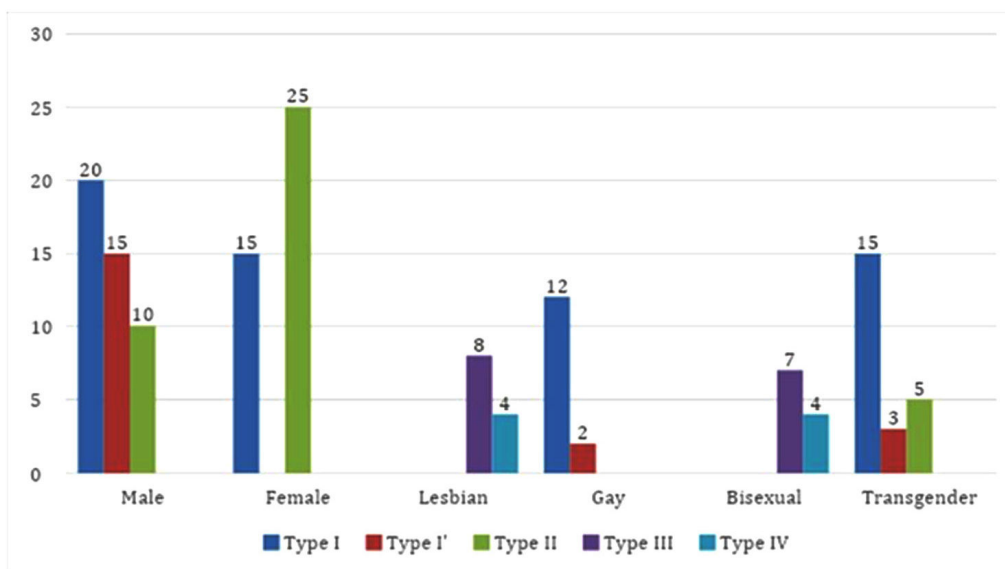


Fig. 14: Graph implies the result of the study with the population of 50 male, 50 females, 15 lesbian, 15 gay, 15 bisexual and 25 transgender.

## DISCUSSION

Chelioscopy may well be a valuable aid device in wrongdoing scenes, mass diaster and accidents. it consider as a most permissible device.<sup>14,15,17</sup> All criminal leaves evidence back at the place one such evidence is lip print its unique and gives a direct link to the person who involved in the crime, even in mass disasters one such evidence. If it can behold the gender to the crime motive can be identified much easier and it's a invasive and inexpensive procedure. According to the researchers K Randhawa<sup>1</sup>, R S Narang, P C Arora they had 3 group of samples based on age group 1 (1-20), group 2 (21-40), group 3 (30-40) and using

Suzuki and tsuchichashi predominance of the lip is print is type I. The lip print has anatomical variation compared to adult anatomical structure and grooves and lip print has reticular grooves 10 describes the anatomical lip print of 9 years old child with 1/3 of reticular pattern.<sup>17</sup>

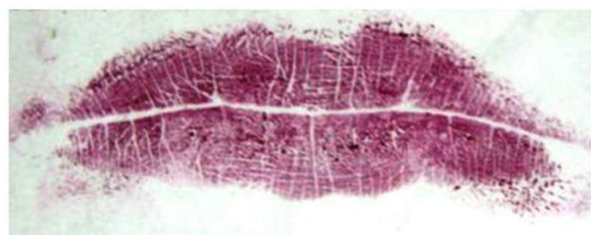


Fig. 15: Lip print of 9 years old child with 1/3 is with reticular pattern in lower lip.<sup>11,14</sup>



In order to validate the study on lip print patterns, future research should include a larger sample size and focus on assessing variances in gender. It is crucial to develop a standardized system of classification, registration, and analysis using software that can aid law enforcement agencies in utilizing forensic odontology more effectively.

## CONCLUSION

From birth to death, no two people have identical lip prints. However, health problems such as diabetes mellitus, hypertension, herpes, inflammation, ulcers, and cysts in the red area of the lip can cause<sup>22</sup> noticeable changes. According to earlier studies, there is little to no resemblance between the lip print grooves of identical twins that were produced at the same time in the<sup>10</sup> womb and born at the same time. According to the most up-to-date studies, every lip print is different, yet there are certain commonalities among classifications. All men have types I, I', and II; all females have types I and III; lesbians have types IV and V; gay people have types I and I'; bisexual people have types III, IV; and transgender people have types I, II and I'. All humans are born male or female, and while this can be modified physiologically, the birth gender markers are retained in the majority of the 170 samples used in this study. There is a very less number of researches on third-gender lip prints, and more needs to be done in this area. The vast majority of transgender people in India live in seclusion or on the periphery of society, where they have a very poor status, and the society frequently speaks to them in a very disrespectful manner. The Indian subcontinent is home to a wide range of studies conducted by cheilosopic experts, the majority of whom were able to distinguish between males and females based on the patterns of their lips, which are distinctive to each gender. Many of them conducted studies with both participants and observers blinded to the results in try to determine a person's gender based on the lip patterns they saw. However, the "third gender" was never addressed and ignored entirely during the whole process. The current cheilosopic study sheds light on the varied lip patterns that are present in them as well as the question of whether or not they have distinctive patterns. In addition to this, the study examines the significance of the many studies that have been conducted in the Indian Subcontinent, discusses the social issues that are faced by transgender people, and elaborates on the role that cheilosopic examination plays in forensics. Additional research

on cheiloscopy has the potential to make it the most effective method there is for determining who committed a crime or who is the suspect.

### *Acknowledgements:*

We sincerely thank Dr Priyanka Verma, Associate professor, Chandigarh University, gharan, Mohali and I thank Aami neermathalam student of maharajas college, Kerala for helping us constantly throughout the study and I also thank our parents Mr. Veerasamy, Mrs. Rajeswari & Mr. Mohana, Mrs. Rema and also our Chandigarh University for the constant support.

*Source of Support:* Nil

*Conflict of Interest:* None declared

## REFERENCES

1. Reddy KS. The essentials of forensic medicine and toxicology. 21st ed. Hyderabad: K Suguna publisher; 2005. Identification; pp. 49-84. [Google Scholar]
2. Kasprzak J. Possibilities of cheiloscopy. Forensic Sci Int. 90;46:145-51. [Google Scholar]
3. Saraswathi TR, Gauri Mishra, Raganthan K (2009) Study of lipprints. J Forensic Dent Sci 1: 28-31.
4. Bindal U, Jethani SL, Mehrotra N, Rohatgi RK, Arora M, *et al.* (2009) Lip Prints as a Method of Identification in Human being.
5. Singh NN, Brave VR, Khanna S (2010) Natural dyes versus lysochrome dyes in cheiloscopy: A comparative evaluation. J Forensic Dent Sci 2:11-17.
6. El Domiaty MA, Al-gaidi SA, Elayat AA, Safwat MD, Galal SA (2010) Morphological patterns of lip prints in Saudi Arabiaat Almadinah Almonawarah province. Forensic Sci Int 179.1-179.
7. Venkatesh, R., & David, M. P. Cheiloscopy: An aid for personal identification. Journal of Forensic Dental Sciences, 2011.3(2), 67-70.
8. Malaysian passport. (2023, October 8). In Wikipedia [https://en.wikipedia.org/wiki/Malaysian\\_passport](https://en.wikipedia.org/wiki/Malaysian_passport)
9. Costa S, Caldas IM. Morphologic patterns of lip prints in a Portuguese population: A preliminary analysis. J Forensic Sci Int. 1974;3:233-48.
10. Kasprzak J. Cheiloscopy. In: Siegal JA, Saukko PJ, Knupfer GC, editors. Encyclopedia of forensic sciences. Vol. 1. London: Academic Press; 2000. pp. 58-61. [Google Scholar] [Ref list].
11. Costa S, Caldas IM. Morphologic patterns of lip prints in a Portuguese population: A preliminary analysis. J Forensic Sci Int. 1974;3:233-48.
12. Moshfeghi M, Beglou A, Mortazavi H, Bahrololumi

- N. Morphological patterns of lip prints in an Iranian population. *J Clin Exp Dent*. 2016;8:e550-55. [PMC free article] [PubMed] [Google Scholar]
13. Tsuchihashi Y. Studies on personal identification by means of lip print. *Forensic Sci Int*. 1974;3:233-48.
  14. Caldas IM, Magalhães T, Afonso A. Establishing identity using cheiloscopy and palatoscopy. *Forensic Sci Int*. 2007;165:1-9. [PubMed] [Google Scholar]
  15. Suzuki K, Tsuchihashi Y. A new attempt of personal identification by means of lip print. *Cann Soc Forens Sci J*. 1971;4:154-8. [Google Scholar]
  16. Castello A, Segui MA, Verdu FA. Luminous lip-prints as criminal evidence. *Forensic Sci Int*. 2005;155:185-7. [PubMed] [Google Scholar]
  17. Augustine J, Barpande SR, Tupkari JV. Cheiloscopy as an adjunct to forensic identification: A study of 600 individuals. *J Forensic Odontostomatol*. 2008; 26:44-52. [PubMed] [Google Scholar]
  18. Naik SK, Prabhu A, Nargund R. Forensic odontology: Cheiloscopy. *Hong Kong Dent J*. 2001; 8:25-8.
  19. Morphological analysis of cholecystectomy specimens. Sharma Sangeeta, B Ran, K Anjali, S Priti, S Suprabha, S Mirza *Journal of Anatomical sciences* 19 (1), 16-21.
  20. Randhava K, Narang RS, Arora PC. Study of the effect of age changes on lip print pattern and its reliability in sex determination. *J Forensic Odontostomatol*. 2011;29:45-51. [PMC free article] [PubMed] [Google Scholar]
  21. Multani S, Thombre V, Thombre A, Surana P. Assessment of lip print patterns and its use for personal identification among the populations of Rajnandgaon, Chhattisgarh, India. *J Int Soc Prev Community Dent*.
  22. Multani S, Thombre V, Thombre A, Surana P. 22. Assessment of lip print patterns and its use for personal identification among the populations of Rajnandgaon, Chhattisgarh, 2014 Sep; 4(3):170-4. doi: 10.4103/2231-0762.142018. PMID: 25374835; PMCID: PMC4209616 India. *J Int Soc Prev Community Dent*.

