

Biphenotypic Sinonasal Sarcoma: A Rare Case Report

Pragati Kesharwani¹, Somya Sharma², Saloni Singhal³,
Ashar Iqbal Lodi⁴, Virendra Bhandari⁵

How to cite this article:

Pragati Kesharwani, Somya Sharma, Saloni Singhal *et. al.* Biphenotypic Sinonasal Sarcoma: A Rare Case Report/Ind J Canc Educ Res 2024;12(1):27-30.

Abstract

Background: Biphenotypic Sinonasal Sarcoma (BSNS) is a recently described tumor with its site of origin limited to the nose and paranasal sinus. It is a rare low-grade sarcoma characterized by concomitant neural and myogenic differentiation with high recurrence rates but lacks metastatic potential. Limited literature is available about the standard treatment regimens due to their rarity.

Case Presentation: Herein we describe the details of the case of a 55-year-old male, known case of recurrent biphenotypic sinonasal Sarcoma who presented with bilateral nasal obstruction. The diagnosis was confirmed by immunohistochemistry. He underwent surgery but developed recurrence twice, and later treated with Radiation Therapy.

Conclusions: Mainstay of the treatment remains surgery but due to its rarity, no definite treatment guidelines are defined. Radical or adjuvant treatment with chemotherapy and/or radiotherapy have been tried with limited data on the outcome.

Keywords: Biphenotypic Sinonasal Sarcoma; Spindle Cell Neoplasm; SMA; PAX3.

Abbreviations: BSNS - Biphenotypic Sinonasal Sarcoma, CD34 - Cluster of Differentiation 34, CK - Creatine Kinase, CT Scan - Computed Tomography Scan, FOXO - Forkhead box protein O, GFAP - Glial Fibrillary Acidic Protein, IMRT - Intensity Modulated Radiation Therapy, MAML - Mastermind like Transcriptional Coactivator, MSA - Muscle Specific Actin, NCOA - Nuclear Receptor Coactivator, PAX - Paired Box Gene, PNS - Paranasal Sinus, SMA - Smooth Muscle Actin, SOX - SRY Related HMG-box gene, STAT - Signal Transducer and Activator of Transcription, WWTR - WW domain - containing transcription regulator protein.

Author Affiliation: ¹⁻³Resident, ⁴Assistant Professor, ⁵Professor, Department of Radiation Oncology, Sri Aurobindo Medical College and PG Institute, Indore 453555, Madhya Pradesh, India.

Corresponding Author: Virendra bhandari, Professor, Department of Radiation Oncology, Sri Aurobindo Medical College and Institute, Indore 453555, Madhya Pradesh, India.

E-mail: virencancer@yahoo.co.in

Received on: 18.07.2023

Accepted on: 01.09.2023

INTRODUCTION

Biphenotypic sinonasal sarcoma (BSNS) is a rare, slow growing soft tissue sarcoma of the sinonasal tract first described by Lewis *et al.* in 2012.¹ It typically presents with nasal mass causing nonspecific obstructive nasal symptoms. The mean age of presentation is 50-51 years, with a predilection for women. Immunohistochemically, neural and myogenic markers are co-expressed.² PAX3 (paired



box gene 3) rearrangements are characteristically noted. The preferred primary treatment is surgery. Treatment with Radiotherapy and chemotherapy has also been tried in adjuvant settings or cases with recurrence. A high recurrence rate has been noted, but distant metastasis has not been reported yet. We present a case of locally invasive recurrent Biphenotypic Sinonasal Sarcoma.

CASE REPORT

A 55 years old male presented with a history of a mass in the bilateral nasal cavity associated with nasal obstruction. The patient had a prior history of a mass in the left nasal cavity. The medical, surgical and family history was insignificant. Initial Computed Tomography Scan Paranasal Sinus (CT PNS) showed mucosal thickening in the bilateral maxillary sinus and frontal sinus, causing obliteration of osteomeatal complexes with bilateral ethmoidal sinus opacified. He underwent mass resection, which was reported as an angiofibroma. He developed a recurrence of nasal mass a year later. A Contrast - Enhanced Magnetic Resonance Imaging (MRI) PNS showed 4.3x3.3x6.8 cm avidly enhancing soft tissue mass lesion in the left nasal cavity, bilateral anterior ethmoidal air cells, and bilateral medial frontal sinuses, which was again resected. Post-resection histopathology report favored spindle cell neoplasm. (Fig. 1)

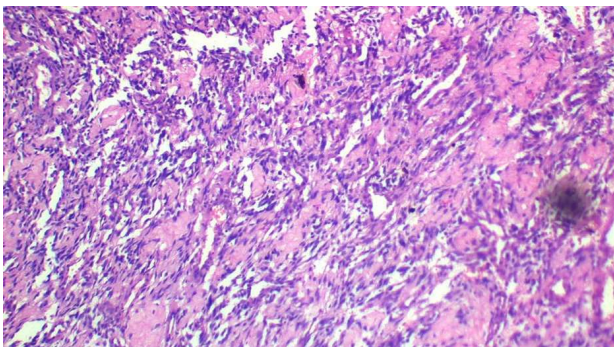


Fig. 1: H & E shows spindle cell neoplasm

An immunohistochemistry panel was studied, positive for Smooth Muscle Actin (SMA, S-100 and Caldesmon. Negative for GFAP (Glial Fibrillary acidic protein), STAT6 (Signal Transducer and activator of transcription 6), CD34 (Cluster of Differentiation 34), Desmin, CK (Creatine Kinase) Synaptophysin, SOX10 (SRY - related HMG Box), and B-Catenin. Ki67 proliferative index 10%. (Fig. 2) Findings confirmed the diagnosis of BSNS (Biphenotypic Sinonasal Sarcoma). Molecular analysis was not done due to financial constraints.

The patient again developed obstructive

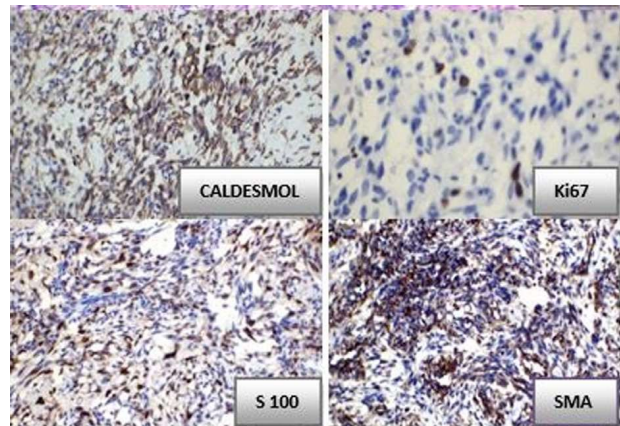


Fig. 2: IHC markers positive for Caldesmol, S-100, SMA and Ki67 proliferative index 10%

symptoms within a year of re-excision and presented to our department with a mass occupying bilateral nasal cavities, difficulty breathing, and swelling over the forehead. On examination, a mass was seen occupying both nasal cavities causing complete obstruction of the left side and partial obstruction of the right nasal cavity. A soft swelling was present over the frontal region, with no palpable lymph nodes.

MRI Face + Neck suggested 8x6.8x2.8 cm well-defined lobulated heterogenous mass lesion involving bilateral nasal cavities, ethmoid air cells, protruding posteriorly into the nasopharynx and anteroposteriorly extending into the right frontal sinuses and causing airway obstruction with the associated remodeling of fronto-ethmoidal air cells appearing heterogeneously hyperintense on T2 and hypointense on T1 images. (Fig. 3).

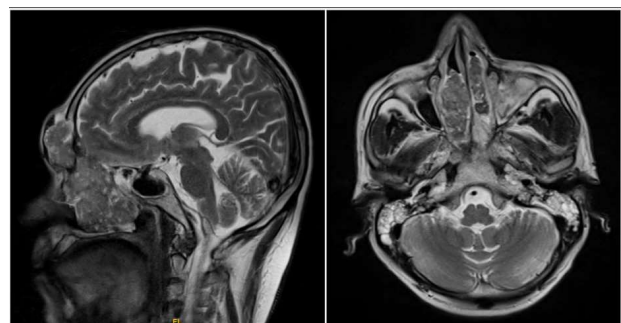


Fig. 3: MRI face + Neck with contrast showing lesion involving bilateral nasal cavities, ethmoid air cells, protruding posteriorly into the nasopharynx and anteroposteriorly extending into the right frontal sinuses

Sinonasal tumors with similar presenting features include solitary fibrous tumour, schwannoma, synovial sarcoma, malignant peripheral nerve sheath tumor with or without rhabdomyoblastic features, leiomyosarcoma, myofibrosarcoma, and inverted papilloma. The diagnosis of BSNS was established based on immunohistological analysis.

The patient was then treated with Local Radiotherapy with a total dose of 60 Gray in 30 Fractions @2Gy/# with 6 MV photons over a period of six weeks by IMRT (Intensity Modulated Radiation Therapy) technique. The patient completed treatment without any gaps. The patient showed significant relief in symptoms and regression of the nasal mass after Radiation Therapy.

DISCUSSION

More than 100 cases of BSNS have been reported in the literature. Tumors commonly involve the nasal cavity and ethmoid sinus. In some cases, tumor extension into the orbit, skull base involvement, and intracranial extension were identified. No known etiological factors have been established. BSNS are characterized by S100, SMA, and muscle specific actin (MSA) expression.^{1,3,4} A recently described monoclonal antibody for evaluating the expression of PAX3 is reported to be highly sensitive (100%) and specific (98%).⁵

Kominsky E *et al.*⁶ conducted a literature review on the 100 previously published cases identified in 12 articles of BSNS based on the electronic databases of Pubmed and Embase. They observed that the mean age of presentation was 52.9 years old, ranging from 28 to 87 years. Female to male ratio was 1.8:1. Most common site involved was the nasal cavity and ethmoid sinus. The extra nasal extension was observed in 27.4% of cases. Forty seven cases were treated with either surgical excision alone or Adjuvant Radiotherapy and/or chemotherapy. Recurrence was observed in 33.3% of patients (equivalent between surgical excision alone and surgical excision with adjuvant chemotherapy/ radiotherapy).

F. Le Loarer *et al.*⁷ retrospectively studied Clinicopathological and molecular features in 41 cases of BSNS. They observed that 61% of patients were females, with a median age of 49 years at presentation. The nasal cavity, followed by the ethmoid sinus, was the predominantly involved primary sites. Thirty three patients were treated with surgical excision with or without radiotherapy and/or chemotherapy. 32% of patients had local recurrence. None of the patients developed distant metastasis. Histologically, the poorly circumscribed and hypercellular proliferation of monotonous spindle cells with low mitotic rates were noted. The immunohistochemical profile of all the cases showed positivity for S100 protein and PAX3 but negative for SOX10. 91% of cases

were focally positive for MyoD1, while 20% were positive for myogenin. Molecular analysis revealed PAX3 - MAML3 (mastermind - like transcriptional coactivator 3) transcript in 90% of cases. Alternatively, Fusion Transcript PAX3 - NCOA2 (Nuclear Receptor Coactivator), PAX3-WWTR1 (WW domain - containing transcription regulator protein), and PAX3 - FOXO1 (Forkhead box protein O 1) were also seen.

In the present case, the patient underwent resection of the lesion twice within a year and again presented with recurrence. The initial histopathology was reported as angiofibroma, while the Biopsy from the recurrent lesion was reported as spindle cell neoplasm that was further confirmed to be BSNS by immunohistochemistry. Both the recurrence occurred within one year of excision, each time more extensive than the previous lesion indicating the possibility of the aggressive nature of the tumour in our patient, but the patient showed a good clinical response with radiotherapy. Long term follow up needs to be further evaluated.

BSNS is a low grade sarcoma with low mitotic activity. Diana Bell *et al.*⁸ reported a case of low grade spindle cell tumour of the left sinonasal cavity initially treated with surgical excision and developed recurrence after 15 years. Molecular analysis identified PAX - MAML3 fusion, and sarcoma was reclassified as recurrent BSNS with higher grade transformation. BSNS being a locally invasive tumour, can invade the skull base and extend to involve intracranial structures and cause complications. Only two fatal cases directly related to the tumour have been reported so far. Both of the cases had an intracranial extension.^{9,10}

CONCLUSION

BSNS is a rare neoplastic entity; It is essential to distinguish it from other tumors in the morphologic differential diagnosis; this distinction can be made with a routine immunohistochemical panel in a large subset of cases, with the option for either fluorescence in situ hybridization interrogation of PAX3 or reverse transcriptase polymerase chain reaction of the described chimeric fusion genes as a diagnostic adjunct. By immunohistochemistry, these tumors characteristically express S100 and SMA, and MSA. Most cases harbor re-arrangements of PAX3, and the most frequent translocation partner is MAML3. Surgery is the mainstay of the treatment for BSNS. Treatment with Radiotherapy is also highly effective and usually can be planned

postoperatively as adjuvant treatment to reduce the chances of recurrence.

REFERENCES

- Lewis JT, Oliveria AM, Nascimento AG, Schembri - Wismayer D, Moore EA, Olsen KD, *et al.* Low - grade sinonasal sarcoma with neural and myogenic features: a clinicopathologic analysis of 28 cases. *The American journal of surgical pathology.* 2012; 36(4): 517-25.
- Agaimy a, Haller F, Hartmann A. Sinonasal tumors: News from the WHO with special reference to mesenchymal entities. *Pathologie.* 2018; 39(1).
- Connan R, Wiggins R, Witt B, Dundar Y, Johnston T, Hunt J. Imaging and Outcomes for a New Entity: Low - Grade Sinonasal Sarcoma with Neural and Myogenic Features. *Journal of Neurological Surgery Reports.* 2017; 78(01): 15-19.
- Chitguppi C, Koszewski I, Collura K, Curtis M, Nyquist G, Rabinowitz M, *et al.* Addendum: Biphenotypic Sinonasal Sarcoma—Case Report and Review of Clinicopathological Features and Diagnostic Modalities. *Journal of Neurological Surgery Part B: Skull Base.* 2019.
- Wang X, Bledsoe KL, Graham RP, Asmann YW, Viswanatha DS, Lewis JE, *et al.* Recurrent PAX3-MAML3 fusion in biphenotypic sinonasal sarcoma. *Nature Genetics.* 2014; 46(7): 666-668.
- Kominsky E, Boyke AE, Madani D, Kamat A, Schiff BA, Agarwal V. Biphenotypic Sinonasal Sarcoma: A Case Report and Review of Literature. *Ear, Nose and Throat Journal.* 2021.
- Le Loarer F, Laffont S, Lesluyes T, Triode F, Antonescu C, ucile ACD, *et al.* Clinicopathologic and Molecular Features of a Series of 41 Biphenotypic Sinonasal Sarcomas Expanding Their Molecular Spectrum. *American Journal of Surgical Pathology.* 2019; 43(6): 747-754.
- Bell D, Phan J, DeMonte F, Hanna EY. High-Grade Transformation of Low - Grade Biphenotypic Sinonasal Sarcoma: A Morphological, Immunohistochemical, and Molecular Study. In 31st Annual Meeting North American Skull Base Society; 2022.
- Lin Y, Liao B, Han A. Biphenotypic sinonasal sarcoma with diffuse infiltration and intracranial extension: A case report. *International Journal of Clinical and Experimental Pathology.* 2017; 10(12).
- Rooper LM, Huang SC, Antonescu CR, Westra WH, Bishop JA. Biphenotypic sinonasal sarcoma: An expanded immunoprofile including consistent nuclear β -catenin positivity and absence of SOX10 expression. *Human Pathology.* 2016; 55.

