

Anaesthetic Management in Retrosternal Extended Multinodular Goitre: A Comprehensive Approach

Syed Hazarath Nabi¹, Vishnuvardhan V²,
Abhinaya Manem³, Suresh Kumar N⁴

How to cite this article:

Syed Hazarath Nabi, Vishnuvardhan V, Abhinaya Manem *et al.* Anaesthetic Management in Retrosternal Extended Multinodular Goitre: A Comprehensive Approach. *Ind J Anesth Analg.* 2024; 11(2) 103-108.

Abstract

Background: Multinodular goitre (MNG) is a common thyroid disorder distinguished by the presence of multiple nodules within the thyroid gland. As a result of gradual progressive development or a rapid nodular haemorrhage leads to tracheobronchial constriction resulting in development of dyspnoea and stridor. Compression of vascular systems can result in vena cava superior syndrome, which includes face and upper body oedema and ultimately postural collapse.

Case Report: A 48-year-old female with multinodular goitre that increased in size over the course of four years and difficulty in swallowing and breathlessness with exertion since a year, with increasing severity in symptoms in the past 2 months. A computed tomography scan of the neck reveals a significant enlargement of the bilateral lobes and isthmus of the thyroid gland across both sides of the neck, extending retrosternally and medially compressing the trachea with significant luminal narrowing. Awake fiberoptic intubation for securing the airway and fiberoptic guided extubation performed by assessing the functioning of vocal cords and confirming absence of tracheomalacia.

Conclusion: Proper preoperative airway examination, patient preparedness for airway management through flexible fiberoptic bronchoscopy or invasively if necessary, and closed perioperative and postoperative surveillance are critical to optimal results.

Keywords: Multinodular goitre (MNG); Fiberoptic extubation; Fiberoptic intubation; Thyroid. (Fig. 4)

Key Messages: For the effective management of retrosternal multinodular goitre, it is imperative to conduct a thorough preoperative assessment, plan accordingly and prepare the patient adequately. This approach ensures patient safety and the successful outcome of the procedure.

Author's Affiliation: ¹Junior Resident, ²Associate Professor, ³Assistant Professor, ⁴Professor, Department of Anaesthesia, Sri Devaraj Urs Medical College & Sri Devaraj Urs Academy of Higher Education and Research, Kolar, Karnataka 563103, India.

Corresponding Author: Vishnuvardhan V, Associate Professor, Anaesthesia, Sri Devaraj Urs Medical College & Sri Devaraj Urs Academy of Higher Education and Research, Kolar, Karnataka 563103, India.

E-mail: voletvishnu@gmail.com

Received on: 09.12.2023 **Accepted on:** 01.02.2024

INTRODUCTION

Multinodular goiter (MNG) is a common thyroid gland condition that commonly manifests with a nodular appearance of thyroid material as a result of genetic variability of follicular cells. Although the clinical characteristics of MNG differ, direct compression of the airway and major vessels necessitates definitive surgical intervention. A retrosternal expansion of this diseased entity



causes more complications. A retrosternal goiter extends into the anterior mediastinum (greater than 2 cm) or descends below the thoracic inlet plane. A meticulous evaluation of the thoracic structures and a stepwise approach to anesthesia induction, with standby cardiopulmonary bypass, are imperative especially in high-risk patients, with symptoms seen on lying down can be alarming. These may include severe postural symptoms, stridor, cyanosis, and radiologic findings such as tracheal compression (>50%), or associated bronchial compression, pericardial effusion, or superior vena cava syndrome. It is important to monitor these symptoms closely and seek medical attention if they persist.¹

CASE REPORT

A 47-year-old female (156 cm, 53 kg, BMI: 21.8 kg/m²) with multinodular goiter extending retrosternal was posted for total thyroidectomy. The patient had complaints of swelling in the neck for 4 years which was gradually progressing in nature. The patient was diagnosed with hypothyroidism and was on Tab. Thyroxine 25 mcg OD. The patient gives a history of difficulty in breathing in the past 1 year, aggravated at night, supine position and relieved on lying laterally or sitting posture. She also complained of difficulty in swallowing more with solids than liquids in the past 1 year. (Fig.1)

On pre-anesthetic examination, her heart rate was 78 beats/min, non-invasive blood pressure (NIBP) was 126/70 mmHg, and room air saturation was 96%. Other general physical examination was unremarkable. Local examination revealed swelling

in the front of the neck in the midline, measuring 10*8 cms with superficial dilated veins and retrosternal extension as the lower border of the swelling was not palpable and swelling did not move with deglutition. Pemberton's sign was positive for dilation of veins and becoming prominent but flushing of the face wasn't evident. Airway examination showed she was Mallampati class 4, with a mouth opening of 3 finger breadth and thyromental distance of 4 cm. Neck flexion was restricted severely and extension was compromised. During the indirect laryngoscopy examination, it was observed that both vocal cords were mobile bilaterally.

Blood count, electrocardiogram, blood sugar levels, renal/liver function test, thyroid function test, serum calcium, and coagulation profile were within normal limits. Chest radiograph showed well-lobulated soft tissue opacity with a retrosternal extension below the manubrium. (Fig. 3) CECT (Contrast-enhanced Computerized Tomography) of the neck reported to have enlarged thyroid gland with multiple varying sizes heterogeneously enhancing nodular lesions involving bilateral lobes [Right: - 6.8*4.6*10.4cm and Left: - 6.3*4.5*8.6 (AP*TR*CC)] and isthmus of gland (2.9 cm) from C4 to D4 vertebral body level (precarinal level). The gland is extended retrosternal of about 4.2 cm inferior to the upper border of the manubrium. It also reported that laterally the right lobe of the thyroid gland was indenting the medial aspect of the upper lobe of the right lung with bilateral displacement of jugular and carotids bilaterally. Medially, it is compressing the trachea and causing significant luminal narrowing [minimum calibre 14*5.5 mm (AP*TR)] with mild deviation to the left. Inferiorly it is extended up to the superior and middle mediastinum. (Fig. 2)

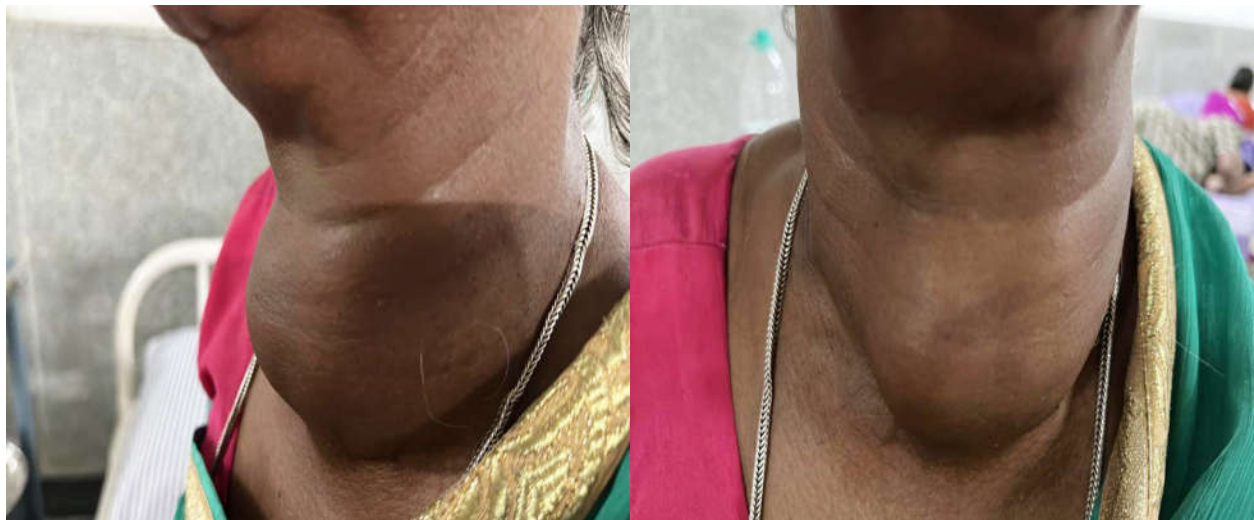

Fig. 1 & 2: Pre-operative AP view and lateral view of the swelling

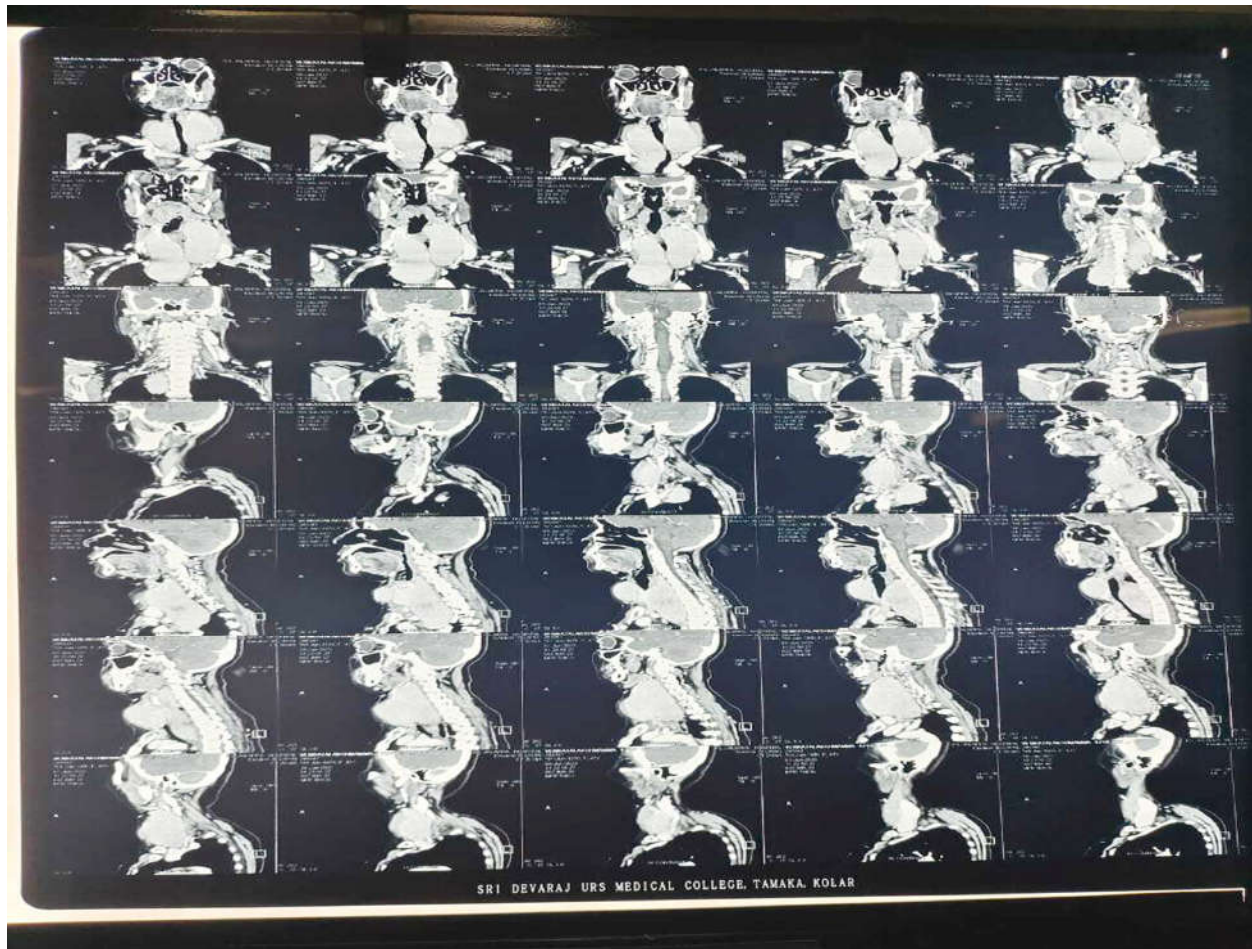


Fig. 3: CT scan showing retrosternal extension and compression over trachea

The patient began receiving chest physiotherapy and incentive spirometry. The patient was started on bronchodilator therapy. She was taken up for surgery under ASA II. The patient was also counselled for awake flexible fibre optic bronchoscopy assisted intubation and consent for the same was taken. The patient was also explained about the need for elective mechanical ventilation post-surgery given the nature of the surgery, the risks of a difficult airway, and the consequences of hypoxia and mediastinal mass syndrome following induction of anaesthesia.

NPO orders were followed. Adequate blood and blood products were reserved on the day of surgery. In the preoperative room, the patient was prepared for awake nasal fibreoptic intubation. Injection of glycopyrrolate 0.2mg IV was given. The patient was nebulized with 4ml of 4% lignocaine. Nasal packing was done using 4ml of lignocaine 2% with adrenaline soaked cotton swab wicks. Two large bore 18 G cannula were secured in bilateral upper limbs and normal saline was started on one side. The patient was shifted inside

the operation theatre, and standard ASA monitors (NIBP, ECG, pulse oximeter) were connected. The difficult airway cart was kept ready in the operation theatre. The patient was placed in semi recumbent position with a head elevation of 20°. Cotton wicks were removed from nostrils and the oral cavity was sprayed with 10% lignocaine. The upper airway was topicalized using the McKenzie technique with lignocaine 4% in a 10ml syringe diluted according to the requirement calculated using lean body mass. Awake flexible fibreoptic was passed through the right nostril which revealed significant compression in the mid-tracheal region above the carina and the patient was intubated with a 6.5mm flexometallic cuffed endotracheal tube which is placed beyond the region of compression. The patient was induced subsequently using an injection of propofol 80mg IV. Injection fentanyl 60mcg was given IV. The patient was maintained on O₂+N₂O+isoflurane (MAC <1). Adequate muscle relaxant was achieved with the injection of vecuronium. The patient was positioned for surgery with neck extension for adequate

surgical exposure. Intraoperative analgesia was maintained with graded doses of injection fentanyl 20 mcg and injection paracetamol. The tumour was excised successfully via a cervical approach which weighed around 680gm. Blood loss was around 600ml and was adequately managed with fluids. The intraoperative vitals of the patient were stable. (Fig. 5)

The surgeon examined the trachea before extubation. The tracheal rings were patent, but mild weakness was noted in the mid-trachea. The issue was addressed, and the examination provided a valuable assessment of the trachea's condition. During the procedure, while the patient was under deep anesthesia, the endoluminal side of the trachea

was carefully examined once again using a flexible bronchoscope. The inspection revealed a narrow, yet patent tracheal lumen located in the mid-tracheal region. This information may be useful for further evaluation and treatment planning. The decision to safely extubate the patient was made based on the absence of tracheomalacia, vocal cord paralysis, and swelling under anesthesia. This ensured a successful extubation with minimal risk and optimal patient outcome. The patient was lying in bed, deeply anesthetized, in an upright position. Neuromonitoring was used to ensure that there was no residual muscle relaxation. A cuff leak test was performed which showed a drop in tidal volumes which revealed a positive result.

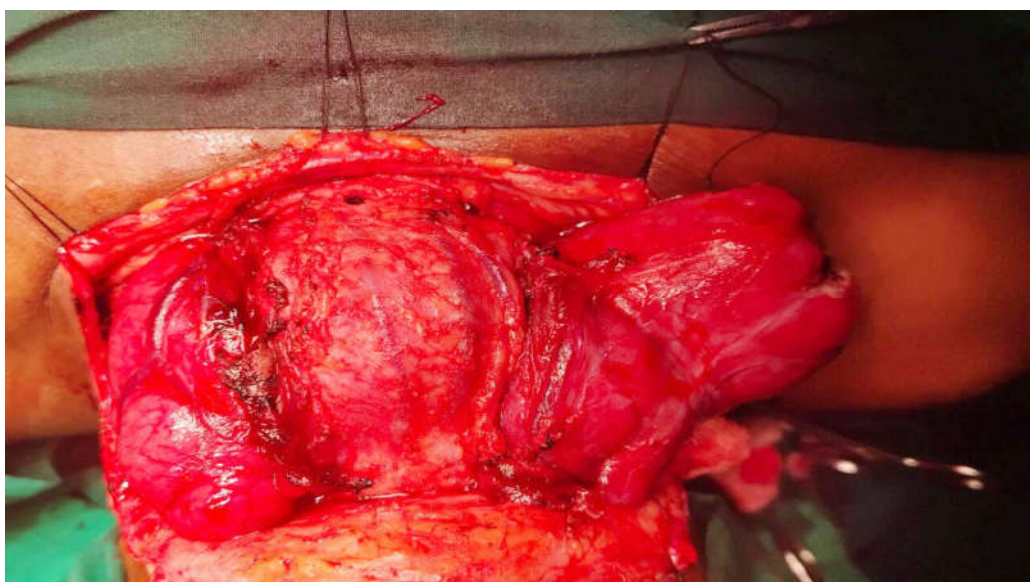


Fig. 4: Intraoperative thyroid swelling

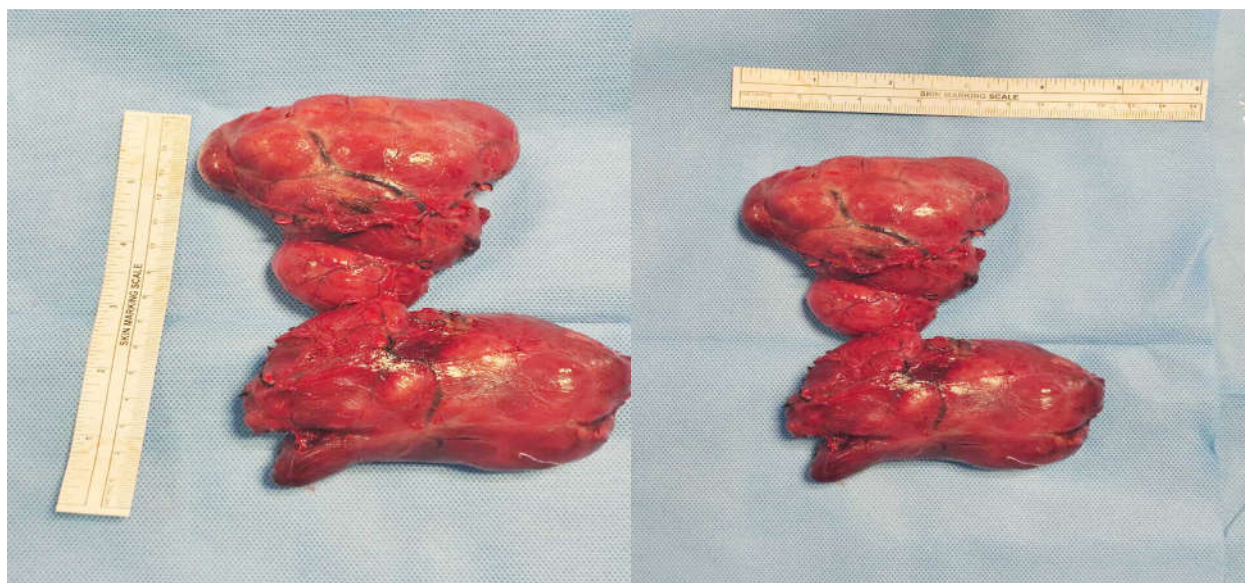


Fig. 5: After tumour excision

Under fibreoptic guidance endotracheal tube was railroaded back onto to fibreoptic bronchoscope and extubated after reversing the muscle relaxant effect using an injection of neostigmine 2.5mg and injection of glycopyrrolate 0.6mg and confirmed the functioning of vocal cords and absence of tracheomalacia. The patient was shifted to the ICU for overnight observation.

Post-operative pain was managed using NSAIDs and with an injection of fentanyl 20mcg intermittently based on a verbal rating scale (VRS \geq 4) and visual analog score (VAS \geq 4). Post-operatively patient was transfused with one packet of packed red blood cells. The patient began to use an incentive spirometer and received chest physiotherapy. The patient was mobilized and shifted to the ward on 1st post-operative day. The patient was discharged after a week of uneventful stay.

DISCUSSION

Managing anesthesia for patients with obstructive retrosternal masses is challenging due to the risk of tracheal occlusion after induction and tracheomalacia post-extubation. To mitigate these complications, anesthesiologists must remain vigilant and implement careful preoperative assessment, titrate anesthetic agents, and closely monitor patients post-operatively. For difficult airway management, use imaging and consider severity, type of abnormality, and blockage level. Multinodular goitre is usually benign and does not invade the trachea. An experienced and highly skilled team, consisting of the anesthetist, surgeon, and other professionals, must come to a unanimous agreement on the final set of plans. This ensures that the approach is well-planned and executed with utmost precision and confidence.¹

Several definitions have been proposed to clarify the meaning of an RSG, some of which include a goitre: (i) that descends below the plane of the thoracic inlet (ii) with more than 50% of the mass lying below the plane of the thoracic inlet (iii) with major intrathoracic extension requiring reaching into the mediastinum for dissection (iv) growing into the anterior-superior mediastinum to a depth of >2 cm or (v) reaching the level of the fourth thoracic vertebra.² After considering the risks and advantages, each case requires a personalized "plan ABC."³ The availability of rigid bronchoscopy with jet ventilation would offer rescue in the event of loss of airway control.

In this case, the patient had obstructive airway symptoms, and the mass was extended retrosternal with significant tracheal lumen narrowing, our primary plan was to use a flexible fibreoptic bronchoscope for intubation so that the endotracheal tube could be passed beyond the obstruction site. Pre-operatively patient was started with nebulization and incentive spirometry. Upper airway topicalization was done using the McKenzie technique which greatly increases the surface area of local anesthetic and allows direct topicalization of the nasal and oral mucosa.⁴ As per the CECT report the anteroposterior diameter of the trachea was significantly narrowed to 14mm and for deranged airway anatomy, we had chosen to go with a 6.5mm flexometallic tube due to its outer diameter being around 8.8mm which can pass beyond the obstructive site easily without traumatising the airway structures. The availability of rigid bronchoscopy with jet ventilation would offer rescue in the event of loss of airway control.

After tracheal assessment by the surgeon and confirming the residual reversal of muscle relaxant using neuromuscular monitoring decision to extubate the case was taken and under fibreoptic guidance, extubation was done by assessing the functioning of vocal cords and absence of tracheomalacia. The patient was shifted to the ICU for observation overnight.

CONCLUSION

In conclusion, patients with multinodular goitre extended retrosternal with or without airway obstructive symptoms should undergo careful detailed history and examination with relevant investigations. CECT findings are very helpful, especially in the identification of tracheal lumen narrowing and anticipation of endotracheal tube size. McKenzie technique as upper airway topicalization provides smooth intubation. Patients can be extubated using fibreoptic guidance with proper timing and technique.

Financial support and Sponsorship: Nil.

Conflicts of Interest: There are no conflicts of interest.

REFERENCES

1. Dhanpal RD, Shivappagoudar VM, Gonsalvez G, Vithayathil R, Alappat AM. Anesthetic Management of a

- Patient with Retrosternal Goiter Using a Double-lumen Endotracheal Tube. *Karnataka Anaesth J* 2017; 3:13-5.
2. Bhatnagar V, Karmarkar AA, S. Raghuvanshi VP. Anesthetic management of a patient with multinodular goiter with retrosternal extension presenting with obstructive sleep apnea for total thyroidectomy. *Med J DY Patil Vidyapeeth* 2018; 11:423-6.
 3. Choudhary N, Kumar A, Wadhawan S, Bhadoria P, Panwar V. Retrosternal goitre: Anaesthetic implications and management. *Indian J Clin Anaesth.* 2018;5(3):453-456.
 4. Gupta, Babita; Kohli, Santvana; Farooque, Kamran1; Jalwal, Gopal; Gupta, Deepak2; Sinha, Sumit2; Chandralekha, Topical airway anesthesia for awake fiberoptic intubation: Comparison between airway nerve blocks and nebulized lignocaine by ultrasonic nebulizer. *Saudi Journal of Anaesthesia* 2014; 8; S15-S19.

