

# Miracle Negative Pressure Wound Therapy (NPWT) or Vacuum Assisted Closure (VAC): For Difficult and Complicated Wounds: An Observational Study

Abhishek Sharma

## How to cite this article:

Abhishek Sharma. Miracle Negative Pressure Wound Therapy (NPWT) or Vacuum Assisted Closure (VAC): For difficult and Complicated Wounds: An Observational Study. *New Indian J Surg.* 2024; 15(3):95-100.

## Abstract

In complicated wounds, healing is a challenge, particularly for the elderly with co-morbidities, which is a major concern. It can lead to prolonged treatment, pain, and morbidity and require major reconstructive procedures, which foist enormous financial and social burdens. Negative pressure wound therapy (NPWT) or vacuum-assisted closure (VAC) is a miracle and more acceptable method as an alternative in wound management that relies on sub atmospheric pressure and encourages the wound for spontaneous healing or by reducing the burden of reconstructive procedures. VAC application methods include thorough debridement, haemostasis, and the application of sterile sponge or foam dressing. A tube with fenestrations is submerged in the sponge, and the wound is wrapped to make it airtight or watertight with adhesive tape. The vacuum pump with fluid collection container is connected to the fenestrate tube. The pump delivers intermittent or continuous suction with pressure ranging from 50-55 to 120-125 mmHg. The NPW dressings are replaced on the third day. Negative pressure therapy reduces wound oedema and bacterial load, stabilizes the wound environment, improves perfusion, and stimulates angiogenesis and granulation tissue. All these mechanisms facilitate the possibility of primary wound closure and reduce the need for other reconstructive procedures. VAC therapy seems to be more effective and simpler

**Author Affiliation:** Medical Superintendent, Senior Consultant, Director and Head of the Department, Department of Plastic Surgery and Reconstructive Surgery, All Is Well Multispeciality Hospital, Burhanpur 450331, Madhya Pradesh, India.

**Corresponding Author:** Abhishek Sharma, Medical Superintendent, Senior Consultant, Director and Head of the Department, Department of Plastic Surgery and Reconstructive Surgery, All Is Well Multispeciality Hospital, Burhanpur 450331, Madhya Pradesh, India.

**Email:** drabhisheksharma7@gmail.com

**Received on:** 07-10-2024

**Accepted on:** 12-11-2024

than traditional dressings for wound care management in reduction in wound size and volume, depth, treatment duration, and cost.

**Keywords:** VAC (vacuum-assisted closure); Negative pressure wound therapy (NPWT); Complicated and difficult wounds; Low cost; Sub-atmospheric pressure dressing.



## INTRODUCTION

In complicated wounds, healing is a challenge, particularly for the elderly with co-morbidities, which is a major concern. It can lead to prolonged treatment, pain, and morbidity and need major reconstructive surgical procedures, which foist enormous financial and social burdens. Negative pressure wound therapy (NPWT) is a miracle and more acceptable method of management of wounds alternatively that relies on negative pressure to prepare the wound for healing spontaneously or by reducing reconstructive procedures. The vacuum-assisted closure is a non-surgical and non-pharmacological means for modulating wound healing; it was first suggested by Argenta and Morykwas in 1997.<sup>1,2</sup> The application of vacuum-assisted therapy reduces infection and oedema and improves local blood flow, which promotes healing.<sup>3</sup> It is used as an alternate or adjunct to surgery for a wide range of wounds, with the target of decreasing the duration of hospitalisation, morbidity, cost, and patient comfort.<sup>4-6</sup>

## MATERIALS AND METHODS

### VAC application method

The debridement and cleaning of the wound are done thoroughly, irrigated with normal saline, and haemostasis is achieved, and the skin surrounding the wound is made dry. To facilitate an equal distribution of negative pressure, sterile sponges are required for dressing, as they cover an over-the-whole wound bed. Two different types of foams or sponges are commonly used: white (polyvinyl alcohol), which is dense, hydrophilic, and has a hole size of 250  $\mu\text{m}$ .<sup>8</sup> Black (polyurethane ether is a lighter, porous, 400–600  $\mu\text{m}$  of size and hydrophobic in nature) is used for abdominal and thoracic cavity wounds. A fenestrated evacuation tube is buried in the sponge, which is attached to a container and a vacuum pump. The adhesive drape was used to seal the wound. Drapes should cover tubing beyond the foam at least 4–5 cm of neighbouring skin to make it airtight or watertight seal. The VAC dressing is recommended to change on the third day. There are two modes of negative pressure, intermittent or continuous, ranging from 50 to 125 mmHg. Higher pressures (150 mmHg plus) are used for exudative and large cavity wounds. Intermittent mode consists of a 5-minute on and 2-minute off phase. In painful and chronic

wounds, the setting of pressure can be kept low (40–75 mmHg).

## RESULT

In this study, we compared our results of vacuum-assisted wound closure technique in different wound scenarios and compared the efficacy and economy of commercialised VAC and indigenously made VAC therapy. A total of 24 patients were included in this study, in whom VAC wound closure treatment was given in our institute between January 2022 and December 2023. The distribution of the patients was as per aetiology as follows: 12 traumatic, 3 pressure sores, 8 diabetic foot ulcers, and 1 post-CABG wound dehiscence. All cases were assessed in terms of wound size, aetiology, gender, age, and treatment period. In the patients studied, 20 were men (83.33%) and 4 were women (16.66%). The age of patients ranged 18–69 years, and the mean age of the patients was 42.6 years. Most of our patients suffered from trauma and diabetic ulcers. After the indigenous vacuum-assisted wound closure application, wound size reduced by 38.8%, and the mean surface area of the wound was 95.7  $\text{cm}^2$  (12.8–218.3 $\text{cm}^2$ ) on average. Once the wounds

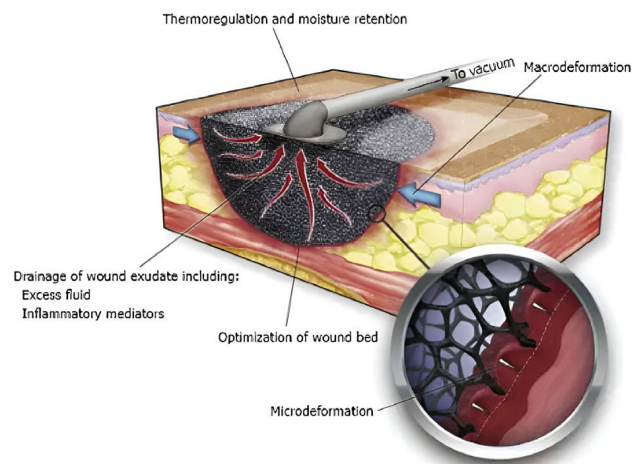


Fig. 1: Physiological changes during VAC therapy

became primed for surgery, split-thickness grafting was used in 8 patients. 5 of them needed secondary sutures; full-thickness grafting was used in 8 of them; 2 of them required flaps; and 1 healed itself by secondary intention. The average period of the application of vacuum-assisted wound closure was 11.4 days (8–16 days). In the long term, the overall cost of treatment is further lower with indigenously made VAC. Our study results were comparable to commercial systems, and indigenously made vacuum-assisted wound closure can be considered

satisfactory, economical, and without complications when cases are selected properly.



Fig. 2: Locally available material or device to assemble VAC therapy

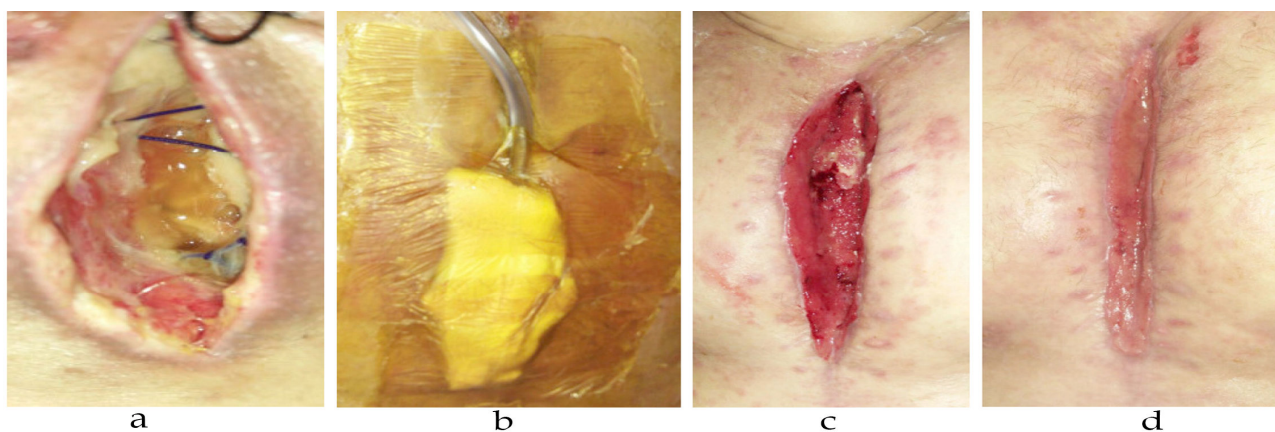


Fig. 3: (a) Wound over chest following CABG; (b) Indigenously prepared VAC in place; (c) Post-VAC therapy wound after two sessions; (d) Same wound after 2 weeks

## DISCUSSION

In the beginning, NPWT-negative pressure wound therapy was used to hasten the preparation of wounds bedside. To evaluate the negative pressure therapy effect of topical on bacterial clearance, local blood flow, the formation of granulation tissue, and flap survival Morykwas *et al.*<sup>1,2</sup> observed in a series of experiments in animals. Subsequently, they decided to use a sponge dressing with a vacuum suction for wound management, with an adjusting vacuum pressure of intermittent and continuous modes. **Indications** of vacuum-assisted closure include bed sores, diabetic foot ulcers, flap salvage, skin graft fixation, crush injuries, burns, abdominal or sternal dehiscence of wounds, wounds after fasciotomy, animal bites, or frostbite extravasation wounds. VAC is not recommended in patients with unmanaged osteomyelitis, body cavities, fistulae, or malignant wounds, with wounds with exposed

arteries, nerves, anastomotic sites, or organs showing up necrotic tissue.<sup>8,9</sup> VAC is relatively contraindicated in patients actively bleeding, on anticoagulant therapy, or with wound dyscrasia.<sup>9</sup> **Alarming signs** during VAC therapy include surrounding invasive sepsis, active or excessive bleeding, signs of infection, increased pain, such as fever, foul-smelling drainage, or pus, and an allergy to the adhesive material.<sup>9</sup> **VAC therapy complications** include VAC system failure (power failure, loss of seal, and drainage system blockage), pain, wound infection, bleeding, skin excoriation, limited mobility, being allergic to drape, adhesion of the tissues to the foam, skin necrosis, and a lack of patient compliance. VAC therapy gives rise to reduced hospital stays by reducing the bacterial load, number of dressing changes, improving skin perfusion, reducing patient comfort, reducing oedema, and providing a moist, optimum wound healing environment.

### Mechanism of action

Animal and human studies have indicated VAC therapy causes reduction of the area of wound, increased blood flow, granulation tissue growth, and regulation of the inflammatory response.<sup>1,10</sup> VAC causes optimisation of the wound environment, wound contraction, removal of wound exudates, micro-deformation of cells, and decreased oedema. These effects allow VAC to improve wound healing by virtue of reduced bacterial load, increased blood flow, and improved wound size reduction for subsequent coverage.<sup>1,12</sup> The tissue hypoxia induced by negative pressure causes wound compression, which leads to decreased perfusion beneath the sponge, which stimulates angiogenesis and local vasodilatation due to the release of nitric oxide.<sup>13,14,15</sup> This happens during the "suction off" periods of therapy. Therefore, the intermittent VAC mode is relatively proven to be more efficient as compared to the continuous mode. Interstitial hypobaric pressure and increased vessel permeability following injury lead to the development of oedema.<sup>16</sup> VAC application leads to increased pressure inside tissue, which causes vessel compression of and increased acceleration of the intravascular fluid, which decreases the intravascular fluid pressure (Bernoulli's principle).

Both of these factors cause decreased oedema due to less efflux of intravascular fluid. In addition, increased blood velocity shifts extracellular fluid into the vessel. In addition, negative-pressure wound therapy reduces injured tissue oedema away by compressive forces. All these processes result in improved oxygenation of cells and less interstitial fluid pressure. VAC therapy causes the immobilisation of wounds, which also favours ealing.<sup>17,18</sup>

The release of growth factors occurs due to micro-deformation of cells caused by VAC, which causes tissue expansion.<sup>19,20-21</sup> After negative pressure application, the expansion effect on the tissue occurs due to the differential pressure changes. The pressure beneath the dressing and outside the cells is negative, whereas the pressure inside the cells is positive. This causes the wound edges closer to a further, decreasing size of the wound, the expansion of cells, and granulation tissue growth. A recent study has shown that the paradoxically increased pressure that occurs in the basic wound is (hyperbaric)<sup>22</sup> In the capillaries, perfusion pressure in normal tissue ranges 10-35 mmHg.<sup>23</sup> If the vascular anatomy is normal, there are no chances that hyperbaric pressure causes capillary occlusion. Whereas, in vascularly compromised tissue, hyperbaric pressure may lead to ischaemia

and necrosis. Therefore, VAC should be used with caution on tissue with less vascularity or ischaemia, especially if it is circumferential.

### Optimum negative pressure required

Various controversies exist regarding the optimal pressure application in negative pressure therapy. Some studies on animal models have shown formation of granulation tissue occurs with 125-mmHg negative pressure compared with elevated (500 mmHg) vacuum suction and low (25 mmHg) vacuum suction. The low pressure during VAC (25 mmHg) leads to less removal of toxins and fluid drainage from the wound and decreased cell deformation. This results in a reduced rate of formation of granulation tissue. The suction pressure high (500 mmHg) during VAC causes enhanced mechanical distortion of tissues, which causes a decrease in perfusion locally and reduced formation of granulation tissue. Therefore, a 125 mm Hg of negative pressure is considered an optimal pressure.<sup>7,24</sup> Results of various levels of negative pressure in different wounds (10-175 mmHg) reveal that the negative pressure changes should be adjusted according to the types of the wound. For chronic non-healing venous ulcers, the 50 mm Hg at intermittent cycles optimum pressure is required. In acute traumatic wounds, 125 mm Hg is the optimum negative pressure required.<sup>25,26</sup>

### Continuous vs. Intermittent VAC

Negative pressure intermittently is recommended as it improves more blood flowing during the vacuum "off" phase. Studies have revealed that granulation tissue formation rate is doubled with negative pressure intermittently than with continuous pressure. (104% with intermittent vs. 64% with continuous).<sup>27</sup> **Leakage of air** in the dressing should be avoided, as they can lead to a continual flow of air over the wound, leading to tissue desiccation and the formation of eschar. This eschar formation covers the wound with retained exudate and leads to deterioration of wound condition.<sup>28</sup> **The** pressure in a vacuum-assisted dressing gradually reduces over 48 hours; therefore, dressings should be changed after 2 days.<sup>29</sup> Caution should be taken during VAC therapy; rebound phenomenon and worsening of the wound condition are seen if it is terminated abruptly after one session. Therefore, at least two to three sessions of VAC should always be considered. There is one randomised control trial that provides objective evidence regarding the use of VAC in different situations. There is a strong recommendation that grade "A" is suggested only for the skin grafting procedure management; grade

“B” is the use of VAC as a span therapy between multiple debridements; and grade “C” is considered for traumatic wounds.<sup>30</sup>

### Cost

There are studies on various wounds that suggest that vacuum assisted closure is to a great extent more economical as compared to traditional wound care management techniques, as it requires a lesser number of dressings and fewer reconstructive procedures for wound healing. Wound healing becomes faster, and the duration of the overall hospital stay and treatment are reduced. Even though commercial VAC dressings are more costly than conventional dressings, in the long term, the overall cost of treatment is lower with VAC.<sup>31,32</sup>

The San Antonio, TX, Kinetic Concepts, Inc. (KCI) wound VAC system and non-availability of other commercial vendors everywhere, and these devices are expensive too. Without buying costly dressing material, we have used off-the-shelf components in our patients for cost-effective negative pressure therapy or borrowed the KCI system, which may cost Rs. 8,000/day approximately. We have utilised locally available materials like abdominal drains, cling drapes, bactigras, sponges, and foams to congregate a dressing (Fig. 2). To generate pressure (75–125mmHg) negatively, this indigenously prepared dressing is connected to wall-mounted suction. This dressing is extremely cost-effective. The all-component cost is only Rs 400-500. This indigenously made VAC dressing system was used in many cases without complications and with results that are comparable to the commercial system<sup>31,32</sup> (Fig. 2, Fig. 3). The lack of ability to use mounted suction intermittently is one of the limitations of this indigenous dressing because mounted suction devices have only a continuous mode.

### Key points

- In complicated wounds, VAC is a better alternative or adjunct to standard wound management.
- It reduces the burden of reconstructive procedures.
- The 125 mm of mercury is optimum recommended pressure setting.
- Intermittent suction mode has an advantage over continuous suction mode.
- Over the conventional wound care methods, VAC has logistical benefits.
- The cost wise VAC in the long term has a cost-benefit ratio. It's results are too parallel to standard wound-care methods.

## CONCLUSIONS

VAC/NPWT is a miracle in the field of surgery. It decreases the bacterial load, reduces oedema, stabilises the wound, improves tissue perfusion, and stimulates granulation tissue. It reduces the requirement for major reconstructive surgical procedures and improves the chances of voluntary wound healing. Vacuum assisted closure is an effective and simpler substitute for the management of various wounds than conventional dressing methods in terms of reduction in wound size, duration, and treatment cost.

## REFERENCES

1. Morykwas M.J., Argenta L.C., Shelton-Brown E.I., and McGuirt W. Vacuum-assisted closure: a new method for wound control and treatment. Animal studies and a basic foundation. *Ann Plast Surg.* 1997;38:553–562. [PubMed] [Google Scholar]
2. Argenta L.C., Morykwas M.J., Vacuum-assisted closure: a new method for wound control and treatment. Clinical experience. *Ann Plast Surg.* 1997;38:563-577. [PubMed] [Google Scholar]
3. Genecov D.G., Schneider A.M., Morykwas M.J., Parker D., White W.L., and Argenta L.C. A controlled subatmospheric pressure dressing increases the rate of skin graft donor site reepithelialization. *Ann Plast Surg.* 1998;40:219–225. [PubMed] [Google Scholar]
4. Armstrong D.G., Lavery L.A., and Abu-Rumman P. Outcomes of subatmospheric pressure dressing therapy on wounds of the diabetic foot. *Ostomy/Wound Manag.* 2002;48:64–68. [PubMed] [Google Scholar]
5. Orgill D.P. utilises negative pressure wound therapy on open chest or sternotomy wounds. *Ostomy/Wound Manag.* 2004;50(11A Suppl):15S–17S. [PubMed] [Google Scholar]
6. Orgill D.W., Austen W.G., and Butler C.E. Guidelines for treatment of complex chest wounds with negative pressure wound therapy. *Wounds (Suppl.)* 2004;16:1–23. [Google Scholar]
7. Ellis G.: How to Apply Vacuum-Assisted Closure Therapy *Nurs Stand.* 2016;30:36–39. [PubMed] [Google Scholar]
8. Fleischmann W., Becker U., Bischoff M., and Hoekstra H. Vacuum sealing: indication, technique, and results. *Eur J OrthopSurgTraumatol.* 1995;5:37–40. [PubMed] [Google Scholar]
9. CollingeC., Reddix R. The incidence of wound complications related to negative pressure wound therapy power outages and interruption of treatment in orthopaedic trauma patients. *J Orthop*

- Trauma*. 2011;25:96–100. [PubMed] [Google Scholar]
10. Marks M.W., Argenta L.C., and Thornton J.W. Rapid expansion: experimental and clinical experience. *Clin Plast Surg*. 1987;14:455–463. [PubMed] [Google Scholar]
  11. Orgill D.P., Manders E.K., and Sumpio B.E. The mechanisms of action of vacuum-assisted closure: more to learn. *Surgery*. 2009;146:40–51. [PubMed] [Google Scholar]
  12. Mouës C.M., Vos M.C., van den Bemd G.J., Stijnen T., Hovius S.E. Bacterial load in relation to vacuum-assisted closure wound therapy: a prospective randomised trial. *Wound Repair Regen*. 2004;12:11–17. [PubMed] [Google Scholar]
  13. Kairinos N., Voogd A.M., and Botha P.H. Negative-pressure wound therapy II: negative-pressure wound therapy and increased perfusion. Just an illusion? *Plast Reconstr Surg*. 2009;123:601–612. [PubMed] [Google Scholar]
  14. Hsu S., Thakar R., and Li S. haptotaxis of endothelial cell migration under flow. *Methods Mol Med*. 2007;139:237–250. [PubMed] [Google Scholar]
  15. Breen E., Tang K., Olfert M., Knapp A., Wagner P. Skeletal muscle capillarity during hypoxia: VEGF and its activation. *High Alt Med Biol*. 2008;9:158–166. [PubMed] [Google Scholar]
  16. Lund T., Wiig H., Reed R.K. Acute post-burn oedema: role of strongly negative interstitial fluid pressure. *Am J Physiol*. 1988;255:H1069–H1074. [PubMed] [Google Scholar]
  17. Argenta L.C., Morykwas M.J., Marks M.W., DeFranzo A.J., Molnar J.A., and David L.R. Vacuum-assisted closure: state of clinic art. *Plast Reconstr Surg*. 2006;117:127S–142S. [PubMed] [Google Scholar]
  18. Venturi M.L., Attinger C.E., Mesbahi A.N., Hess Cl., and Graw K.S. Mechanisms and clinical applications of the vacuum-assisted closure (VAC) device: a review. *Am J Clin Dermatol*. 2005;6:185–194. [PubMed] [Google Scholar]
  19. Saxena V., Hwang C.W., Huang S., Eichbaum Q., Ingber D., Orgill D.P. Vacuum-assisted closure: microdeformations of wounds and cell proliferation. *Plast Reconstr Surg*. 2004;114:1086–1098. [PubMed] [Google Scholar]
  20. Wilkes R.P., McNulty A.K., Feeley T.D., Schmidt M.A., Kieswetter K. Bioreactor for application of subatmospheric pressure to three-dimensional cell culture. *Tissue Eng*. 2007;13:3003–3010. [PubMed] [Google Scholar]
  21. Greene A.K., Puder M., and Roy R. Microdeformational wound therapy: effects on angiogenesis and matrix metalloproteinases in chronic wounds of three debilitated patients. *Ann Plast Surg*. 2006;56:418–422. [PubMed] [Google Scholar]
  22. Kairinos N., Solomons M., and Hudson D.A., The paradox of negative pressure wound therapy—in vitro studies. *J Plast Reconstr Aesthet Surg*. 2010;63:174–179. [PubMed] [Google Scholar]
  23. Guyton, A.C., eighth ed., Saunders; Philadelphia: 1991. Textbook of Medical Physiology; p. 1014. [Google Scholar]
  24. Timmers M.S., LeCessie S., Banwell P., and Jukema G.N. The effects of varying degrees of pressure delivered by negative-pressure wound therapy on skin perfusion. *Ann Plast Surg*. 2005;55:665–671. [PubMed] [Google Scholar]
  25. Fang R., Dorlac W.C., and Flaherty S.F. Feasibility of negative pressure wound therapy during intercontinental aeromedical evacuation of combat casualties. *J Trauma*. 2010;69(suppl 1):S140–S145. [PubMed] [Google Scholar]
  26. Borgquist O., Ingemansson R., and Malmsjö M. The influence of low and high pressure levels during negative-pressure wound therapy on wound contraction and fluid evacuation. *Plast Reconstr Surg*. 2011;127:551–559. [PubMed] [Google Scholar]
  27. Morykwas M.J., Argenta L.C., Shelton-Brown E.I., and McGuirt W. Vacuum-assisted closure: a new method for wound control and treatment. Animal studies and a basic foundation. *Ann Plast Surg*. 1997;38:553–562. [PubMed] [Google Scholar]
  28. Morykwas M.J., Faler B.J., Pearce D.J., and Argenta L.C. Effects of varying levels of subatmospheric pressure on the rate of granulation tissue formation in experimental wounds in swine. *Ann Plast Surg*. 2001;47:547–551. [PubMed] [Google Scholar]
  29. Kairinos N., Solomons M., and Hudson D.A., Negative-pressure Wound Therapy I: The Paradox of Negative-Pressure Wound Therapy. *Plast Reconstr Surg*. 2009;123:589–598. discussion 599–600. [PubMed] [Google Scholar]
  30. Streubel P.N., Stinner D.J., and Obrebsky W.T. Use of negative-pressure wound therapy in orthopaedic trauma. *J Am Acad Orthop Surg*. 2012;20:564–574. [PubMed] [Google Scholar]
  31. Apelqvist J., Armstrong D.G., Lavery L.A., Boulton A.J., Resource utilisation and economic costs of care based on a randomised trial of vacuum assisted closure therapy in the treatment of diabetic foot wounds. *Am J Surg*. 2008;195:782–788. [PubMed] [Google Scholar]
  32. Philbeck T.E., Jr., Whittington K.T., Millsap M.H., Briones R.B., Wight D.G., Schroeder W.J. The clinical and cost-effectiveness of externally applied negative pressure wound therapy in the treatment of wounds in home healthcare medical patients. *Ostomy/Wound Manag*. 1999;45:41–50. [PubMed] [Google Scholar]