

Medical Images

Acinic Cell Carcinoma: A Twist in the Tale

Noopur Managoli Kulkarni¹, Roshini Vinod², Sujit Londhe³, Shailesh Gawande⁴

¹Reader, ²Senior Lecturer, ^{3,4}Consultant Dental Surgeon, Dept. of Oral Pathology and Microbiology, Pandit Deendayal Upadhyay Dental College, Maharashtra 413255, India.

How to cite this article:

Noopur Managoli Kulkarni, Roshini Vinod, Sujit Londhe et al. Acinic Cell Carcinoma: A Twist in the Tale. Indian J Pathol Res Pract. 2020;9(1):93-94.

Corresponding Author:

Noopur Managoli Kulkarni, Reader, Dept. of Oral Pathology and Microbiology, Pandit Deendayal Upadhyay Dental College, Maharashtra 413255, India.

E-mail: drnoopurmanagoli@gmail.com

Received on 14.12.2019

Accepted on 08.01.2020

Acinic cell carcinoma accounts for 17% of all the salivary gland malignancies. Parotid gland is a massively involved gland with female prevalence. The word 'Acinus' is derived or originated due to the histologic resemblance of the tumor invading cells to the parenchymatous cells of the gland.¹

Diagnosis of this lesion can be misleading at times, due to its resemblance to the normal parotid tissue.² This tumor presents itself in a variety of histological patterns like Acinar-lobular, microcystic, follicular, papillary, cystic, medullary, ducto-glandular, primitive tubular. A panel of tumor markers like CK7, CD56, CD57 and so on can be used in immunohistochemistry for the diagnosis of acinic cell carcinoma (Fig. 1).

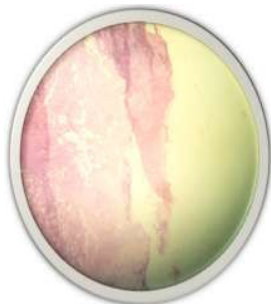

Fig. 1: Scanner view revealing vacuolated cells, with clear cell changes, solid microcystic variant of acinic cell carcinoma.

Diagnosis using imaging studies can prove to be difficult, due to its similarity with benign lesions.³ Total parotidectomy followed by radiotherapy is the preferred mode of treatment (Fig. 2).

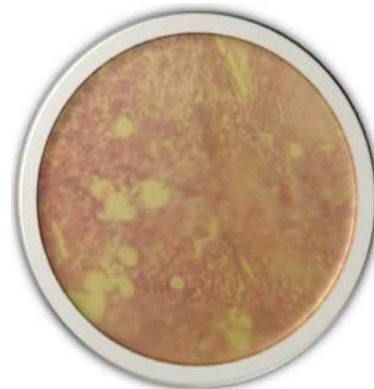


Fig. 2: High power view of acinic cell carcinoma with evidence of hemorrhage, areas of comedonecrosis, with mild perineural invasion and inflamed stroma.

References

1. Nabil Al Zaher et al. Acinic cell carcinoma of salivary glands. A literature review. Hematology/Oncology and stem cell therapy. 2009 Jan-Mar;2(1):259-64.

2. Rosero DS, Alvarez R, Gambó P, et al. Acinic Cell Carcinoma of the Parotid Gland with Four Morphological Features. *Iran J Pathol* 2016;11(2):181-185.
3. Sepúlveda I, Frelinghuysen M, Platin E, et al. Acinic cell carcinoma of the parotid gland: a case report and review of the literature. *Case Rep Oncol*. 2015 Jan 13;8(1):1-8. doi:10.1159/000371340

