

Comparative Study of Foramen Magnum in Dry Cadaveric Skulls and Computerized Tomography Images in North Interior Part of Karnataka Region

¹Mohammad Tahir K Qureshi, ²Ishwar B Bagoji ³R S Bulagouda, ⁴Gavishiddappa A Hadimani, ⁵M Lakshmi Narayan, ⁶Anand V Nimbale

How to cite this article:

M K Qureshi, R S Bulagouda, Gavishiddappa A. Hadimani et al. /Comparative Study of Foramen Magnum in Dry Cadaveric Skulls and Computerized Tomography Images in North Interior Part of Karnataka Region./Indian J Anat. 2022;11(1):9-14.

Author's Affiliation: ^{1,2,3}Assistant Professor, Department of Anatomy, ⁶Professor and HOD, Department of Dentistry, Sri BM Patil Medical College, (Blde Deemed to be University) Vijayapura, Karnataka 586103, India, ^{4,5}Assistant Professor, Department of Community Medicine, Hassan Institute of Medical Sciences, Hassan, Karnataka 573201, India.

Corresponding Author: Ishwar B Bagoji, Assistant Professor, Department of Anatomy, Sri B M Patil Medical College, (Blde Deemed to be University) Vijayapura, Karnataka 586103, India.

E-mail: ishwarbagoji@gmail.com

Received on: 04.04.2022

Accepted on: 27.04.2022

Abstract

The foramen magnum (FM) is a unique and complex anatomical opening in the base of the skull, which the posterior cranial fossa communicates with the vertebral canal. It is also related to a number of pathological conditions, including Chiari malformations, various tumours, and occipital dysplasias. The study aimed to compare and evaluate the foramen magnum morphology in dry skulls and CT scan images. **Material and methods:** The morphology of the foramen magnum was assessed in 118 adult non-pathological dry human skulls and 3D computer tomography images in 118 individuals (66 male, 52 female) aged 18–75 years. **Result:** the incidence of various shapes of the foramen magnum was observed the most common shape was oval (33.89%) in skulls, followed by round (15.25%), tetrahedral (13.55%), pentagonal (7.32%), hexagonal (16.94%) and irregular (12.71%). The mean anteroposterior 33.76 ± 2.1mm & 28.09 ± 1.9 mm transverse diameter of the foramen magnum. The minimum and maximum values for AP diameter were 31.78 & 39.13. In the CT scan study, the mean anteroposterior diameter of FM in the male 35.96 ± 3.7 and 33.85 ± 3.5 in females. The transverse diameter in males 30.38 ± 3.5 and 27.83 ± 2.5 in females. The FMI was observed in males 85.48 ± 9.1 and 83.26 ± 9.0 in female. **Discussion:** Results provides baseline data for the anatomist and important information for neurosurgeons to approach the cranial base with maximum safety and minimum mortality and morbidity.

Keywords: Foramen magnum, morphological variation, Cervico-medullary junction, Transcondylar approach.

Introduction

The base of the skull presents the most conspicuous structure called the foramen magnum, which is formed in the occipital bone and separates the brain above from the spinal cord below. The foramen magnum is constructed by the fusion of four parts of the occipital bone (pars squama pars right and left lateralis and pars basilaris)¹. The posterior part of the foramen magnum, known as the neurovascular compartment, contains the caudal portion of the medulla oblongata, meninges, cerebrospinal fluid, vertebral blood vessels, anterior and posterior spinal arteries and the spinal root of accessory nerves; the anterior part of it is known as Osseo-ligamentary compartment.² The knowledge of the change in the anatomical configuration and shape of the foramen magnum disturbs the vital structures passing through it and emerges the surgical approach in foramen magnum brain herniation Foramen magnum meningioma achondroplasia, foramen magnum dermoid cyst and Arnold Chiari syndrome.³⁻⁵



Materials and Methods

The present study was conducted on 118 adult non-pathological dry human skulls of unknown ageprocured from the Bone bank Department of Anatomy, Shri B M Patil Medical college BLDE (Deemed to be University), Vijayapur, Karnataka, for the duration of one year. On the other hand, to compare morphometry of dry bone after taking approval from the institutional ethical committee, we examined 118 computed tomographic images of both sexes (Male 66, Female 52) aged between 18-75. The CT images were collected from the Department of Radiology and Imaging, Shri B M Patil Medical College, BLDE (Deemed to be University), Vijayapur, Karnataka, India. The different shapes of FM were noted and classified as oval, round, egg, tetragonal, pentagonal, hexagonal and irregular shapes.

Inclusion Criteria

Fully ossified, dried, macerated skulls.

Adult cranial CT scan with complete foramen magnum.

Exclusion Criteria

Skulls with gross deformity.

CT scans with damaged foramen magnum associated with pathological condition were excluded from the study

All the dry skull parameters were obtained with the help of a digital sliding calliper with an accuracy of 0.01 mm—statistical analysis made by using SPSS Anova Software. The following parameters were measured:

1. The anteroposterior (AP) diameter of the FM was defined as the distance from basion to opisthion and measured.
2. The transverse diameter (TR) of the FM was defined as the distance between the foramen's lateral margins at the point of greatest lateral curvatures and measured.
3. FM index (FMI) calculated using the following formula: Foramen Magnum Index $\frac{1}{4}$ Maximum transverse diameter Maximum AP diameter 100. The shape of the foramen magnum was assessed and classified oval round, pyriform, arrow pentagonal and hexagonal.

Results

In dry Skulls

In the present study, the incidence of various shapes of the foramen magnum was observed the most common shape was oval (33.89%) in skulls, followed by round (15.25%), tetrahedral (13.55%), pentagonal (7.32%), hexagonal (16.94%) and irregular (12.71%) (Table-1) (figure 1). The mean anteroposterior (Sagittal) & transverse diameter of the foramen magnum was found to be 33.76 ± 2.1 mm (mean \pm SD) & 28.09 ± 1.9 mm, respectively. The minimum and maximum values for AP diameter were 31.78 & 39.13. The minimum and maximum transverse diameter of the foramen magnum was 21.07 & 30.82 mm. The minimum and maximum values for FMI were 73.88 & 97.98, respectively (Table-2).

In CT images

The various parameters of the foramen magnum of CT scans showed eight varying morphological shapes were identified and reported (Table 3). Oval, round, egg shape, tetrahedral, pentagonal, hexagonal and irregular. The most common shape of the foramen magnum identified in the CT image was the oval shape, found in (26.27%). The most diminutive shape of FM observed in irregular shape (9.32%). Egg shape in (12.71%), tetrahedral (10.16%), round shape (11.01%), pentagonal (14.40%) hexagonal (15.25%) (Figure 2). For the present study, we observed the mean anteroposterior diameter of FM in the male subject was 35.96 ± 3.7 and in females was 33.85 ± 3.5 , respectively. The transverse diameter in males and females was 30.38 ± 3.5 and 27.83 ± 2.5 , respectively. The FMI was observed in males and females as 85.48 ± 9.1 , 83.26 ± 9.0 respectively (Table-4).

Table 1: Morphological variations of Foramen Magnum in dry skulls

Shape	Number	%
Round	18	15.25
Oval	40	33.89
Tetrahedral	16	13.55
Pentagonal	9	7.62
Hexagonal	20	16.94
Irregular	15	12.71

Table 2: Dimensions of Foramen Magnum in dry skulls

Total no (N)-118	Anteroposterior Diameter (mm)	Transverse Diameter (mm)	Foramen Magnum Index
Mean \pm SD	33.76 ± 2.1	28.09 ± 1.9	84.65 ± 6.3
Minimum	31.78	21.07	73.88
Maximum	39.13	30.82	97.98

Table 3: Morphological variations of Foramen Magnum in CT scan images.

Shape	No	%
Oval	31	26.27
Egg	15	12.71
Round	13	11.01
Tetrahedral	12	10.16
Pentagonal	17	14.4
Hexagonal	18	15.25
Irregular	11	9.32

Table 4: Dimensions of Foramen Magnum in CT scan images

Total no (N)-118	Male	Female
Anteroposterior Diameter (mm)	35.96±3.7	33.83±3.5
Transverse Diameter (mm)	30.38±3.5	27.83±2.5
FMI (mm)	85.48±9.1	83.26±9.0

CT is a reliable diagnostic tool for the accurate measurement of transverse and AP diameter of the foramen magnum

Discussion

The study of foramen magnum gained interest in the field of clinical science, anthropology, comparative anatomy and evolutionary biology.⁶ The base of the skull presents an important anatomical opening called the foramen magnum, which communicates the posterior cranial fossa with the vertebral canal. During fetal development, the anterior and lateral aspects of the FM are formed from the basioccipital, the exoccipitals, and their respective interoccipital synchondroses anterior while the posterior boundary of the foramen is formed by the supraoccipital, the exoccipitals, and their corresponding interoccipital synchondroses posterior. The fetal growth centers do not fully ossify until approximately 10 years of age until which time both the size and shape of the FM are undergoing change. Between the 7th month in utero and birth, the rate of FM growth in its sagittal dimension is 5.4% greater than that of its transverse dimensions⁷. Between birth and 0.5 years, the opposite trend is observed – the rate of transverse growth is 7.6% faster than that of sagittal growth⁷. Mean adult sagittal lengths are attained by 5 years of age, whereas mean transverse lengths are not attained until 10 years of age.⁷

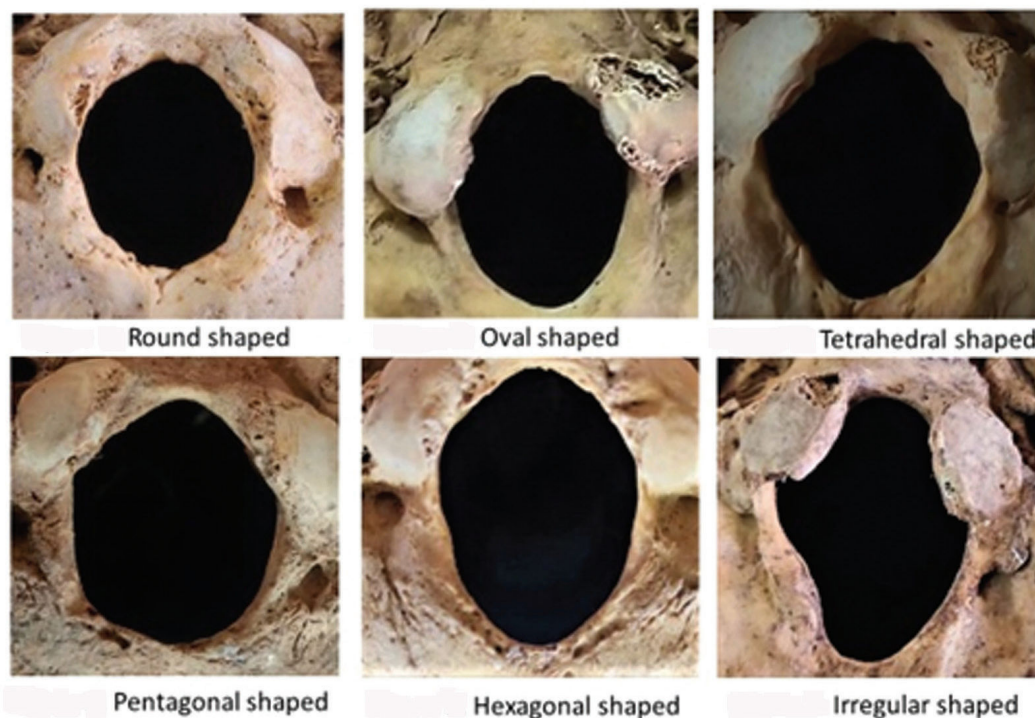


Figure. 1 Different shapes of the foramen magnum in dry skulls.

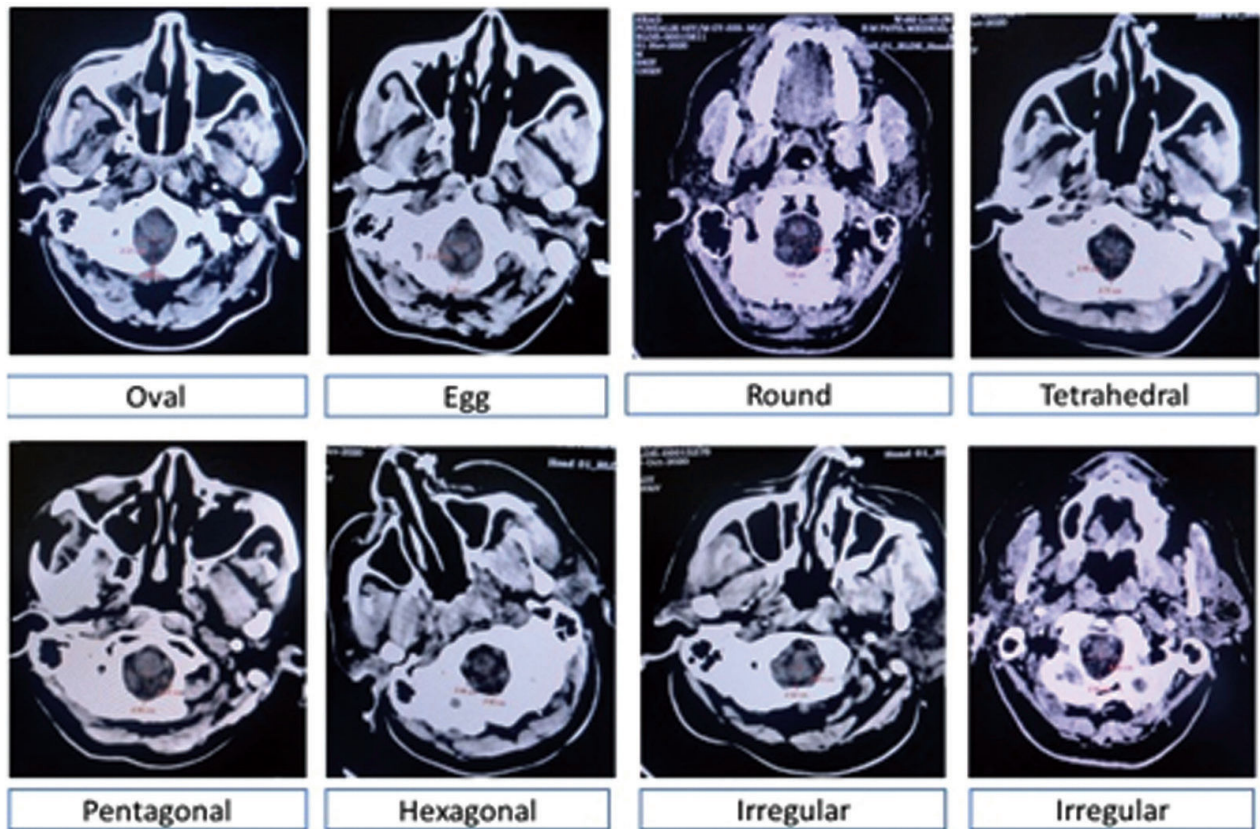


Fig. 2 Different shapes of foramen magnum as studied in CT scans

Biological and non-biological factors play an important role in the regulation of the development of foramen magnum. Genetical, hormonal, nutritional and muscles are the main biological factors, non-biological factors include abnormal fetal position in uterine cavity enhance the change in the muscle attachment this may be the cause for variation in the shapes of the foramen magnum.⁸

The literature of foramen magnum reports on the area of the foramen magnum and its variations. The most common shape of the foramen magnum in our study observed in both dry and CT images was oval shape (33.89 & 26.27%), while the least common shape found in the dry skull was pentagonal (7.62%) and in CT image irregular shape (9.32). Other variant shapes of FM observed both in the dry skull, and CT image were round (15.25%) & (11.01%). Pentagonal shape (7.62%) and (14.40%), the hexagonal shape (16.94%) and (15.25%). The round-shaped foramen magnum provides a larger operative angle for a better approach and requires less bone extraction for the neurosurgeons⁹. Thus, in the Indian population, the neurosurgeon has to go for osteotomy for a better transcondylar approach, as the shape of this foramen is oval in most of the subjects¹⁰. In an ovoid type of the FM,

the ability of the surgeon to adequately expose the anterior portion of the FM might be difficult¹⁰. In our study, the shape of the FM varied and the ovoid FM was demonstrated in both dry skull and CT image (33.89% & 26.27%), of the specimens. Garcia et al.¹¹ have found 45% of oval shape FM in their CT scan study, which is higher than our CT scan study findings. Murshed et al. have found 8.1% of oval shape FM, which is much lower than our CT scan study values. In a study of 200 skulls, Zaidi and Dayal¹² reported that oval FMs were found in 128 (64%) skulls. Sindel et al.¹³ and Langetal.¹⁴ reported that this shape was not found in more than 18.94% and 22.35%, respectively, of their samples. Other types with their respective frequencies of occurrence have been found as tetrahedral, pentagonal and hexagonal and, in our study, the least irregular shape achieved (12.71%) (9.32%) in both dry skull and CT scans, similar findings were described by many authors (Chethan Petal 2012¹⁵, Natsis Ketal 2013¹⁶). The irregular shape of FM is highlighted by the developmental cranial anomalies of the bone and soft tissues at the craniovertebral junction (Furtado S et al 2010). Murshed et al. have found 9.09% of irregular (B) shape in their study, which is almost similar to our results. However, Garcia et al.¹¹.

have not classified the irregular shape further into irregular (A) and irregular (B). The sagittal diameter is generally larger than the transverse diameter, which was also observed in our study. In the present study, the anteroposterior and transverse diameter of FM in dry skull 33.76 ± 2.1 mm and 28.09 ± 1.9 mm & in CT scans 35.96 ± 3.7 mm and 30.38 ± 3.5 , which were consistent with the findings of Sampada PK et al¹⁷. Catalia - Herrera¹⁸ reported 35 mm for the sagittal and 30.5 mm for the transverse diameters. Similar finding in CT scan reported in a series Gruber et al¹⁹ in 2009, Uthman, AT et al²⁰ In males the mean area was greater (828.92 ± 113.25 mm²) than in females (754.46 ± 107.69 mm²). The FMI in dry skull 84.65 ± 6.3 mm, and CT image in male 85.48 ± 9.1 mm and 83.26 ± 9.0 mm. Kanodia G et al²¹ evaluated the dimensions of FM in the dry skull as well as in living by CT scan, they reported AP diameter as 34.1 ± 2.9 mm and transverse diameter as 27.5 ± 2.5 mm in the dry skull while there was no significant difference, but AP diameter of the dry skull was larger than CT scan group. Results of this study provide a baseline useful data that enables surgeons to perform effective and reliable surgery in FM and in mastoid region²² with maximum safety. A large foramen magnum usually results from chronic increased intracranial pressure or from direct effects of an expanding process within the foramen magnum (syringomyelia, Arnold-Chiari malformation). Asymmetry of the foramen magnum occurs with craniovertebral anomalies or premature synostosis of one or more of the occipital synchondroses. A keyhole shaped foramen magnum has been described in the hydrocephalus syndrome. Achondroplasia is the most common syndrome with a small foramen magnum, but other skeletal dysplasia's and disorders associated with sclerosis of the skull can also lead to a small foramen magnum.

Conclusion

The foramen magnum is an important landmark of the base of the skull and is of particular interest to many fields of medicine. Specific neuro-anatomical structures and their lesions in foramen magnum, require particularly microsurgical intervention, choosing and establishing the most suitable surgical techniques need for accurate planning mainly based on the foramen magnum morphometry to refrain from any neurological injury.

References

1. Murshed KA, Cicekcibasi AE, Tuncer I. Morphometric evaluation of the foramen

- magnum and variations in its shape: A study on computerized tomographic images of normal adults. *Turk J Med Sci.*, 2003;(33):301-6.
2. Hadimani GA, Desai SD, Bagoji IB, Sahana BN. Bilateral variation in the origin of vertebral artery. *J Pharm Sci Res*, 2013; 5(10):196-198.
3. Bagoji IB, Doshi MA, Hadimani GA, Bannur BM. Fenestration of Proximal Segment of the Basilar Artery. *J. Pharm. Sci. & Res.* 2016;8(8): 934-935.
4. Hecht JT, Horton WA, Reid CS, Pyeritz RE, Chakraborty R. Growth of the foramen magnum in achondroplasia. *Am J Med Genet.* 1989;32(4):528-35.
5. Gavishiddappa A. Hadimani et al. Study on variations in the branching pattern of arch of aorta. *Int J Pharm Pharm Sci*, 2015;7(9):515-517.
6. Zdilla MJ, Russell ML, Bliss KN, Mangus KR, Koons AW. The size and shape of the foramen magnum in man. *J Craniovertebr Junction Spine.* 2017;8(3):205-21.
7. Richards GD, Jabbour RS. Foramen magnum ontogeny in Homo sapiens: A functional matrix perspective. *Anat Rec (Hoboken)* 2011;29(4):199-216.
8. Burdan F, Umlawska W, Dworzański W, Klepacz R, Szumiło J, Starosławska E, Drop A. Anatomical variances and dimensions of the superior orbital fissure and foramen ovale in adults. *Folia Morphol.* 2011;70: 263-71.
9. Divya M, Gaurav A, Abha S, Rahat B. An anatomical perspective of human occipital condyles and foramen magnum with neurosurgical correlates. *International journal of clinical and experimental anatomy.* 2013;6(7):29-33.
10. Radhakrishna SK, Shivarama CH, Ramakrishna A, Bhagya M. Morphometric Analysis of Foramen Magnum for Sex Determination in South Indian Population. *NUJHS.* 2012;2(1):20-22.
11. Garcia E. E., Carlos A. P., Leandro O. B., Erika C. L., Hector S. M. Tomographic morphometry of the foramen magnum and its relation to sex and Mapuche ethnicity. *Academic Journals Database.* 2011;5(1):28-31.
12. Zaidi SH, Dayal SS. Variations in the shape of foramen magnum in Indian skulls. *AnatAnz.* 1988;167(4):338-40.
13. Sindel M, Ozkan O, Ucar Y. Foramen magnum anatomic variation. *Akd U Tip Fak Dergisi.* 1989; 6:97-102.
14. Lang VJ, Schafhauser O, Hoffmann S. Uber die postnatale Entwicklung der transbasalen Schadelporten: Canalis caroticus, foramen jugulare, canalis hypoglossalis, canalis condylaris und foramen magnum. *AnatAnz.* 1983;153:315-57.
15. Chethan P, Prakash KG, Murlimanju BV, Prashanth KU et al. Morphological analysis and morphometry of the foramen magnum:

- an anatomical investigation. *Turk Neurosurg.* 2012;22(4):416-19.
16. Natsis K, Piagkou M, Skotsimara G, Piagkos G, Skandalakis P. A morphometric anatomical and comparative study of the foramen magnum region in a Greek population. *Surg. Radiol. Anat.* 2013;35(10):925-34.
 17. Sampada PK, Poornima B, Mallikarjun M, Sakri SB. Morphometric and morphological study of the foramen magnum in dried human skull bones. *Int J Anat Res.* 2017;5(2.1):3682-86.
 18. Catalina- Herrera CJ Study of the anatomic metric values of the foramen magnum and its relation to sex. *Acta Anat (Basel).* 1987; 130:344-7
 19. Gruber P, Henneberg M, Boni T, Ruhli FJ. Variability of human foramen magnum size. *Anat Rec.* 2009; 292:1713-9.
 20. Uthman, AT. Al-Rawi, N. H. & Al-Timimi, JF. Evaluation of the foramen magnum in gender determination using helical CT scanning. *Dentomaxillofac. Radiol.* 2012;41(3):197-202,
 21. Kanodia G, Parihar V, Yadav YR, Bhatele PR, Sharma D. Morphometric analysis of posterior fossa and foramen magnum. *J Neurosci Rural Pract.* 2012;3(3):261-66.
 22. Hadimani GA, Bagoji IB. Study of mastoid canals and grooves in North Karnataka human skulls. *J Clin Diagn Res.* 2013;7(8):1537-1539.

