

## A Correlation of Preoperative Ultrasound Parameter to Cormack-lehane Classification in Predicting Difficult Laryngoscopy

Avani Shah<sup>1</sup>, Hitendra Kanzariya<sup>2</sup>, Neeta Bose<sup>3</sup>

<sup>1</sup>Senior Resident, <sup>2</sup>Assistant Professor, Department of Anesthesiology, Parul Institute of Medical Sciences and Research, Parul University, Waghodia, Vadodara, Gujarat 391760, India. <sup>3</sup>Associate Professor, Department of Anesthesiology, GMERS Medical College, Gotri, Vadodara, Gujarat 390021, India.

### Abstract

**Background:** Prediction of difficult airway is a challenging task. Commonly used airway assessment screening tests has high interobserver variability and low predictability in detecting difficult airway. Ultrasound could be a helpful tool in the prediction of these difficulties. **Objectives:** The purpose of this study was to evaluate the ability of preoperative ultrasound assessment of anterior neck soft tissue thickness in predicting difficult laryngoscopy in patients undergoing during elective surgery requiring tracheal intubation. **Design:** Prospective; Double blind; Observational study. **Patients:** A total of 100 patients aged more than 18 years, without neck pathologies undergoing general anesthesia and tracheal intubation were included in the study. **Outcome Measures:** Ultrasound distance from skin surface to anterior commissure of vocal cord (DSVC) was recorded with a linear 6 to 13 MHz ultrasound transducer preoperatively. Postoperative anesthesia record was analyzed for Cormac Lehane grades during laryngoscopy. **Results:** The DSVC cutoff value of 0.51 cm was the best predictor of Cormack Lehane grade more than 2 at direct laryngoscopy and of difficult intubation, (sensitivity 78.3%, specificity 74%). The mean (SD) of DSVC was 0.53 (0.12) cm in the difficult laryngoscopy group and 0.40 (0.14) cm in the easy laryngoscopy group, ( $p < 0.001$ ). **Conclusion:** The noninvasive prediction of difficult laryngoscopy can be done by airway ultrasound. The distance of 0.51 cm or more at the level of vocal cord can predict potential difficult laryngoscopy in patients undergoing anesthesia with endotracheal intubation.

**Keywords:** Ultrasonography; Difficult airway; Direct laryngoscopy.

### How to cite this article:

Avani Shah, Hitendra Kanzariya, Neeta Bose. A Correlation of Preoperative Ultrasound Parameter to Cormack-lehane Classification in Predicting Difficult Laryngoscopy. Indian J Anesth Analg. 2020;7(1 Part -I):9-14.

### Introduction

Anticipated as well as unanticipated difficult airway remained a challenge for clinician. The incidence of difficult intubation was reported ranging from about 5% to 11% in different settings,

such as patients under general anesthesia and critically ill patients in the emergency department and intensive care unit.<sup>1-3</sup> Failed or delayed intubation is associated with significant morbidity and mortality.<sup>4</sup> The incidence of failed intubation is about 1 in 1 to 2000 in elective surgical cases<sup>5,6</sup> and about 1 in 50 to 100 in the emergency scenarios.<sup>7,8</sup>

**Corresponding Author:** Hitendra Kanzariya, Assistant Professor, Department of Anesthesiology, Parul Institute of Medical Sciences and Research, Parul University, Waghodia, Vadodara, Gujarat 391760, India.

**E-mail:** [avani.nhl@gmail.com](mailto:avani.nhl@gmail.com)

**Received on** 17.10.2019, **Accepted on** 28.11.2019



This work is licensed under a Creative Commons Attribution-NonCommercial-ShareAlike 4.0.

Careful assessment, planning and preparation before the procedure can help in avoiding airway complications.

Classic prediction criteria essentially deal with surface anatomy. They scan for some factors that are associated with difficult intubation but fails to address others. A meta-analysis reported that only 35% of difficult intubations had a Mallampati score of III or IV.<sup>9</sup> Ultrasound imaging provides a simple and noninvasive technique for the clinical assessment of the patient's airway. Currently multiple parameters are being investigated for preintubation airway assessment, but it has remained unclear as to which sonographic parameters can be useful as predictors of difficult laryngoscopy and intubation.<sup>10</sup>

Of available ultrasound parameters for prediction of difficult intubation, anteriorneck soft tissue thickness at the level of vocal cord is of importance. There is very limited literature available evaluating this parameter for predicting difficult laryngoscopy. In the current study, we evaluated performance of ultrasonographic and clinical parameters in predicting difficult laryngoscopy.

## Materials and Methods

A prospective, double-blinded observational study enrolling patients undergoing elective surgery under general anesthesia was conducted at the preoperative area and the operation theatre complex of a tertiary care hospital. After institutional ethics committee approval and informed consent, adult patients with age of 18 years or above, who were scheduled for elective surgery requiring general anesthesia with direct laryngoscopy and tracheal intubation, were included in the study.

Patients were excluded if they had contraindications for a proper direct laryngoscopy including limited mouth opening, head and neck pathologies, underwent tracheostomy, had limited neck extension ( $< 30^\circ$ ) or refused to participate in the study. The age, sex, body height, body weight, body mass index and the Mallampati (MP) classification (Appendix 1) of the patients were recorded.

### Measurements and image acquisitions

All the sonographic measurements were done in the preoperative holding area by a single operator. The operator was anesthesiology resident and had acquired the basic operating technique in using ultrasonography. The operator spent one month practicing the technique for obtaining the standard

ultrasound image under qualified radiologist before initiating the study.

Data were collected using the Sonosite portable ultrasound system, and the linear transducer (7–13 MHz) was employed with small part preset. The patient was positioned in supine position with active maximal head extension. Ample amount of gel was applied. The probe was placed in the midline and the neck is scanned in the transverse plane from cephalad to caudal direction until the scanning plane section through both the vocal cords, (Fig. 1). The thickness of anterior neck soft tissue was measured from skin to anterior commissure of the vocal cord (DSVC).

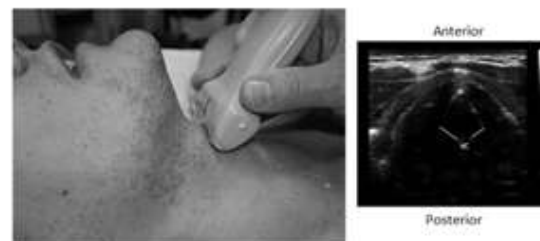

Fig. 1: Measurement of soft tissue neck thickness at the level of vocal cord

After receiving the patient in the operating room, patient was monitored with routine intraoperative monitors, including pulse oximetry, noninvasive blood pressure and electrocardiography. The technique of anesthesia was standardized for all the patients in the study. After anesthesia induction with injection propofol 2–2.5 mg/kg, fentanyl 1–2  $\mu\text{g}/\text{kg}$  and muscle relaxant vecuronium 0.1 mg/kg intravenously, direct laryngoscopy and endotracheal intubation was carried out by an anesthesiologist with at least two years of experience of performing the procedure. All the patients were put in neutral position without neck overextension or overbending. The Macintosh blade size 4 was used for laryngoscopy and no external laryngeal pressure was used to facilitate the view.

During the intraoperative laryngoscopy, the Cormack and Lehane (CL) grading was recorded.<sup>11</sup> In patients with a difficult airway, intubation was performed according to the Difficult Airway Society 2015 guidelines.<sup>12</sup> The anesthesiologists, who performed airway assessment for the patients in the operation, were blinded to our ultrasound assessment result.

The anesthetic records of the patients were reviewed for the grade of laryngoscope view using the Cormack and Lehane classification after the scheduled elective operations (Appendix 2).

Patients with a class III or IV view were assigned to the difficult laryngoscopy group, and those with a class I or II view were assigned to the easy laryngoscopy group.

The Statistical Package for Social Sciences (SPSS) version 22.0 for Windows was used for analysis. The Receiver Operating Characteristic (ROC) curve was drawn to assess the performance of the test, and the cut-point of DSVC for the most appropriate prediction the CL grades was determined. The sensitivity, specificity, positive and negative predictive values were calculated using the determined DSVC were compared with the Mallampati classification.

**Results**

Totally, 112 patients were scanned during the study period. Twelve cases were excluded from analysis due to the use of supraglottic airway device ( $n = 9$ ), regional anesthesia ( $n = 2$ ), postponement of surgery ( $n = 1$ ). One hundred patients were included in the final analysis. Demographic parameters are shown in (Table 1).

**Table 1:** Demographic data of the patients

Parameters	Range	Mean	SD
Age (years)	20-78	54.2	13.6
Weight (kg)	41.2-109.5	64.7	11.8
Height (cm)	119.5-182.1	161.4	10.2
Body mass index (BMI)	16.8-48.5	23.9	5.4

No difference was noted in age, sex, BMI, ASA status and MP grades (MPG) among easy and difficult laryngoscopy group. MP grades and CL grading distribution are shown in Table 2 and 3 respectively.

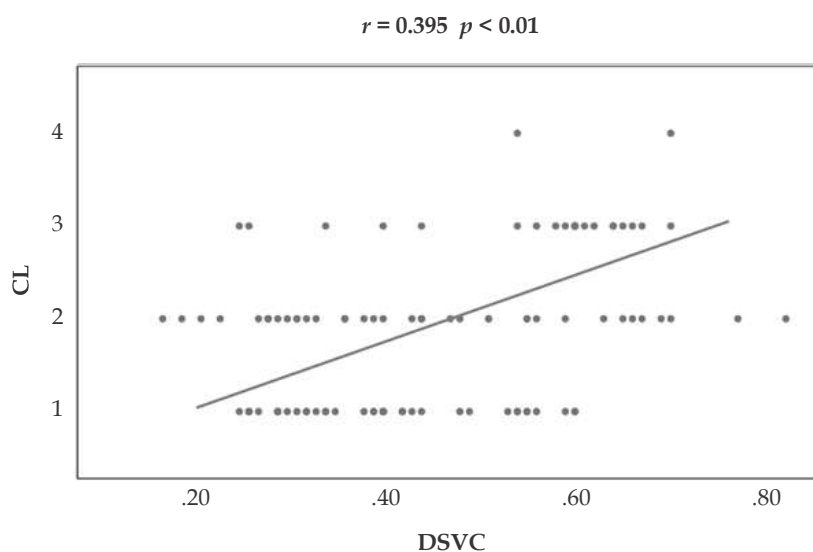
**Table 2:** Mallampati grading of the patients

MP grade	Percentage (%)
Grade 1	47
Grade 2	36
Grade 3	15
Grade 4	2

**Table 3:** Cormack-Lehane grading of the patients

CL grade	Percentage (%)
Grade 1	40
Grade 2	37
Grade 3	21
Grade 4	2

For the airway assessment results by the anesthetists, 77% of patients had CL classification grade either 1 or 2 and 23% patients had potential difficult laryngoscopy (CL classification Grade 3, or 4). The average time taken to complete the US examination of the patient’s airway was about 1.2 min. A correlation was computed to assess the relation between DSVC with Cormack Lehane grading. There was a weak positive correlation of DSVC with CL grading with a regression coefficient of  $r = 0.395$  ( $p < 0.01$ ) found, (Fig. 2).



**Fig. 2:** Scattered diagram of DSVC vs Cormac-Lehane grades

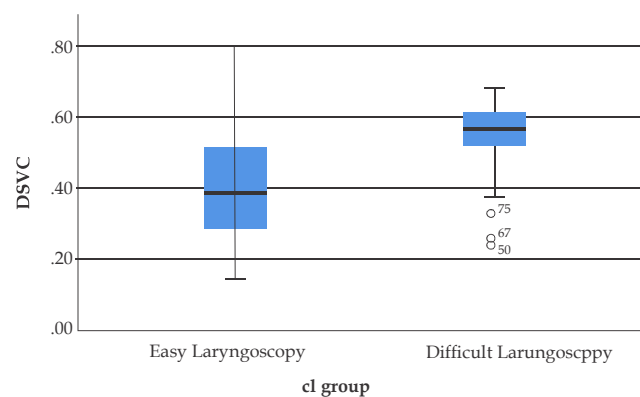
The ultrasonographic measurement in difficult and easy laryngoscopy group are compared in (Table 4).

The mean value of DSVC was  $0.53 \pm 0.12$  mm in difficult laryngoscopy group and  $0.40 \pm 0.14$  mm in easy laryngoscopy group which was statistically

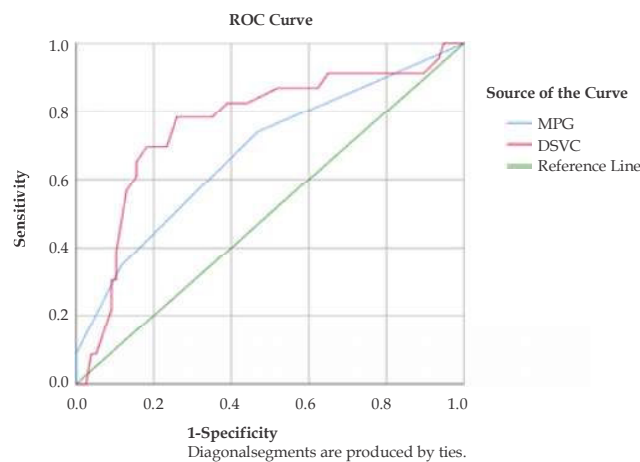
significant with  $p$  - value  $< 0.001$ . The distribution of the DSVC in the patients with easy laryngoscopy and in those with potential difficult laryngoscopy were demonstrated in the boxplot, (Fig. 3). The ROC curves for MP grades and DSVC are shown in (Fig. 4).

**Table 4:** Ultrasonographic measurements comparison

Parameter (mm)	Difficult Laryngoscopy ( $n = 23$ )		Easy Laryngoscopy ( $n = 77$ )		$p$ - value
	Mean	SD	Mean	SD	
DSVC	0.53	0.12	0.40	0.14	$<0.001$



**Fig. 3:** Boxplot for the distribution of DSVC in the patients with easy and difficult laryngoscopy group.



**Fig. 4:** Receiver Operating Characteristic (ROC) analyses for DSVC (pink line) and Mallampati grading (blue line). Cormack–Lehane grading of glottis exposure over II was considered the threshold of difficult laryngoscopy during the study. Green diagonal line = reference line.

The area under the ROC curves (AUCs) of DSVC and MPG was 0.763 and 0.679 respectively. The AUC of DSVC is more closure to 1 as compared to AUC of MPG indication more validity than MPG. The cut-off of DSVC of 0.51 mm was determined at the point on the ROC curve nearest to the upper

left corner of the ROC curve. The sensitivity and specificity of adopting the cut-off of DSVC of 0.51 mm were 78.3% and 74.0% ( $p < 0.001$ ) which is considered fair in the prediction of difficult laryngoscopy, (Table 5).

**Table 5:** Performance of DSVC and MPG

Test	AUC	Sensitivity	Specificity	PPV	NPV	p - value
DSVC	0.763	78.3%	74%	47.4%	91.9%	< 0.001
MPG	0.679	39.1%	88.3%	50%	82.9%	0.03

**Discussion**

The management of the airway remains a critical skill for anesthesiologist. Failed to secure airway is a major contributing factor for patients’ morbidity and mortality.<sup>13</sup> Currently used traditional indices of difficult airway are not 100% sensitive or specific.<sup>14</sup> Ultrasound has recently emerged as a new tool for airway assessment and prediction of difficult laryngoscopy.<sup>15</sup> The role of ultrasound is still in the primitive phase in airway assessment. Some authors have used ultrasound for predicting difficult airway, but till now, there has been little evidence about which ultrasound assessments are best predictors.<sup>16-18</sup>

In our study, we evaluated the distance from skin to vocal cords by ultrasound preoperatively and compared it with Cormack Lehane assessment during direct laryngoscopy. We also compared the performance of the ultrasound parameter with Mallampati grading in the prediction of difficult airway. The incidence of difficult laryngoscopy as assessed by Cormack Lehane grading was 23% in our study. This incidence was higher than the reported. In the current study, the comparative correlation of DSVC with CL grading for predicting difficult laryngoscopy showed moderate positive correlation.

In the present study, it was found that the measurement of the DSVC is a potential tool in airway assessment and a thickness of more than 0.51 cm correlated with the prediction of difficult intubation. In a study done by Alessandri et al.<sup>19</sup> the sonographic measurements of anterior neck soft tissue were greater in the difficult laryngoscopy group as compared to the easy laryngoscopy group. They compared the distance from skin to the hyoid bone, epiglottis, vocal cord, thyroid isthmus and trachea. they found distance from skin to vocal cord of 0.81 ± 0.20 cm was associated with difficult laryngoscopy.

In a similar study, that was conducted by Ezri et al.<sup>16</sup> comprising a Middle Eastern population, the investigators found that the amount of pretracheal soft tissue in the easy and difficult laryngoscopy groups was mutually exclusive. Patients in whom laryngoscopy was difficult had more pretracheal soft tissue (mean [SD] 28 [2.7] mm vs 17.5 [1.8] mm;

*p* < 0.001). However, in another study conducted in an American population, it was found that the anterior neck soft tissue thickness was not a good predictor of difficult laryngoscopy.<sup>17</sup> Population in both these studies were of different ethnic group and the incidence of obesity was also different from our study population. In our study, we found that MP was also a good predictor of difficult intubation. DSVC had high sensitivity in predicting difficult intubation than that of the MP class. The specificity and PPV were lower than the physical parameters. Ultrasound measurements of anterior neck soft tissue at the level of the VC could improve the predictive power of current standard clinical screening tests when combined with a Mallampati score. However, Adhikari et al.<sup>20</sup> demonstrated that the Mallampati clinical screening test did not correlate with ultrasound measurements.

We included only 100 adult patients of Indian/ Asian origin. Only 8% of our subjects were obese (BMI ≥ 30 kg/m<sup>2</sup>). We have evaluated only one sonographic parameter however, predicting difficult laryngoscopy with a set of parameters will become more valuable. All these are potential limitations of this study. Further, investigations can be done involving a more diverse study population including patient groups having factors known to cause difficult intubation such as pregnancy, obesity and syndromes involving the airway.

**Conclusion**

Ultrasonographic measurement of the DSVC is a potential predictor of difficult laryngoscopy. A value of more than 0.51 cm correlates well with Cormack Lehane grades for difficult laryngoscopy. It is also more sensitive than the physical parameters such as MP class. The growing interest in the use of ultrasound in airway assessment will be helpful in developing new predictors for difficult laryngoscopy.

**Appendix 1:** Mallampati classification.

- Class 1 Full visibility of tonsils, uvula, and soft palate
- Class 2 Visibility of hard and soft palate, and upper portion of tonsils and uvula

Class 3 Soft and hard palate and base of uvula

Class 4 Only hard palate visible

#### Appendix 2: Cormack–Lehane classification

Grade Laryngoscopic view

1. Full view of the vocal cords
2. Partial view of the glottis or arytenoids
3. Only epiglottis visible
4. Neither glottis nor epiglottis visible

#### References

1. Shiga T, Wajima Z, Inoue T. Predicting difficult intubation in apparently normal patients: A meta-analysis of bedside screening test performance. *Anesthesiology* 2005;103(2):429–37.
2. Combes X, Jabre P, Jbeili C. Prehospital standardization of medical airway management: Incidence and risk factors of difficult airway. *Acad Emerg Med* 2006;13(8):828–34.
3. De Jong A, Molinari N, Terzi N. Early identification of patients at risk for difficult intubation in the intensive care unit: Development and validation of the MACOCHA score in a multicenter cohort study. *Am J Respir Crit Care Med* 2013;187(8):832–39.
4. Cook TM and MacDougall-Davis SR. Complications and failure of airway management. *Br J Anesth* 2012;109(Suppl. 1):i68–i85.
5. Samsoon GL and Young JR. Difficult tracheal intubation: A retrospective study. *Anesthesia* 1987;42(5):487–90.
6. Rose DK and Cohen MM. The incidence of airway problems depends on the definition used. *Can J Anesth* 1996;43(1):30–34.
7. Sakles JC, Laurin EG, Rantapaa AA. Airway management in the emergency department: A one-year study of 610 tracheal intubations. *Ann Emerg Med* 1998;31(3):325–32.
8. Nolan JP and Kelly FE. Airway challenges in critical care. *Anesthesia* 2011;(66) Suppl 2:81–92.
9. Lee A, Fan LTY, Gin T, et al. A systematic review (meta-analysis) of the accuracy of the Mallampati tests to predict the difficult airway. *Anesth Analg* 2006;102(6):1867–878.
10. Chan SMM, Wong WY, Lam SKT. Use of ultrasound to predict difficult intubation in Chinese population by assessing the ratio of the pre-epiglottis space distance and the distance between epiglottis and vocal folds. *Hong Kong J Emerg Med* 2018;25(3):152–59.
11. Cormack RS, Lehane J. Difficult tracheal intubation in obstetrics. *Anesthesia* 1984;39:1105–111.
12. Frerk C, Mitchell VS, McNarry AF. Difficult Airway Society guidelines for management of unanticipated difficult intubation in adults. *Br J Anesth* 2015;115(6):827–48.
13. Apfelbaum JL, Hagberg CA, Caplan RA. American Society of Anesthesiologists Task Force on Management of the Difficult Airway. Practice guidelines for management of the difficult airway: An updated report by the American Society of Anesthesiologists Task Force on Management of the Difficult Airway. *Anesthesiology* 2013 Feb;118(2):251–270.
14. Tamire T, Demelash H, Admasu W. Predictive values of preoperative tests for difficult laryngoscopy and intubation in adult patients at tikuranbessa specialized hospital. *Anesthesiol Res Pract* 2019(Article ID 1790413):13.
15. Kundra P, Mishra SK, Ramesh A. Ultrasound of the airway. *Indian J Anesth* 2011 Sep;55(5):456–62.
16. Ezri T, Gewurtz G, Sessler DI. Prediction of difficult laryngoscopy in obese patients by ultrasound quantification of anterior neck soft tissue. *Anesthesia* 2003 Nov;58(11):1111–114.
17. Komatsu R, Sengupta P, Wadhwa A. Ultrasound quantification of anterior soft tissue thickness fails to predict difficult laryngoscopy in obese patients. *Anesth Intensive Care* 2007 Feb;35(1):32–37.
18. Rana S, Verma V, Bhandari S, et al. Point-of-care ultrasound in the airway assessment: A correlation of ultrasonography-guided parameters to the Cormack–Lehane Classification. *Saudi J Anesth* 2018 Apr-Jun;12(2):292–96.
19. Alessandri F, Antenucci G, Piervincenzi E. Ultrasound as a new tool in the assessment of airway difficulties: An observational study. *Eur J Anesthesiol* 2019;36(7):509–515.
20. Adhikari S, Zeger W, Schmier C. Pilot study to determine the utility of point-of-care ultrasound in the assessment of difficult laryngoscopy. *Acad Emerg Med* 2011 Jul;18(7):754–58.