

Relevance of Mast Cell Variations in Uterocervical Lesions

Gayathri M.N.¹, Meghana P.², Sruthi Madhusudanan³

How to cite this article:

Gayathri M.N., Meghana P., Sruthi Madhusudanan/Relevance of Mast Cell Variations in Uterocervical Lesions/Indian Journal of Pathology: Research and Practice 2023;12(3) 89-93.

Abstract

Context: Mast cells are a heterogeneous group of immune cells involved in a variety of biological processes. The presence of mast cells in tumours has been described as an evidence of a host immunologic anti-tumor response, and their abundance as an indicator of a favourable prognosis. However, it is also stated to be extremely closely associated with angiogenesis and tumour invasion. Because the literature on mast cells in uterocervical lesions is limited, the current study seeks to look for changes in mast cells in some of the common uterocervical lesions and their potential implications in diagnosis and prognosis.

Aims: To study the mast cell density in various neoplastic and non-neoplastic lesions of uterocervical lesions.

Settings and Design: Prospective study done over a period of one year in a tertiary care hospital.

Methods and Material: Hysterectomy specimens received in the department of pathology a tertiary care hospital, were stained with H&E and toluidine blue for the identification of mast cell.

Statistical Analysis used: For categorical variables, frequencies, proportions, Chi square test for proportion is used and for continuous variables, mean, standard deviation, independent t test will be used.

Results: The most common neoplastic and non-neoplastic lesions were leiomyoma and chronic cervicitis respectively and the highest mean mast cell count was more in non-neoplastic lesions.

Conclusions: The study revealed that the mast cell count decreased progressively from non-neoplastic and benign to malignant lesions, implying that the mast cell count appeared to be inversely related to the degree of dysplasia and thus may be an additional diagnostic tool in different uterocervical lesions and may act as a good prognostic indicator of the lesions' benign nature.

Keywords: Mast cells; Uterocervical lesions; Neoplastic; Non-neoplastic.

Author Affiliation: ¹Associate Professor, ³Post Graduate Student, Department of Pathology, Mysore Medical College and Research Institute, Mysore, Karnataka 570001, India, ²Senior Registrar, Department of Molecular Biology and Cytogenetics, Apollo Hospitals, Greams Road, Chennai, Tamil Nadu 600006, India.

Corresponding Author: Meghana P., Senior Registrar, Department of Molecular Biology and Cytogenetics, Apollo Hospitals, Greams Road, Chennai, Tamil Nadu 600006, India.

E-mail: meghanap.mp@gmail.com

Received on: 05.09.2023

Accepted on: 30.10.2023



This work is licensed under a Creative Commons Attribution-NonCommercial-ShareAlike 4.0.

INTRODUCTION

Paul Ehrlich identified and named mast cells in 1878. Mast cells serve a critical role in both innate and adaptive immunity.¹ These are a heterogeneous group of immune cells engaged in a variety of biological events. The multiple biologic functions of mast cell appear to be mediated by the variety of active molecules. There are no circulating mast cells under normal conditions because progenitor cells move to peripheral tissues as immature cells differentiating in situ. Mast cells are found in essentially all of the body's major organs and tissues, but due to their role in immunological mechanisms, they are mostly found at host environment interfaces such as the skin, airways, gastrointestinal, and urogenital tracts.²

Mast cells, when activated, produce preformed and newly synthesised mediators such as cytokines and chemokines. Mast cells have been found to infiltrate solid tumours in multiple studies conducted.³ Several other studies show that mast cells, by the use of different granules, are exceedingly related with angiogenesis and tumour invasion.⁴

Cervical cancer is India's second most frequent malignancy and third leading cause of cancer mortality, accounting for roughly 10% of all cancer related deaths.⁵ The literature on mast cell profile, on the other hand, is limited. Given this, the current study intends to evaluate the changes in mast cells in some common uterocervical lesions and their potential significance in diagnosis and prognosis.

SUBJECTS AND METHODS

Data for the present study was obtained from the hysterectomy specimens received in the department of pathology a tertiary care hospital, for over a period of one year (July 2021 to July 2022). Gestational uterus and autolysed hysterectomy specimens were excluded. Specimen received were fixed in 10% formalin and paraffin sections were prepared and stained with H&E for routine examination and toluidine blue for mast cells. Mast cells were counted in 10 consecutive high power fields in areas where maximum cells were seen.

RESULTS

A total of 104 hysterectomy specimens comprising of both neoplastic and non-neoplastic lesions, each constituting 52 cases were studied.

In our study majority of the specimens received were from patients of 30-40 years age group, followed by 41-50 years age group with the mean age of 45 years. The youngest was 30 and the oldest, 81 years old. (Fig. 1)

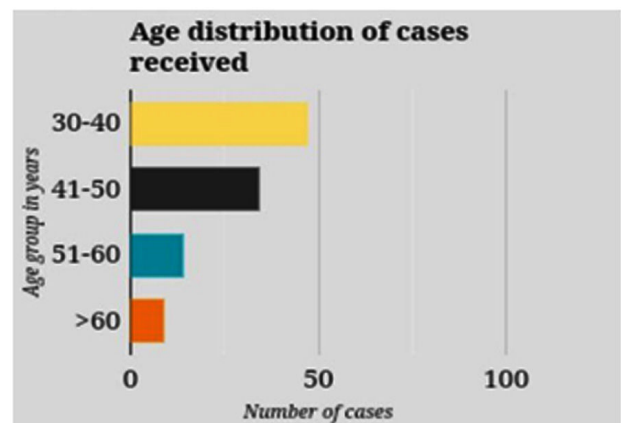


Fig. 1: Age distribution of cases received.

Among the neoplastic lesions, leiomyoma (38.46%) was the most common followed by keratinising squamous cell carcinoma cervix (17.31%) and HSIL (13.46%). In the keratinising squamous cell carcinoma cervix, 6 cases were well differentiated and 3 were moderately differentiated. (Fig. 2)

Among the non-neoplastic lesions of utero-cervix, chronic cervicitis (46.15%) was the most common, followed by chronic polypoidal endocervicitis (38.47%) and endometritis (15.38%).

Neoplastic lesions were more common in 30-40 years age group (44.23%), followed by 41-50 years age group (28.85%).

Non-neoplastic lesions were more common in 30-40 years age group (46.15%), followed by 41-50 years age group (36.54%). Least number of cases were seen in the age group >60 years (5.77%).

In non-neoplastic lesions, mast cell count per 10 high power fields were more in cases of leiomyoma ranging from 48-154 and with a mean of 86.24, whereas the malignant lesions such as endometrioid carcinoma, adenocarcinoma, squamous cell carcinoma and poorly differentiated carcinomas showed very few mast cells (<5/10 HPF).

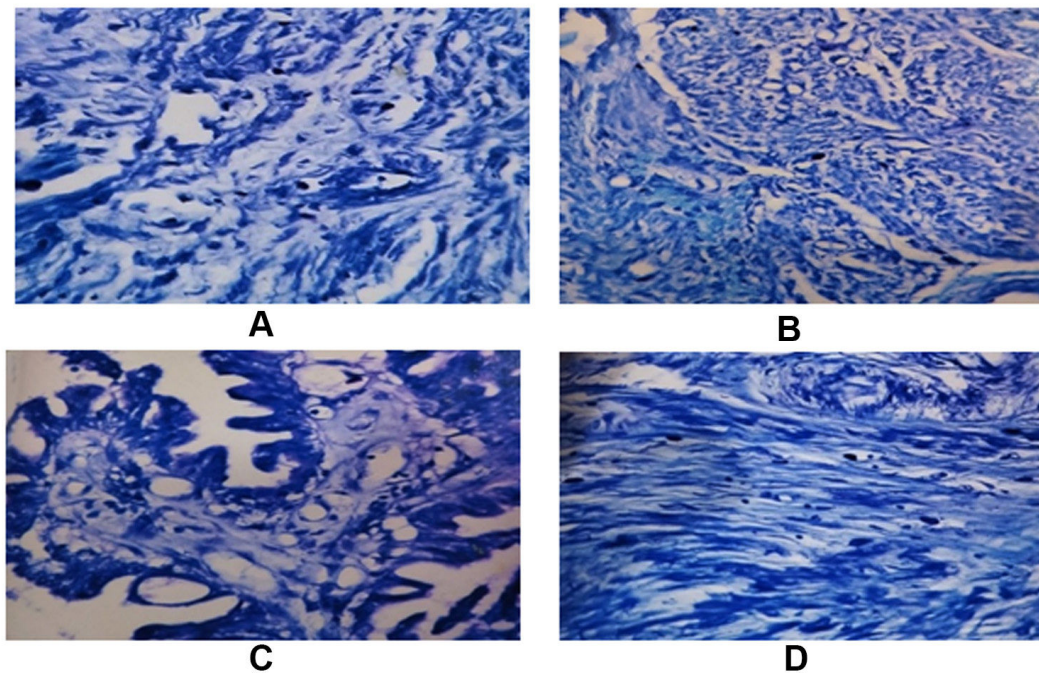


Fig. 2: Mast cells in a case of (A) Endometritis (B) Squamous cell carcinoma cervix (C) Villo-glandular variant of adenocarcinoma-cervix (D) Chronic polypoidal endocervicitis

The pre-malignant lesions like HSIL and atypical hyperplasia showed mast cells varying between 24-44 and 15-20 per high power fields respectively.

In the non-neoplastic uterocervical lesions, chronic polypoidal endo-cervicitis showed the highest mast cell count ranging between 48 and 75, with a mean of 61.85. Chronic cervicitis cases showed a mean mast cell count of 53.79, whereas

the endometritis cases ranged between 14 and 26, with a mean count of 20.25.

The benign lesions showed the highest mean mast cell count of 78.64, followed by the pre-malignant lesions with a mean mast cell count 28.73. The malignant lesions showed the least mean mast cell count of 2.75. (Table 1)

Table 1: Comparison of mast cell count between neoplastic and non-neoplastic lesions

Non-neoplastic Lesions	No of Cases	Range (/10hpf)	Mean	SD	SE
Endometritis	8	14-26	20.25	4.1	1.44
Chronic cervicitis	24	35-72	53.79	11.17	2.28
Chronic polypoidal endocervicitis	20	48-75	61.85	6.84	1.52
Leiomyoma	20	48-154	86.25	24.27	5.43
Cellular leiomyoma	2	38-48	43	7.07	5
Adenomyosis	3	48-58	51.67	5.51	3.18
Atypical hyperplasia	4	15-20	18	2.16	1.08
HSIL	7	24-44	34.86	8.05	3.04
Endometrioid carcinoma	3	1-4	2.67	1.53	0.88
Keratinising SCC-Cervix	9	2-4	3	1	0.58
Non Keratinising SCC-Cervix	1	4	4	—	—
Endocervical Adenocarcinoma, usual type-cervix	1	2	2	—	—
Villoglandular Adenocarcinoma - Cervix	1	2	2	—	—
Poorly differentiated carcinoma - Cervix	1	1	1	—	—

The Chi-square test and One-way ANOVA methods of analysis showed statistically significant difference in the mast cell count between the

benign, pre-malignant and malignant lesions.

Among the malignant lesions studied, poorly differentiated carcinoma showed the least mast cell

count of 1 per 10 high power fields.

Endocervical adenocarcinoma, usual type cervix and villoglandular adenocarcinoma - cervix showed a mean mast cell count of 2. Endometrioid carcinoma and keratinising squamous cell carcinoma - cervix showed mast cell count ranging between 1-4 and 2-4 respectively. While the only studied case of non-keratinising squamous cell carcinoma cervix showed mast cell count of 4 per 10 high power fields.

Among the 9 cases of keratinising squamous cell carcinoma-cervix, the well and moderately differentiated cases showed no significant variation in the mast cell counts.

DISCUSSION

The current study serves as a preliminary step towards profiling mast cell variations in common uterocervical lesions. Mast cells are known to play a vital part in health and disease as they contain a variety of key chemical mediators and substances in their typical metachromatic granules. Because mast cells play multiple roles in angiogenesis, edema formation, and fibrogenesis, it stands to reason that mast cell alterations could be observed in various neoplastic and non-neoplastic disorders.

Out of 104 cases studied the most common age group affected by the uterocervical lesions ranged from 30 to 40 years, with a mean age of 45 years. In our study the youngest patient was 30 years and the oldest was 81 years old. The results were comparable with the studies done by Mainali N *et al*², Jain PC *et al*⁶ and Gousuddin *et al*⁷.

Among the neoplastic lesions, leiomyoma was the most common lesion in the present study with total number of cases being 20 (38.46%). Gousuddin *et al*⁷ and Vedi A *et al*⁸ also showed leiomyoma to be the most common neoplastic lesion.

In the non-neoplastic lesions of uterocervix, chronic cervicitis was most common with the total number of cases being 24 (46.15%), comparable to the study done by Mainali N *et al*². The study done by Gousuddin *et al*⁷ showed equal number of cases of chronic cervicitis and endocervicitis, and Kalyani *et al*⁴ showed polypoidal endocervicitis to be the most common lesion.

While leiomyoma was the most common neoplastic lesion, in the malignant group squamous cell carcinoma cervix was most common. This was comparable with the studies done by Mainali N *et al*², Kalyani *et al*⁴ and Gousuddin *et al*⁷.

In the present study, leiomyoma (42.30%) was the most common neoplastic lesion followed by squamous cell carcinoma - cervix (19.23%). In the study done by Gousuddin *et al*⁷ showed leiomyoma (24.59%) as the most common neoplastic lesion, cervical dysplasia (19.67%) as the second most common lesion followed by squamous cell carcinoma - cervix (16.38%). Mainali N *et al*² and Kalyani *et al*⁴ showed squamous cell carcinoma - cervix (55.56%) and cervical dysplasia (56.41%) respectively, to be the most common neoplastic lesion in their studies. However both the studies were done only on the cervical lesions and hence cases of uterine leiomyoma were not included by them.

The present study showed chronic cervicitis (46.15%) to be the most common non-neoplastic lesion, followed by chronic polypoidal endocervicitis (38.47%), Mainali N *et al*² showed similar results. The study done by Kalyani *et al*⁴ showed polypoidal endocervicitis (51.85%) to be the most common non-neoplastic lesion followed by chronic cervicitis (48.15%). Gousuddin *et al*⁷ showed equal number of cases of the two non-neoplastic lesions.

The mast cell count per 10 high power fields ranged between 48 and 154 in cases of leiomyoma with a mean mast cell count of 86.25. The cellular leiomyoma cases showed lesser mast cell range (38-48), with mean mast cell count of 43. Adenomyosis cases showed 48-58 mast cell range and a mean count of 51.67, which was reasonably high when compared to the studies done by Gousuddin *et al*⁷ and Vedi A *et al*⁸.

The present study showed mean mast count of 18 and the mast cell ranging between 15 and 20 in cases of atypical hyperplasia of the endometrium, which was comparable with the findings of Gousuddin *et al*⁷, with the mast cell range of 11-28 and mean mast cell count of 16.3.

The HSIL cases in present study showed the mast cell count ranging between 24 and 44, with a mean mast cell count of 34.86. Kalyani *et al*⁴ showed similar findings with the mast cell range varying from 20 to 70 and a mean count of 41.66. Whereas Mainali N *et al*² showed lesser mean mast cell when compared to our study.

The mast cell count per 10 high power fields in the case of endometrial carcinoma ranged between 1 and 4, with a mean mast cell count of 2.67. The findings were comparable with the study done by Gousuddin *et al*⁷ which showed a mean mast cell count of 2.8, with the mast cell range of 1-6.

The squamous cell carcinoma cases showed a mean mast cell count of 3.1 and the range of 2-4, which was less when compared to the studies done by Gousuddin *et al*⁷. Vedi A *et al*⁸ and Kalyani *et al*⁴. However, the present study showed no significant variation in the mast cell count between keratinising and non-keratinising types and between the well and moderately differentiated squamous cell carcinomas.

In the present study the cases of endocervical adenocarcinoma, villoglandular adenocarcinoma and poorly differentiated carcinoma cervix, showed the mast cell counts of 2, 2 and 1 respectively. The present study showed decreased mast cell count in cases of endometritis when compared to the chronic cervicitis and chronic polypoidal endocervicitis. Endometritis cases showed a mean mast cell count of 20.25 and the range varying between 14 and 26. Chronic polypoidal endocervicitis cases showed the highest mean mast cell count of 61.85 in the non-neoplastic group, with the count ranging from 48 to 75. Kalyani *et al*⁴ and Mainali N *et al*² showed similar findings in their study group, with the polypoidal endocervicitis cases having the highest mast cell count in the non-neoplastic group, ranging from 21 to 60 and from 40 to 250 respectively, with a mean mast cell count of 39.14 and 114 respectively.

Cases of chronic cervicitis showed a mast cell range of 35-72 and a mean count of 53.79, which were comparable with Kalyani *et al*⁴, Mainali N *et al*² and Gousuddin *et al*⁷ studies.

CONCLUSION

The current study suggests that uterocervical lesions are most common in females aged 30 to 40 years, with leiomyoma being the most common neoplastic lesion, followed by keratinising squamous cell carcinoma cervix. Chronic cervicitis was the most prevalent non-neoplastic lesion,

followed by chronic polypoidal endocervicitis. Leiomyoma had the highest mean mast cell count, followed by chronic polypoidal endocervicitis. There was a statistically significant association between malignant lesions and the other neoplastic and non-neoplastic lesions. However, there was no statistically significant relationship between the mean mast cell count of various malignant tumours. It was noticed in our study that the mast cell count decreased progressively from non-neoplastic and benign to malignant lesions, implying that the mast cell count appeared to be inversely related to the degree of dysplasia and thus the mast cell variation may be an additional diagnostic tool in different uterocervical lesions and may act as a good prognostic indicator of the lesions' benign nature.

REFERENCES

1. Barrett KE, Barman SM, Boitano S, Brooks H. Ganong's Review of Medical Physiology 25th Edition. McGraw-Hill Education; 2015.
2. Mainali N, Sihna A, Upadhyaya P, Upreti D. A study on mast cell variation in neoplastic and non neoplastic disease of uterine cervix. Journal of Pathology of Nepal. 2014 Sep 23;4.
3. Theoharides TC, Conti P. Mast cells: the JEKYLL and HYDE of tumor growth. Trends in Immunology. 2004 May 1;25(5):235-41.
4. R K, G R. Significance of Mast cells in Non-neoplastic and Neoplastic lesions of Uterine Cervix. Biomedical Research and Therapy. 2016 Jan 29; 3(01):469-75.
5. Arbyn M, Castellsagué X, de Sanjosé S, Bruni L, Saraiya M, Bray F, *et al*. Worldwide burden of cervical cancer. Annals of Oncology. 2011 Dec 1;22(12):2675-86.
6. Jain PC, Singh SN, Pratap VK, Lahiri B. Connective tissue changes and mast cell variations in benign and malignant lesions of the uterine cervix. Int Surg. 1977;62(6-7):358-60.ww.

