

An Orphan Disease Begets an Orphan Judgment

Vivekanshu Verma¹, Shri Gopal Kabra²

How to cite this article:

Vivekanshu Verma, Shri Gopal Kabra. An Orphan Disease Begets an Orphan Judgment. Indian Journal of Legal Medicine. 2024;5(1):79-86.

Abstract

An orphan disease is characterized by its rarity, leading to a lack of interest from pharmaceutical industries and medical researchers due to limited financial viability. Consequently, the etiopathology and causative agents of such diseases remain unidentified, and specific drug therapies are unavailable. Treatment relies on the clinical experience and intuition of individual physicians, with no standardized protocol or sufficient patient data for validation. Toxic Epidermal Necrolysis (TEN) is one such orphan disease, with an incidence of 1 to 1.5 per million. It often results from severe hypersensitivity reactions to drugs or infections, causing the immune system to destroy the epidermal layer, leading to multiorgan failure and a high mortality rate. This case highlights the complexities and controversies in managing TEN. Despite numerous specialists' involvement, her treatment led to a legal battle, culminating in a significant compensation award due to alleged medical negligence.

Keywords: Negligence; Malpractice; Court; Hospital; Orphan disease; Adverse Drug Reaction; TEN; SJS; Medico-legal.

INTRODUCTION

*Success has many fathers and failure is an orphan.*¹ An orphan disease is one that is so rare that pharmaceutical industries and medical researchers take no interest in it, as they do not find it a financially viable proposition in it. As a result, the etiopathology of the disease remains unexplored, specific causative agents remain unidentified and no specific drug therapy is made available. That is why the disease is labelled an 'orphan'. The term "orphan" originates from the early 14th century, meaning "a child bereaved of one or both parents,

typically the latter." It derives from the Late Latin word "orphanus," meaning "parentless child," which also influenced Old French and Italian terms. The Latin term traces back to the Greek "orphanos," which means "orphaned, without parents, fatherless," and literally "deprived." This stems from the Proto-Indo-European (PIE) root *orbho-, meaning "bereft of father" or "deprived of free status." This PIE root also led to related terms in various languages, such as Hittite "harb-" (change allegiance), Latin "orbus" (bereft), Sanskrit "arbhah" (weak, child), Armenian "orb" (orphan), and Old Church Slavonic "rabu" (slave). Additionally, it connects to Old English "ierfa" (heir), Old High German "arabeit" (work), and Gothic "arbja" (heir), illustrating a broader historical context of hardship, change, and deprivation.²

Medically, because of non-availability of approved treatment protocol, the disease is treated by different physicians with available medicines as per their clinical experience, intuition and discretion. Besides, the disease being rare, no single physician/expert gets to see more than few patients in his entire career, to acquire sufficient experience.

Author Affiliation: ¹Associate Consultant, Medanta - The Medicity, Gurugram 122001, Haryana, ²Director Legal Affairs and Medical Audit, Santokba Durlabhji Memorial Hospital, Jaipur 302015, Rajasthan, India.

Corresponding Author: Shri Gopal Kabra, Director Legal Affairs and Medical Audit, Santokba Durlabhji Memorial Hospital, Jaipur 302015, Rajasthan, India.

E-mail: kabrasg@hotmail.com

Received on: 09.07.2024 **Accepted on:** 17.08.2024



Even at institutional level there is not statistically significant number of patients to scientifically validate the treatment schedule followed.³ Thus, there is plethora of treatment schedules with contradictory claims.⁴

Toxic Epidermal Necrolysis (TEN) is an orphan disease

Toxic Epidermal Necrolysis (TEN) is one such a rare disease with an incidence of 1 to 1.5 per million population, thus it may be considered as an orphan disease, internationally.^{5,6,7} But, although rare, it is still a very serious condition, that courses to fatal outcome in about 30-50% of cases, inspite of best of care.⁸ It is said to be a result of severe hypersensitive reaction to some drug or an infection or combination of the two.⁹ The triggered toxicity is an immune mediated response that selectively identifies the epidermal layer of the skin and mucous membrane to be non-self and destroys it by necrolysis.¹⁰ The necrolysed cells in turn release toxins that effect body systems and cause death by multiorgan failure. Add to it the resistant

hospital strains of microorganisms that colonise the epidermis-denuded body surface areas. The oozing serum provides nutrient rich medium for the microorganisms to thrive. Fortunately, the intact active dermis does not allow entry of the bacteria in the blood stream (unlike deep burns where entire skin is shed).¹¹ However, the toxins secreted by them may seep in to damage the vital organs. Any intrusive procedure such as IV canulation and fluid infusion or nasogastric intubation, is attended with great risk of introduction of the surface bacteria inside the body. It must be understood though that all the above are probabilities, their actual occurrence uncertain and widely variable.

A CASE REPORT

Consider in this light the TEN case, treated at a reputed Hospital in Kolkata and later at another Hospital, based in Mumbai. Being an orphan disease, the patient (a clinical psychologist with her husband, himself an allopathic doctor) consulted 19 specialists - physicians, dermatologists, plastic

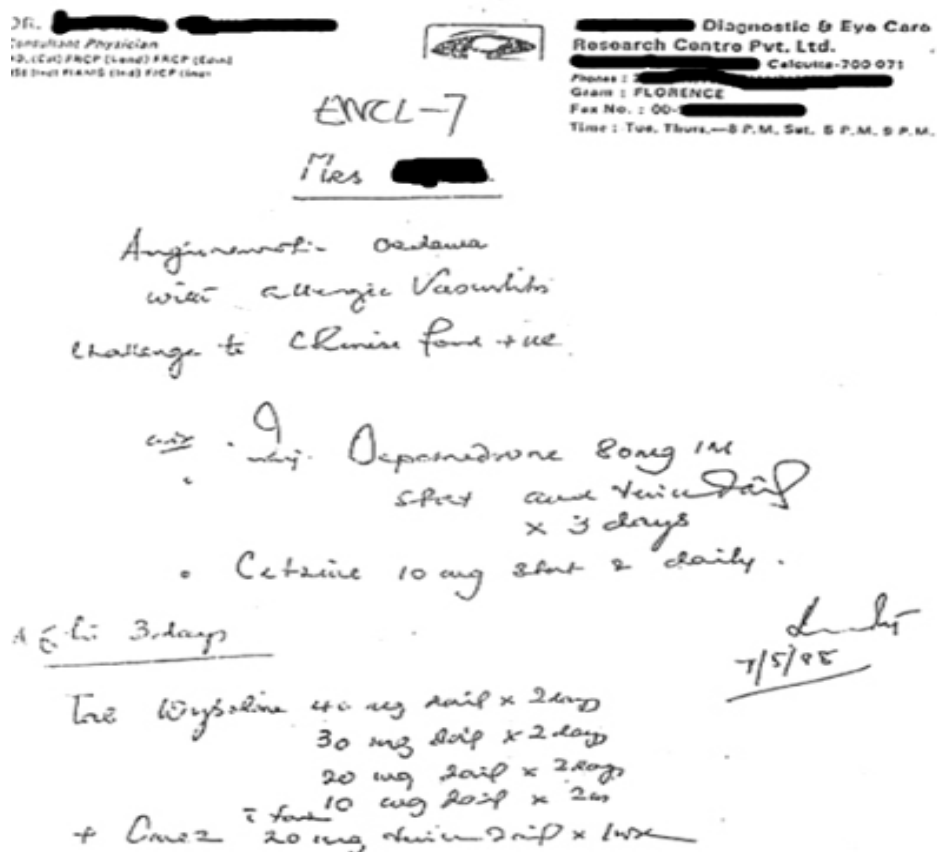


Fig. 1: Patient's Prescription for Angioneurotic oedema, for managing allergy to Chinese food

surgeon, ENT specialist, Ophthalmologists - of Kolkata, and 9 doctors of Mumbai Hospital. Her husband himself was the primary physician of this patient, claiming himself to be trained physician and PhD researcher bacteriologist. All the senior doctors both at Kolkata Hospital and Mumbai Hospital, came as professional colleagues to treat his wife in good faith, not charging any fee from him in conformity with professional ethics.

It seems that, what triggered the Adverse Drug Reaction (ADR) was the initial medical treatment, given by Patient's Attendant Husband (as an Allopathic Doctor himself) to his ailing wife, the patient, for a throat infection, with neck lymph nodes enlargement and fever. Though not specifically disclosed by Patient's Husband, being a trained physician, he must have administered Analgesic, Antipyretic and Antibiotic.^{12,13}

Unfortunately, there was a severe abnormal reaction to it that relentlessly progressed from some skin rashes, to **angioneurotic oedema**, to

macula-papular eruptions, to blisters on skin and mucous membrane in large part of the body which was diagnosed by a dermatologist to be Stevenson Johnson Syndrome (SJS); which with further progress, when there was necrolysis and reepithelization of 30% of body surface, that another dermatologist labelled the disease to be Toxic Epidermal Necrolysis (TEN).¹⁴

TEN was thus an end stage diagnosis. However, what caused it was the inadvertent drug treatment given by Patient's Husband to his wife, the Patient. The drug treatment, in retrospect, proved to be harmful and negligent, as she had allergic diathesis - she was allergic to Chinese food.

When her condition deteriorated, Patient was admitted to Kolkata Hospital under a classmate of patient's husband. Patient's Husband was constantly present by the side of his wife, and being her primary physician supervised and maintained a tight control over her nursing and medical treatment.

CONSULTATION RECORD

Name: [redacted] Age: [redacted] Sex: [redacted] Mar. Status: [redacted] Hospital No. [redacted]
 Service: [redacted] Ward: [redacted] M.R.D. Occupation: [redacted]
 Related by Dr. [redacted] (Requesting Doctor) to Dr. [redacted] (Consultant & Specialist)

Nature of Investigation: (CT Process) Date: [redacted]

May I request Dr. [redacted] to examine this patient & adv. [redacted]

Observations: Toxic Epidermal Necrolysis (TEN) (SJS)
 [redacted] + blisters + Ery. WBC + Leuko WBC.
 [redacted] (intractable long duration) + [redacted]
 Analgesic: Mefenamic acid 500mg 2-3 times a day
 Antibiotic: [redacted]
 Chlorpheniramine 4mg 2-3 times a day
 Paracetamol 500mg 2-3 times a day
 [redacted] 200mg / 15ml once
 [redacted] 200mg 2-3 times a day
 [redacted] 4ml 2-3 times a day

Remarks / Clinical Inspection:

Fig. 2: Patient's IPD Case Referral for Toxic Epidermal Necrolysis

It is he who invited 19 specialists to come and examine his wife and decided whose prescribed treatment was to be followed. He was responsible for their acts. However, when his wife died, he

betrayed good faith and alleged that all of them acted negligently and that his wife died due to 'cumulative' negligence of all the consultants.




Fig. 3: Negligently filled Monitoring Chart of the TEN patient by the bedside nurses during inpatient care in IPD

When it was pointed out that he was involved and was responsible for all the treatment received by the patient, the Hon'ble Apex Court decreed it to be a 'contributory negligence' and allowed 10% rebate from the 11 crore compensation awarded.¹⁵

CASE DISCUSSION

Medical negligence is defined as the failure to provide reasonable care and skill, thereby

endangering the health or life of a patient.¹⁶ This can occur when healthcare providers do not meet the accepted standards of practice, leading to harm or worsening of the patient's condition. Negligence encompasses a wide range of errors, including misdiagnosis, incorrect treatment, surgical mistakes, or inadequate follow-up care.¹⁷ The key aspect of medical negligence is the deviation from the expected level of competence, which directly impacts patient safety.¹⁸ It underscores the critical

need for healthcare professionals to maintain high standards to prevent harm and ensure patient well-being.

Complaints

The **chief allegation** was use of steroids in high dose. And that steroid, according to some expert opinion, are not to be used for treatment of TEN (Toxic Epidermal Necrolysis). That steroid being immunosuppressant enhance the chances of infection in an already vulnerable patient.

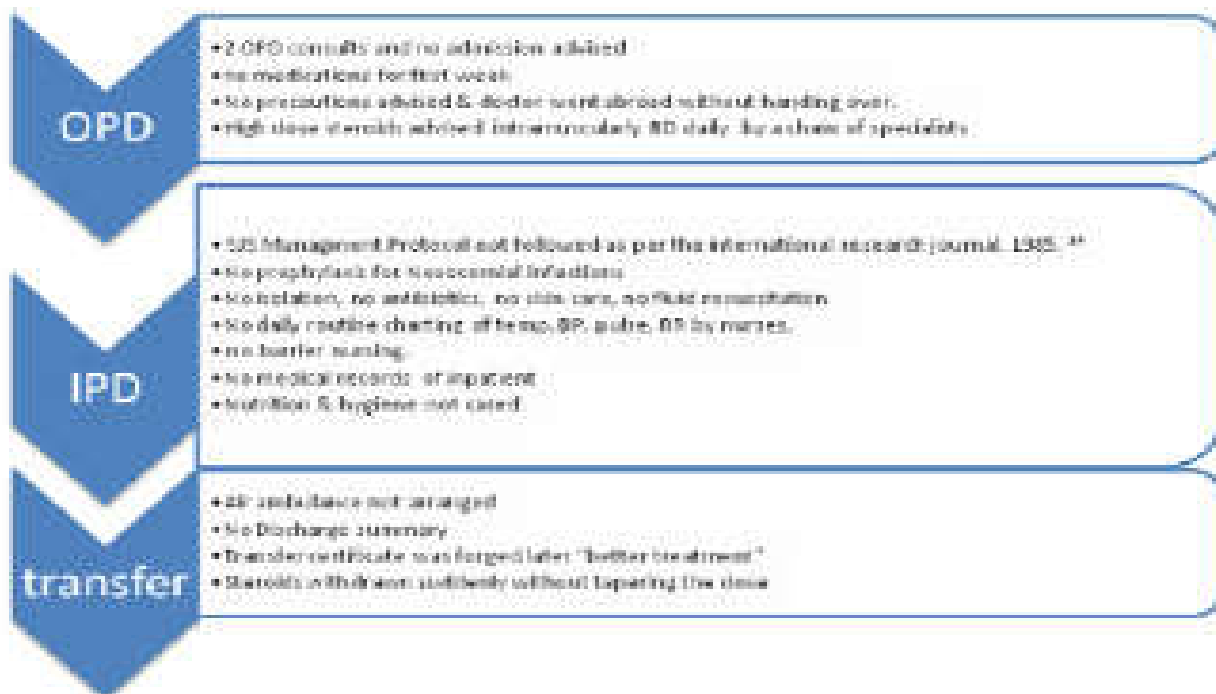
Patient's husband placed before the Apex Court expert opinions that he had procured to support his allegations. Though equal number of expert opinions were submitted by the respondent specialists to counter it, the Hon'ble Court disregarded the later as being retrospective justification to cover up their negligent acts.

Despite the controversy, corticosteroids remain a part of the therapeutic arsenal for Steven Johnson's Syndrome (SJS) and TEN, especially in severe cases. Their use is often tailored to the individual patient's condition and response to treatment. The steroids are prescribed not per se to treat SJS or TEN but to retard the deadly effect of toxins on cells.

Toxins cause death of cells by rupturing the membranes of intracellular lysosomes. Ruptured lysosomes liberate their acidic enzymes that digests the cell itself - necrolysis. (Lysosomes are called the suicidal bags of the cell). Steroids by stabilizing the lysosome membrane tend to protect the cell. This is universally true for all inflammations that cause cell death.

Steroids are frequently prescribed to provide immediate relief from inflammatory painful conditions. Imagine a patient with agonizingly painful blisters and raw skin all over her body and the relief she must have got from receiving steroids. There was very little choice giving her the usual painkillers. It was like a status asthmaticus patient in suffocating agony responding to steroid therapy.

The Alleged Medical Negligence during patient care was enumerated by the patient's lawyer at different times not only in the OPD (Out Patient Department) consultation, but also in IPD (In Patient Department) care, as well as during the Patient transfer from one hospital to another, chronologically described by the prosecution, summarised in the flowchart below:



As stated earlier, TEN is a life-threatening orphan disease about which very little is known. A physician when called in to tackle the crisis in such a disease, has nothing to fall back upon except his clinical judgment. He honestly prescribes, in good faith, a treatment that he believes, in his clinical judgment, would help

tide over the crisis. His real time bed-side clinical judgment and decision cannot be substituted by a virtual decision in retrospect, by any expert, least so by a judicial officer. There is nothing to doubt good faith of, bed side, real time decision of the treating physician. He certainly cannot be faulted.

Cause of death

Besides, the legal principle of probability²⁰ and proximity²¹ to ascertain cause and effect, cannot be applied in the absence of medical evidence that the probability had manifestly actualized. In the instant case, the steroid treatment is alleged to have lowered the patient's immunity that caused infection. The steroids affect *cellular immunity* by causing disappearance of white blood cells (WBCs) from blood.²² This did not actualize in the present patient who had well documented leucocytosis till her end. Also, there was firm evidence that there was no dreaded infection of lungs, kidneys or other vital organs. There was also no wide spread infection of the skin. As documented by the Mumbai Hospital, a small patch of *Pseudomonas Pyocyanus* was healing, and the denuded epithelium was rejuvenating. The cause of death was endogenous toxins of TEN and toxins liberated from necrolysed epithelium that caused multiorgan failure.

Other allegations

There was an allegation of very poor nursing care evidenced by not noting of vital parameters in the patient record on certain dates. The Apex Court passed nasty strictures, little realising that on those days both arms, arm pits, mouth and perineum were full of blisters and raw areas of desquamating skin epithelium. How could one wrap the sphygmomanometer cuff around the arm or put a thermometer in blister filled arm pit or mouth, that also every four to six hours. Not surprisingly her physician husband, in constant attendance, prohibited it. However, he later manipulated this fact to malign the hospital.

The same was true for the intravenous infusion. Putting an indwelling intravenous cannula and giving infusions through it was hazardous because of the possibility of introducing dreaded infection in the blood stream from the body surface. The patient was taking enough fluids, liquid and semisolid feeds by mouth and was well hydrated and nutrition was well maintained, as documented by treating consultants. The riskier option of putting a nasogastric tube to feed the patient was unnecessary and inadvisable. Patient's husband was active partner to all these decisions. Being an Infection Specialist (HIV AIDS researcher at Ohio State University) he tightly controlled all such risky activities.

Apex Court Decision

Yet, Patient's husband managed to get a judgment from the Apex Court awarding him, a

foreign resident of Indian origin, a compensation of 11 crores for cumulative negligence of 26 top doctors of the country that caused death of his wife (the deceased patient) by the deadly orphan disease of Toxic Epidermal Necrolysis (TEN).

In this case, multiple specialists were consulted, but her condition deteriorated, leading to her death. Her Husband accused the specialists of negligence, leading to a landmark legal battle. The Supreme Court awarded patient's life partner, substantial compensation, citing cumulative negligence despite conflicting expert opinions on steroid use in TEN treatment. This judgment highlighted the complexities and controversies in managing orphan diseases and the challenges faced by the medical profession in treating such rare and life-threatening conditions. A decision that orphaned the medical profession of the country.

As written by William Gaddis in his Novel's Opening line, Novel titled: *A Frolic of his Own* (1994),²³ Opening Line: "Justice? You get justice in the next world; in this world you have the law." The title *A Frolic of his Own* is from a judicial decision about vicarious liability in *Joel v. Morison*.²⁴ If the driver was deviating from his master's implied commands while conducting his master's business, the master would be liable for his actions. However, if the driver was on a personal errand, unrelated to his master's business, the master would not be liable. The doctrine of respondent superior holds that a principal is liable for an agent's negligence only when the agent is acting within the "course of his employment" at the time of the accident. Although the agent was conducting the employer's business, he momentarily deviated from his master's implied command.

Recent Updates in Criminal Law on Death due to Medical Negligence

The Bharatiya Nyaya Sanhita (BNS) 2023,²⁵ prescribes a lesser punishment for doctors causing death by negligence compared to other offenders. However, under the BNS, imprisonment is mandatory if found guilty. Section 106 of the BNS, corresponding to Section 304A of the Indian Penal Code (IPC), deals with 'causing death by negligence' and imposes a punishment of up to five years of either simple or rigorous imprisonment along with a fine. Specifically, Section 106 of the BNS states that if a registered medical practitioner causes death by negligence while performing a medical procedure, the punishment shall be two years of imprisonment with a fine. The law clarifies that a "registered medical practitioner" refers

to an individual holding a medical qualification recognized under the National Medical Commission Act 2019,²⁶ with their name listed in the National Medical Register or a State Medical Register under that Act. This distinction in punishment reflects the unique position and responsibilities of medical professionals in the context of legal accountability.

CONCLUSION

An orphan disease, such as Toxic Epidermal Necrolysis (TEN), is rare and lacks interest from pharmaceutical companies and researchers due to limited financial incentives. This results in unexplored etiopathology, unidentified causative agents, and no specific drug therapies. Physicians rely on their clinical experience and discretion for treatment, leading to varied and unvalidated treatment protocols. TEN, is a severe condition resulting from hypersensitive reactions to drugs or infections, causing immune-mediated destruction of the epidermis and mucous membranes, often leading to multiorgan failure and a high mortality rate. This judgment highlighted the lack of standardized protocols and the complexities in treating rare diseases, ultimately questioning the liability in medical practice. The case reveals the systemic issues in managing orphan diseases and the need for clear guidelines to protect both patients and healthcare providers.

Conflict of Interest: *Nil*

Declaration of generative AI and AI-assisted technologies in the writing process:

During the preparation of this work the author utilized the 'Chat GPT' in order to improve the language and readability. After using this tool/service, the author reviewed and edited the content as needed and take full responsibility for the content of the publication.

REFERENCES

- Nix, Alexander. Alexander Nix - Success has many fathers and failure is an... (brainyquote.com) Link Last accessed on 9th July 2024. https://www.brainyquote.com/quotes/alexander_nix_1038761
- orphan | Search Online Etymology Dictionary (etymonline.com) Link Last accessed on 9th July 2024. <https://www.etymonline.com/search?q=orphan>
- Creamer D, Walsh SA, Dziewulski P, et al. UK guidelines for the management of Stevens-Johnson syndrome/toxic epidermal necrolysis in adults 2016. *British Journal of Dermatology*; 174(6):1194–1227.
- Dodiuk-Gad RP, Chung WH, Valeyrie-Allanore L, Shear NH. Stevens-Johnson Syndrome and Toxic Epidermal Necrolysis: An Update. *Am J Clin Dermatol*. 2015;16(6):475-493.
- Roujeau JC, Guillaume JC, Fabre JP, Penso D, Flechet ML, Girre JP. Toxic epidermal necrolysis (Lyell syndrome). Incidence and drug etiology in France, 1981–1985. *Arch Dermatol* 1990;126:37–42.
- Chan HL, Stern RS, Arndt KA, Arndt KA, Langlois J, Jick SS, et al. The incidence of erythema multiforme, Stevens-Johnson syndrome, and toxic epidermal necrolysis. A population-based study with particular reference to reactions caused by drugs among outpatients. *Arch Dermatol* 1990;126:43–7.
- Yang MS, Lee JY, Kim J, Kim GW, Kim BK, Kim JY, Park HW, Cho SH, Min KU, Kang HR. Incidence of Stevens-Johnson Syndrome and Toxic Epidermal Necrolysis: A Nationwide Population-Based Study Using National Health Insurance Database in Korea. *PLoS One*. 2016 Nov 11;11(11):e0165933.
- Chan HL, Stern RS, Arndt KA, Arndt KA, Langlois J, Jick SS, et al. The incidence of erythema multiforme, Stevens-Johnson syndrome, and toxic epidermal necrolysis. A population-based study with particular reference to reactions caused by drugs among outpatients. *Arch Dermatol* 1990;126:43–7.
- Bastuji-Garin S, Rzany B, Stern RS, Shear NH, Naldi L, Roujeau JC. Clinical classification of cases of toxic epidermal necrolysis, Stevens-Johnson syndrome, and erythema multiforme. *Arch Dermatol*. 1993 Jan;129(1):92-6.
- Abe R. Immunological response in Stevens-Johnson syndrome and toxic epidermal necrolysis. *J Dermatol*. 2015;42(1):42-48.
- LYELL A. Toxic epidermal necrolysis: an eruption resembling scalding of the skin. *Br J Dermatol*. 1956 Nov;68(11):355-61
- Pejčić AV. Stevens-Johnson syndrome and toxic epidermal necrolysis associated with the use of macrolide antibiotics: a review of published cases. *Int J Dermatol*. 2021 Jan;60(1):12-24.
- Moshfeghi M, Mandler HD. Ciprofloxacin-induced toxic epidermal necrolysis. *Ann Pharmacother*. 1993 Dec;27(12):1467-9.
- Mockenhaupt M, Viboud C, Dunant A, Naldi L, Halevy S, Bouwes Bavinck JN, Sidoroff A, Schneek J, Roujeau JC, Flahault A. Stevens-Johnson syndrome and toxic epidermal necrolysis: assessment of medication risks with emphasis on recently marketed drugs. The EuroSCAR-study. *J Invest Dermatol*. 2008 Jan;128(1):35-44.
- Kunal Saha (Dr.) V Sukumar Mukherjee (Dr.) 2006 (2) CPR 14:2006 (3) CPJ 142 (NCDRC).

16. Koley, Tapas K. *Medical Negligence and the Law in India: Duties, Responsibilities and rights*. Oxford University Press. 2010. *Defining Professional Negligence*, p24-26.
17. Kannan, K. *Modi's Medical Jurisprudence & Toxicology*. 27th Ed. LexisNexis. 2022.
18. Kabra, SG. *Perverse Medical Negligence Judgments are the Bane of Medical Profession*. Antara Infomedia Publications. 2023.
19. Ting H.C., Adam, B.A., *Stevens-Johnson Syndrome: A Review of 34 Cases*. *International Journal of Dermatology*. Volume 24, Issue1, January 1985, Pages 587-591.
20. Allen, Ronald J. and Alex Stein, 2013, "Evidence, Probability and the Burden of Proof", *Arizona Law Journal*, 55(3): 557-602.
21. Koffa, K. (1935): *Principles of Gestalt Psychology*. London, Routledge & Kegan Paul Ltd. *Law Of Proximity (Gestalt Principle)*.
22. Tran TH, Lan PT, Khang TH, Luong VH. *Systemic Corticosteroid Therapy for Stevens-Johnson Syndrome and Toxic Epidermal Necrolysis in Vietnam: Clinical Evaluation and Analysis of Serum Cytokines*. *Open Access Maced J Med Sci*. 2022 Jan 16; 10(B):303-308.
23. Gaddis, William. *A Frolic of His Own*. Poseidon Press, 1994.
24. *Joel v Morison* [1834] EWHC KB J39.
25. Section 106, *Bharatiya Nyaya Sanhita (BNS)* 2023.
26. *National Medical Commission (NMC) Act*, 2019.

