

Management of Communitated Cervical Root Fracture using Biodentine : A Case Report

H C Baranwal¹, Amrita Kumari², Neeraj Kumar³

Author's Affiliation: ¹Professor, ²Junior Resident, ³Post Graduate, Unit of Conservative Dentistry and Endodontics, Institute of Medical Sciences, Banaras Hindu University.

Corresponding Author: Amrita Kumari, Junior Resident, Unit of Conservative Dentistry and Endodontics, Institute of Medical Sciences, Banaras Hindu University.

E-mail: amritakmr0@gmail.com

How to cite this article:

H C Baranwal, Amrita Kumari, Neeraj Kumar, Management of Communitated Cervica Root Fracture using Biodentine: A Case Report. Indian J Dent Educ. 2020;13(2):79–82.

Abstract

Root fracture is one of the detrimental fracture which results after impingement of high force upon the root. This has detrimental consequences for the tooth and its supporting structure. Horizontal root fractures are the most common type and occur mainly in the maxillary incisors. Prognosis of coronal third root fracture is less favourable because of the difficulty in immobilizing the tooth. For a successful outcome, an appropriate diagnosis of a fractured tooth in its most primitive possible stage encourages more conservative management options as well as an improved prognosis. This case report illustrates a novel treatment option for management of communitated horizontal cervical root fracture in left maxillary central incisor. In contemporary modern era, the introduction and readiness of biocompatible materials like biodentine and proper understanding of the biological concepts of root fractures help in better prognosis of root fracture. Biodentine appears to be an improvement over other materials for some endodontic procedures that involve root repair and bone healing.

Keywords: Cervical root fracture; Biodentine; fiber post

Introduction

Root fracture results after impingement of high force upon the root, has detrimental consequences for the cementum, dentin, pulp and periodontium. Traumatic injuries of Crown-root fractures comprise 5% of injuries affecting the permanent dentition while, overall incidence of Horizontal root fracture (HRF) is low and has been stated to be 0.5%–7% when compared with other forms of dental impact injuries.^{1,2} Central and lateral maxillary incisors encounter HRFs 68% and 27%; in contrast, only 5% of root fractures are found in mandibular incisors.³ At least three angulated radiographs (periapical, occlusal and eccentric

exposures) have been recommended to diagnose a fracture, although it yields only limited information for accurate diagnosis. Cone-beam computed tomography (CBCT) provides an assisting imaging modality to supplement conventional radiography for evaluating root fractures.⁴

Prognosis of cervical root fracture (CRF) is considered to be poor due to a short mobile coronal fragment, less probability of healing with hard tissue, and possible bacterial contamination of necrotic pulp tissue from the gingival crevice. For effective outcome, an appropriate diagnosis of a fractured tooth in its most primitive possible stage encourages more conservative management options as well as an improved prognosis. Biodentine new



This work is licensed under a Creative Commons Attribution-NonCommercial-ShareAlike 4.0.

bioactive calcium silicate-based cement introduced as 'dentin substitute'. This new biologically active material aids its penetration through opened dentinal tubules to crystallize interlocking with dentin and provide mechanical properties, good handling properties, and short setting time.⁶

Case report

A 23 years old female patient presented with slight pain, mobility and discolouration of upper front teeth. She gave history of trauma and then dental treatment by some local private practitioner 4 months back. She advised extraction of that tooth because of no resolution in condition, however patient was not willing for extraction and thus reported to our department of conservative dentistry and endodontics, BHU, Varanasi for further consultation. Clinical examination revealed mobility of upper left central incisor buccolingually. There was no tender on percussion. There was composite material seen in mesial and distal surface of #21 with adjacent tooth as a splint. On Radiographic examination, IOPA showed Obturated #21 (FDI) with communitated cervical root fracture. CBCT examination confirmed the

presence of multiple small fractures at the cervical third of the root and extent of the fracture line.

Considering all these conditions, sealing the fracture lines with biodentine and reattachment of the mobile fragment with fiber post was planned. Post space was prepared after stabilizing the crown with thumb and index finger, leaving apical 5 mm of GP. Canal was checked for fiber post fit and size #3 fiberpost was selected for reattachment procedure. BIODENTINE capsule was mixed in amalgamator for 30 sec at a speed of 4000-4200 rpm. Freshly mixed biodentine was introduced in canal to seal the fracture lines and cover dentine layer.

After preparing post space, biodentine is allowed to flow within the fracture site in the circumference of canal and then fiber post is placed in position. After proper itching and bonding procedure, the tooth was coronally sealed with dual cure resin cement. Once the tooth was reattached, patient was kept for follow up to evaluate any signs of further discoloration or mobility. Once the patient was aymptomatic the tooth was prepared for crown coverage. Six months follow up shows no mobility and pain.

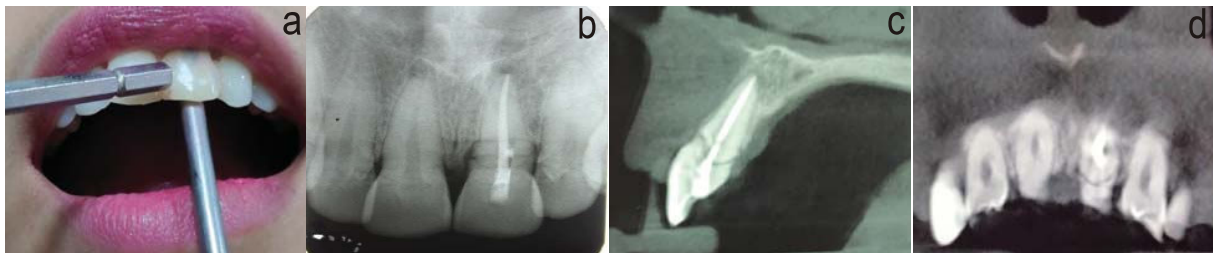


Fig. 1: (a) Pre-operative photograph checking mobility, (b) Pre-operative IOPA, (c) CBCT showing sagittal view, (d) CBCT showing axial view.

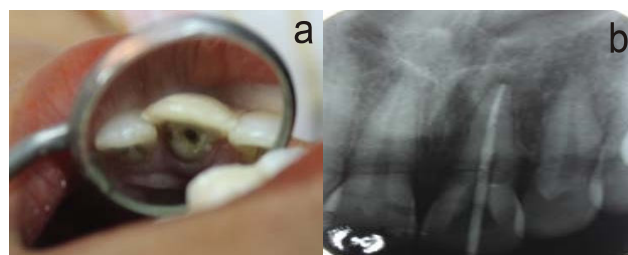


Fig. 2: (a) Biodentine in post space, (b) Fiber post in place

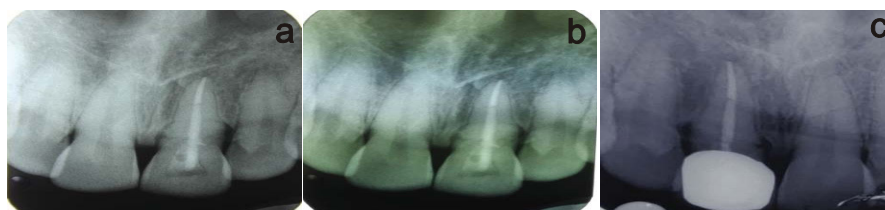

Fig. 3: (a) Post-operative IOPA, (b) Follow-up IOPA after 3 months, (c) Follow-up IOPA after crown placement

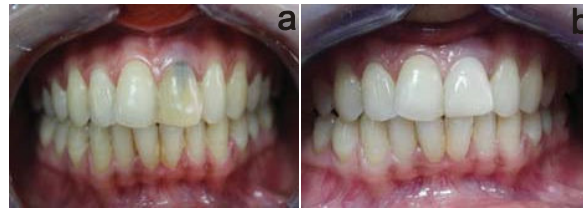

Fig. 4:(a) Pre-operative photograph, (b) Post-operative photographafter crown cementation.

Discussion

Management of horizontal cervical root fracture is complex and challenging to an endodontist due to association of pulpal and periodontal components. The ultimate goal to preserve the natural dentition encourages the possibilities of new horizons to manage these critical situations. There are factors like age of the patient, stage of root growth, mobility of the coronal fragment, dislocation of the coronal fragment, and fragment diastasis that put forth great influence on healing at the fracture line.¹ Fiber post was planned to retain crown and to redistribute stresses down onto the root, thereby reducing the risk of coronal fracture.⁵

A novel approach of using biodentine as a splint material over the fracture fragments was utilised as of being Osseoinductive lead to formation of hard tissue around fracture, alkaline that contribute to its antibacterial effect which forms a sterile environment around the fracture site and biocompatibility so even minor leakage helps in the healing of periodontal apparatus by forming normal architecture and hard set stabilization which would contribute to it acting as an intraradicular splint.⁷

It is still unclear whether a chemical union exists between Biodentine and the overlying resin composite restoration. However some previous research found that the functional monomer 10-MDP, present in the adhesive bind to calcium in tooth structure (Yoshida Y et al. J Dent Res 2004). Theoretically, it could be assumed that the 10-MDP monomer may bind chemically to the calcium in Biodentine, hence promoting chemical adhesion in addition to micromechanical attachment.⁸

Micromechanical adhesion of biodentine enabled excellent adaptability of Biodentine crystals to the underlying dentin thus is considered to have better sealing properties.⁹

Koubi G et al conducted a randomized 3 years prospective study and concluded that Biodentine can be used as a dentine substitute under composite.¹⁰

According to several in-vitro and in-vivo studies, there are some components of restorative composite resins, adhesives, and resin-modified glass

ionomer cements that are toxic. The mechanisms of cytotoxicity are related to short-term release of free monomers occurring during the monomer-polymer conversion, and long-term release of leachable substances is generated by erosion and degradation over time.

Conclusion

Cervical root fractures have long been well-thought-out to have a poor prognosis. In recent years, introduction and availability of biocompatible materials like biodentine and proper understanding of the biological concepts of fracture helps in better prognosis of horizontal root fracture.

References

1. Andreasen JO, Andreasen FM, Andersson L, eds. Textbook and Color Atlas of Traumatic Injuries to the Teeth. Copenhagen, Denmark: Munksgaard; 2007:337-71.
2. Orhan K, Aksoy U, Kalender A. Cone-beam computed tomographic evaluation of spontaneously healed root fracture. J Endod 2010;36:1584-7.
3. Wolner-Hanssen AB, von Arx T. Permanent teeth with horizontal root fractures after dental trauma: a retrospective study. Schweiz Monatsschr Zahnmed 2010; 120: 200-12.
4. Bornstein MM, Wolner-Hanssen AB, Sendi P, von Arx T. Comparison of intraoral radiography and limited cone beam computed tomography for the assessment of root-fractured permanent teeth. Dent Traumatol 2009; 25:571-7.
5. Cheung, William (May 2005). "A review of the management of endodontically treated teeth". The journal of American dental association. 136 (5): 611- 619.
6. Septodont Biodentine™ Active Biosilicate Technology™ Scientific file 2010.
7. Laurent P, Camps J, About I (2012) Biodentine(TM) induces TGF-β1 release from human pulp cells and early dental pulp mineralization. IntEndod J 45: 439-448.

8. Yoshida Y, Nagakane K, Fukuda R et. al. Comparative study on adhesive performance of functional monomers. J Dent Res. 2004 Jun;83(6):454-8.
9. MandeepKaur, Harpreet Singh et al MTA versus Biodentine: Review of Literature with a Comparative Analysis J ClinDiagn Res. 2017 Aug; 11(8): ZG01-ZG05.
10. Kaubi G, Colon P, Franquin JC. Clinical evaluation of the performance and safety of a new dentine substitute, biodentine, in the restoration of posterior teeth-a prospective study. Clin Oral Investig. 2013;17(1):243-49

