

## A Case Report of Superior Vena Cava Syndrome Diagnosed in Emergency Department

Gokul B.<sup>1</sup>, Shakti Shishodia<sup>2</sup>, Pallavi Sehgal<sup>3</sup>, Dheeraj B. Nair<sup>4</sup>

### How to cite this article:

Gokul B., Shakti Shishodia, Pallavi Sehgal, *et al.* A Case Report of Superior Vena Cava Syndrome Diagnosed in Emergency Department. *Ind J Emerg Med.* 2024;10(2):79-81.

### Abstract

A 66 year old Male Presented to Er with complaints of Facial Swelling since 15 days, Cough non productive with no diurnal Variation since 1 Month, Breathing difficulty since 1 Month with no aggravating or relieving factors. There was a History of change in Voice for past 3 months for which the patient didn't neither took any treatment nor Evaluation.

There was no History of fever, chest pain, Palpitations, Syncope, Trauma, Decreased Urine Output, Frothy Urine, Insect Bite or any history of similar complaints in the past.

Patient was then Evaluated for lower respiratory tract infections, Heart failure, Angioedema, Nephrotic Syndrome.

After all the investigations Patient was diagnosed as superior vena cava syndrome caused due to the Mediastinal Mass and Managed conservatively for superior vena cava Syndrome and referred to Oncology Department for further care and Management.

**Keywords:** A Case report of Superior; Vena Cava Syndrome Due to Mediastinal; Mass Diagnosed in Emergency Department.

## INTRODUCTION

Superior Vena cava Syndrome (SVC) is a Collection of Clinical signs and Symptoms resulting from Either Partial or complete obstruction

of Blood flow through the SVC. This obstruction is Most commonly a result of thrombus formation or Tumour Infiltration of the vessel wall. The Superior Vena cava is formed by the Junction of the Left and Right Innominate (Brachiocephalic) Veins and is Tasked with returning Blood from the head, Neck, Upper extremities and Torso back to the Heart. Today, this Syndrome is most commonly seen secondary to Malignancy, although there has been a more recwnt rise in Benign Etiologies. The resulting venous congestion produces a Clinical Scenario relating to increased upper body Venous Pressures. Tge most common Signs and Symptoms include face or Neck swelling, Upper extremity Swelling, Dyspnoea, Cough and dilated Chest Vein Collaterals.<sup>1,2,3</sup>

**Author's Affiliation:** <sup>1</sup>DNB Resident, <sup>2</sup>Attending Consultant, <sup>3</sup>Associate Consultant, <sup>4</sup>Head of the Department, Department of Emergency Medicine, Max Superspeciality Hospital, Vaishali, Ghaziabad 201010, Uttar Pradesh, India.

**Corresponding Author:** Shakti Shishodia, Attending Consultant, Department of Emergency Medicine, Max Superspeciality Hospital, Vaishali, Ghaziabad 201010, Uttar Pradesh, India.

E-mail: [shaktishishodia61@gmail.com](mailto:shaktishishodia61@gmail.com)

Received on: 09-02-2024 Accepted on: 21-05-2024



SVC Syndrome saw a Dramatic decrease throughout the Twentieth Century. Today, the majority of SVC Syndromes are result of mediastinal malignancies, Primary among which are small cell bronchogenic small cell carcinoma. The second most commonly associated malignancy is Non-hodgkins lymphoma followed by metastatic tumors. In addition, Benign or non malignant causes of SVC Syndrome now compromise atleast 40% of cases. Iatrogenic thrombus formation or SVC Stenosis is a growing etiology due to pacemaker wires and semipermanent intravascular Catheters used for hemodialysis, long term antibiotics or Chemotherapy.<sup>4,5</sup>

## CASE REPORT

### Patient Information:

A 66 year old Male living in Urban area of Delhi, NCR region.

### Clinical Finding and Diagnostic Assessment:

A 66 year old Male Presented to Er with Complaints of Facial Swelling since 15 days, Cough-non productive with no diurnal variation since 1 Month, breathing difficulty since 1 Month with no aggravating or relieving factors. There was a history of change in voice for past 3 Months for which the patient didn't neither took any Treatment Nor Evaluation.

There was no history of fever, Chest Pain, Palpitations, Syncope, Trauma, Decreased Urine output, Frothy Urine, Insect Bite or any History of Similar Complaints in the Past.

He was Non Alcoholic and Non Smoker

### Patient Vitals:

Bp-110/80MmHg, Pr-85/Min-Regular, Spo2-98% on room air, RR-20/Min.

General Examination was Uneventful.

### Systemic Examination:

CVS, Cns and Abdomen-within normal limits.

Respiratory System-Bilateral air Entry Plus. Air Entry Reduced on the Right>Left, No added sounds.

No Thyromegaly Present

Examination of Throat with torch light was within normal limits.

Baseline investigations Such as CBC, Lft, Kft, Urine Routine and Microscopy Sent.

Abg, Chest Xray, Nt pro BNP, Echo and Ct Chest was done.

All the reports were within normal limits except chest X-ray showed a Right Paratracheal opacity and Ct Chest revealed a large irregular Heterogenously Enhancing soft tissue density Suggestive of Mediastinal Mass Encassing the superior vena Cava and also the right bronchi.

The Images of Chest Xray and CT are given Below.

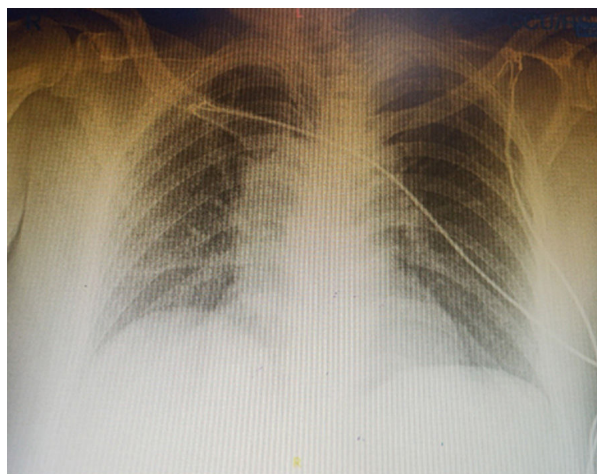


Fig. 1: Chest Xray showing a Right Paratracheal Opacity

CT Chest revealing a large irregular Heterogenously Enhancing soft Tissue density.

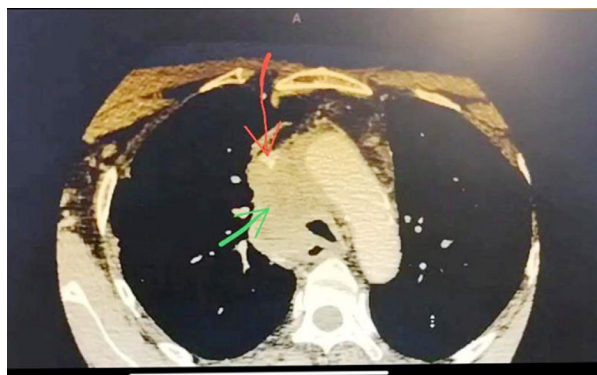


Fig. 2: Suggestive of Mediastinal Mass encassing the Superior Vena Cava and also the Right Bronchi.

### Therapeutic Intervention:

Patient was Haemodynamically Stable and Treated Conservatively by Head End Elevation, IV steroids, IV Diuretics and anticoagulants and Nebulisations.

Patient was then planned for Petct and referred to Tumour board for multidisciplinary approach and Mangement by multidisciplinary team of Pulmonology, Oncology, Cardiology and vascular Surgeon.

## DISCUSSION

Ronny Cohen, Derrick Mena, Roger Carbajal-Mendoza, Ninon Matos, Nishu Karki International Journal of Angiology 17 (01), 43-46, 2008.<sup>6</sup>

Mohamed Elamin Salama, Patrick Ukwade, Abdur Rafeh Khan, Hasan Qayyum, Patrick T Ukwade Cureus 14 (9), 2022.<sup>7</sup>

The Above two case reports have been Published Earlier in which superior vena cava syndrome has been diagnosed in Er and superior vena cava Syndrome Mimicking Anaphylaxis in Er.

A Patient Presenting with Cough, breathing Difficulty, Facial Swelling Should be Considered for the differential Diagnosis of Superior Vena cava Syndrome.

## CONCLUSION

The above case report Mentions the Case of Superior vena cava Syndrome Diagnosed in Er. in the above case report, Potential Challenges of diagnosing SVC Syndrome in Er and cognitive bias are Highlighted.

## REFERENCES

1. Drouin L, Pistorius MA, Lafforgue A, N'Gohou C, Richard A, Connault J, Espitia O. [Upper-extremity venous thrombosis: A retrospective study about 160 cases]. *Rev Med Interne*. 2019 Jan;40(1):9-15. [PubMed]
2. Zimmerman S, Davis M. Rapid Fire: Superior Vena Cava Syndrome. *Emerg Med Clin North Am*. 2018 Aug;36(3):577-584. [PubMed]
3. Carmo J, Santos A. Chronic Occlusion of the Superior Vena Cava. *N Engl J Med*. 2018 Jul 05;379(1):e2. [PubMed]
4. De Potter B, Huyskens J, Hiddinga B, Spinhoven M, Janssens A, van Meerbeeck JP, Parizel PM, Snoeckx A. Imaging of urgencies and emergencies in the lung cancer patient. *Insights Imaging*. 2018 Aug;9(4):463-476. [PMC free article] [PubMed]
5. Friedman T, Quencer KB, Kishore SA, Winokur RS, Madoff DC. Malignant Venous Obstruction: Superior Vena Cava Syndrome and Beyond. *Semin Intervent Radiol*. 2017 Dec;34(4):398-408. [PMC free article] [PubMed]
6. Ronny Cohen, Derrick Mena, Roger Carbajal-Mendoza, Ninon Matos, Nishu Karki International Journal of Angiology 17 (01), 43-46, 2008 [Google Scholar]
7. Mohamed Elamin Salama, Patrick Ukwade, Abdur Rafeh Khan, Hasan Qayyum, Patrick T Ukwade Cureus 14 (9), 2022 [Google Scholar]