

## The Relationship between Depth and Diameter of Human Acetabulum in Dry Hip Bone of Maharashtrian Population

Karkhyle Md Layeeque<sup>1</sup>, Zuberi Hussain Riyaz<sup>2</sup>, Azhar Ahmed Siddiqui<sup>3</sup>

### How to cite this article:

Karkhyle Md Layeeque, Zuberi Hussain Riyaz, Azhar Ahmed Siddiqui/The Relationship between Depth and Diameter of Human Acetabulum in Dry Hip Bone of Maharashtrian Population/Indian J Anat. 2021;10(3-4):77-80.

**Author's Affiliation:** <sup>1</sup>Associate Professor, <sup>2</sup>Professor, <sup>3</sup>Professor and HOD, Department of Anatomy, JIIUs, Indian Institute of Medical Science and Research Warudi Tq Badnapur District Jalna 431202, Maharashtra, India.

**Corresponding Author:** Zuberi Hussain Riyaz, Professor, Department of Anatomy, JIIUs, Indian Institute of Medical Science and Research Warudi Tq Badnapur District Jalna 431202, Maharashtra, India.

**E-mail:** zuberihussain@gmail.com

### Abstract

**Background:** Knowledge of Anatomy of the hip is important in number of surgical procedures like Reconstruction of the acetabulum. In patients with significant acetabular bone deficiency remains a major challenge in total hip arthroplasty. Appropriate anatomic concepts for surgery to treat femoroacetabular impingement require a precise appreciation of the native acetabular anatomy. Since the acetabulum is various shape, width or depth, joint congruences are frequent with minor anatomical variations in the shape of the acetabulum. Hence the present study was undertaken as controversies still exist on the importance of these variations and to prevent problems following surgical procedures such as acetabular reconstruction and femoroacetabular impingement.

**Methods:** 81 dry human hip bones of unknown sex were taken for observation from department of anatomy IIMSR Warudi, Badnapur. All hip bones were adult type. The exact age and sexes of the hip bones were not known. Measurements were taken in millimeters using sliding vernier calliper. The mean and standard deviation of the of Acetabulum- in various dimensions were calculated. The data were analyzed using the SPSS Software. The morphometric values of the two sides were analyzed using an unpaired t-test Diameter and Depth of acetabulum were measured.

**Results:** The purpose of this study was to generate data that would be useful to the orthopaedicians

for geometric modeling. The study would also help the forensic experts. It would also be valuable for the anthropologists in their racial and population studies. The mean  $\pm$ S.D value of depth and diameter of acetabulum were  $27.12 \pm 1.02$ mm, in right side and  $27.02 \pm 1.03$  in left side,  $47.50 \pm 1.27$ mm in right, and  $47.45 \pm 1.33$  in left side respectively. Distribution of anatomical parameters of hip bone and unknown sex related differences within various ethnic parameters are presented in Table. The mean and standard deviation of the of Acetabulum in various dimensions were calculated. The data were analyzed using the SPSS Software. The morphometric values of the two sides were analyzed using an unpaired t-test.

**Conclusions:** Morphological study on adult hip bone is useful for anatomists, anthropologists, experts in Forensic medicine, and orthopedics for performing surgical procedures in this area.

**Keywords:** Acetabulum; Depth; Diameter of acetabulum; Hip arthroplasty; Reconstruction.

### Introduction

The acetabulum (L. Shallow Vinegar cup) is the large cup shaped cavity or socket on the lateral aspect of the hip bone that articulates with the head of the femur it from the hip joint. The acetabular fossa forms the central floor and is rough and non articular.<sup>1</sup> The lunate surface is articular surface widest above (the 'dome'), where weight is

transmitted to the femur. Fractures in this region therefore often lead to poor healing. All three elements of the hip-bone contribute to the formation of the acetabulum in human, but not in equal proportions. The pubis forms the upper and anterior fifth of the articular surface; the ischium forms the floor of the acetabular fossa and rather more than the lower and posterior two fifths of the articular surface and the ilium forms the remainder of the articular surface<sup>6</sup> Inferiorly The acetabular articular surface is deficient opposite the acetabular notch and covered by articular cartilage, which is thickest where the surface is broadest. The acetabular fossa within it is devoid of cartilage it contains fibroelastic fat largely covered by synovial membrane.<sup>2</sup> Depth of Acetabular fossa increased by the acetabular labrum, it is made up of fibrocartilaginous rim which is attached to the acetabular margin.<sup>3</sup> The diameter of the acetabular cavity is constricted by the labral rim, which holds the femoral head, it maintain the joint stability. both as a static restraint and by providing proprioceptive information as stated by Standring.<sup>4,5</sup>

The acetabulum is a deep cup shaped cavity on the lateral aspect of the hip bone about its center, and is directed laterally, downwards and somewhat forwards. It is surrounded by an irregular projecting margin which is deficient inferiorly; this gap is termed the acetabular notch. The floor of the cavity is roughened and non-articular and is termed the acetabular fossa. The sides of the cup present a horseshoe-shaped articular surface which is widest superiorly; in this situation the weight of the trunk is transmitted to the femur in the erect attitude. In the recent state this strip is covered with articular cartilage and provides the surface on which the head of the femur moves within the hip-joint.

### Material & Methods

81 dry human hip bones of unknown sex were taken for observation from department of anatomy IIMSR Warudi, Badnapur. All hip bones were adult type. The exact age and sexes of the hip bones were not known. They were used for tutorial teaching for medical students. Measurements were taken in millimeters using sliding vernier calliper. The mean and standard deviation of the of Acetabulum in various dimensions were calculated. The data were analyzed using the SPSS Software. The morphometric values of the two sides were analyzed using an unpaired t-test. Following parameters of of Acetabulum Diameter and Depth were measured.

Following parameters were used for

measurement:

Acetabulum Diameter and depth, Measurements were taken as per the norms described in anthropometry. The data were analyzed using the SPSS Software. The morphometric values of the two sides were analyzed using an unpaired t-test.

Depth of Acetabulum A thin slide scale was placed across the diameter of the acetabulum. Depth of the acetabulum was measured in mm using vernier scale from the center of the acetabulum to the slide scale

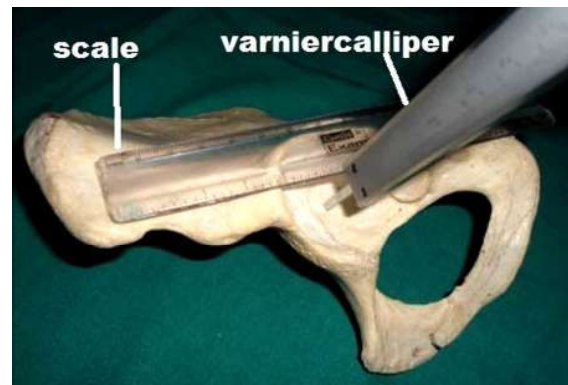


Fig. 1: Measurement of depth of acetabulum by calliper using thin acrylic scale .

Diameter of acetabulum Maximum transverse diameter of the acetabulum was measured using vernier callipers.

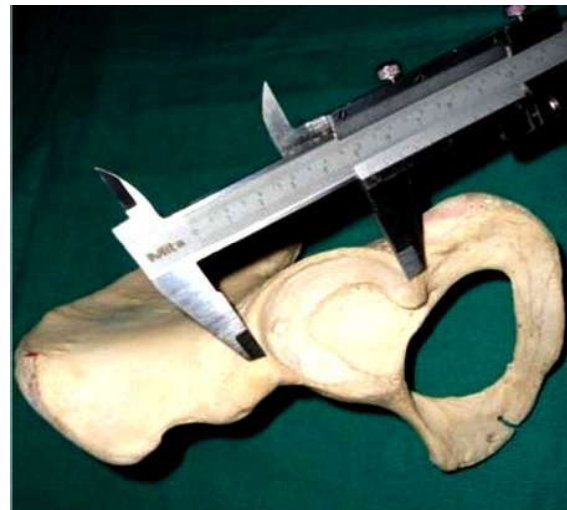

Fig. 2: Showing measurement of diameter of the acetabulum by vernier calliper.

### Result

Summarizes the means and standard deviations of depth and diameter of acetabulum of the hip bone.

The result shown in below.

Parameter	Acetabulum	Mean ± SD(mm)	P-value
Depth	Right	27.12 ±1.02	< 0.0001
	Left	27.02 ±1.03	
Diameter	Right	47.50 ±1.27	< 0.0001
	Left	47.45 ±1.33	

SD= Standard deviation,

P-value = significance between bilateral side of acetabulum of the hip bone. The overall goal of this study was to generate data that would be useful to the orthopaedicians for geometric modeling, it will also helpful to the forensic experts, anthropologists in their racial and population studies. The mean ±S.D value of depth and diameter of acetabulum were 27.12 ± 1.02mm, in right side and 27.02±1.03 in left side, 47.50 ± 1.27mm in right, and 47.45±1.33 in left siderespectively. Distribution of anatomical parameters of hip bone and unknown sex related differences within various ethnic parameters are presented in Table. The mean and standard deviation of the of Acetabulum in various dimensions were calculated. The data were analyzed using the SPSS Software. The morphometric values of the two sides were analyzed using an unpaired t-test.

## Discussion

Depth of acetabulum is important in restoring normal hip mechanics and establishing a good range of movement. It is considered a contributing factor in component dislocation. As a result, to get a better insight, the present study was compared with that of other workers.

Mukhopadhya B et al carried out a study on 100 hip joints of 50 adults obtained from medicolegal post-mortem cases. Three measurements i.e. the depth of acetabulum and the radii of acetabulum and the femoral head were made on each hip. They found that the mean depth of acetabulum was 27.11 mm.<sup>7</sup>

Salamon A et al measured 30 macerated anatomical specimens of pelvic bones. Mean acetabular depth was 30±3.2 mm (21-38 mm).<sup>8</sup> Saikia KC et al recorded the mean depth of acetabulum was 2.5 cm.<sup>9</sup>

In the present study, the mean depth of acetabulum is 27.12±1.02. The mean depth of the present study coincides with the study done by Mukhopadhya B et al.<sup>7</sup>

Lang C et al studied a series of mostly unorthodox measurements on a sample of 45 (19 females and 26 males) dry hip bones from the Grant Collection,

curated in the Medical Sciences Building at the University of Toronto. They found that the mean acetabular depth in males and females was 29.00 mm (SD-3.80) and 26.64 mm (SD- 2.93) respectively.<sup>10</sup>

Kim YH measured the equatorial and meridian diameter of acetabulum in 655 Korean adult cadavers and 172 Korean fetuses with a caliper by taking the greatest width of the cavity (a1), and the depth was measured using two wires. The mean depth of acetabulum in male and female was 20.3 mm and 18.1 mm respectively.<sup>11</sup>

Arsuaga JL et al studied 34 linear variables and 10 non-metrical (morphological) characters in a series of 418 adult hip bones of known sex (227 males and 191 females) The mean acetabular depth in males and females was 25.1 mm (SD = 2.6) and 22.8 mm (SD = 2.2) respectively. They found that acetabulum were deeper in men than in women in both hips and this was significant (P< 0.01 right hip, P < 0.02 left hip).<sup>12</sup>

Chauhan R et al carried out the dissections of fifty-four cadaveric hip joints belonging to the age group of 50-70 years of both sexes. Average depth of acetabulum (in mm) on the right side and left side were 27.49±2.70 (23.0-34.0) and 28.18±2.58 (24.3-34.0) respectively.<sup>13</sup>

According to Murtha PE et al the mean depth of acetabulum in male and female was 22.7 mm and 19.5 mm respectively.<sup>14</sup>

Msamati BC et al found the mean 52 acetabulum depth on right side was 31.7 mm and on left side was.<sup>15</sup>

Saikia KC et al found the mean values of acetabular depth was identical between males:25 (1.6-5.6 cm) and females: 2.5 cm (1.4-5.2 cm).<sup>9</sup> Papaloucas C et al carried out the measurements of 200 hip bones within the Greek population. It was found that in males, in comparison to the females acetabular depth was larger.<sup>16</sup>

The mean(FundaTastekin Aksu, 2006) depth of acetabulum of the dried hip bone was 29.49mm. In the present study it is 27.12mm and is low when compared with the previous study. Whereas the range in the present study lies within the range observed in the previous study. The mean (Funda Tastekin Aksu, 2006) diameter of acetabulum of the dried hip bone was 54.29mm. In the present study it is 47.50 mm and is low when compared with the previous study.<sup>17</sup>

## Conclusion

Scientific improvement urges researchers and

practitioners in any field of medicine to deepen knowledge, resulting in emergence of specialties. Hip surgery being one of them requires more detailed knowledge, about the complex acetabular measurements. Studies based on depth of acetabulum are relatively few in the literature, hence the findings of the present study can provide a guideline for further studies on acetabulum. Considering that total hip replacement is a common surgery performed now a day, awareness of the dimensions of the acetabulum is of immense importance to the orthopaedic surgeons. It will assist prosthetists to construct suitable prostheses.

After comparing the findings of the present study with the previous data available, the observation are similar while others are varying due to the formulas used for these calculations. Morphological study on adult hip bone is useful for anatomists, anthropologists, experts in Forensic medicine, and orthopedics for performing surgical procedures in this area. A radiological study may be added for further accuracy. The purpose of this work is to contribute to the scientific literature, providing anatomical data on the similarities and variations. The depth of acetabulum correlates with acetabular diameter so this information may be helpful during hip arthroplasty, treatment of joint fracture and in diagnosing congenital hip dysplasia.

## References

1. Standring S. Pelvic girdle, gluteal region and hip joint. *Grays Anatomy : The anatomical basis of clinical practice*, Ed 41ST, Andrew Williams. Elsevier Churchill Livingstone. New York. 2005; 1421, 1440.
2. Moore KL, Dalley AF. Pelvis and Perineum. *Clinically oriented Anatomy*, Ed 6, Betty Sun. Lippincott Williams and Wilkins. Philadelphia. 2006; 361.
3. Tortora GJ, Reynolds S, Grabowski. The skeletal system: The Appendicular skeleton. *Principles of Anatomy and Physiology*, Ed 10, Bonnie Rosech. John Wiley and Sons, Inc. Hoboken, NJ; 2003:228-231.
4. Last RJ. Lower limb. *Last's Anatomy Regional and Applied*, Ed 9, RMH McMinn. Churchill Livingstone. New York; 1996:215-216.
5. Solomon L, Warwick DJ. The Hip. *Apley's System of Orthopaedics and Fractures*, Ed 8, Edward Arnold. Oxford University Press. New York; 2001:405,416,446.
6. Kulkarni GS. Surgical Anatomy of Hip joint. *Total Hip Arthroplasty. Textbook of Orthopedics and Trauma*, Ed3, Jaypee Brothers Medical Publishers Pvt. Ltd. New Delhi. 1999; 2910, 3685.
7. Mukhopadhyaya B, Barooah B. Osteoarthritis of hip in Indians. An anatomical and clinical study. *Ind J Orthop*. 1967;1:55-62.
8. Solomon L, Warwick DJ. The Hip. *Apley's System of Orthopaedics and Fractures*, Ed 8, Edward Arnold. Oxford University Press. New York; 2001:405,416,446.
9. Saikia KC, Bhuyan SK, Rongphar R. Anthropometric study of the hip joint in Northeastern region population with computed tomography scan. *Indian J Orthop*. 2008;42:260-6
10. Lang C. Osteometric differentiation of male and female hip bones: An exploratory analysis of some unorthodox measurements. *Canad Rev PhysAnthropol*. 1987;6(1):1-9
11. Kim YH. Relationship between the sphericity of femoral head-acetabulum and the low incidence of primary osteoarthritis of the hip joint in Koreans. *Yonsei Med J*. 1989;30(3):280-7.
12. Arsuaga JL, Carretero JM. Multivariate analysis of the sexual dimorphism of the hip bone in a modern human population and in early hominids. *Am J Physical Anthropol*. 1994;93:241-57.
13. Chauhan R, Paul S, Dhaon BK. Anatomical Parameters of North Indian Hip Joints- Cadaveric Study. *J AnatSoc India*. 2002;51(1):39-42.
14. Murtha PE, Hafez MA, Jaramaz B., DiGiorgia AM. Variations in acetabular anatomy with reference to total hip replacement. *J Bone Joint Surg*. 2008;90-B:308-13.
15. Msamati BC, Igbigbi PS, Lavy CBD. Geometric measurements of the acetabulum in adult Malawians. *East African Med J*. 2003;80(10):546-9.
16. Papaloucas C, Fiska A, Demetriou T. Sexual dimorphism of the hip joint in Greeks. *Forensic Sci Int*. 2008; 179(1):83.
17. FundaTastekinAksu, NazliGulrizCeri, Candan Arman, SuleymanTetik, Morphology and Morphometry of the Acetabulum, *Cilt 20, Sayi 3, (Eylul) 2006, S: 143 - 148.*