

# Current International Trends in Breast Augmentation

Jacob Antony Chakiath<sup>1</sup>, Ravi Kumar Chittoria<sup>2</sup>

**How to cite this article:**

Jacob Antony Chakiath, Ravi Kumar Chittoria/Current International Trends in Breast Augmentation/Indian Journal of Maternal-Fetal & Neonatal Medicine; 9(2):73-83.

**Authors Affiliation:**

<sup>1</sup>Senior Resident, <sup>2</sup>Professor & Registrar (Academic) Head of IT Wing and Telemedicine, Department of Plastic Surgery, JIPMER, Pondicherry 605006, India.

**Correspondence Author:**

**Ravi Kumar Chittoria**, Professor & Registrar (Academic) Head of IT Wing and Telemedicine, Department of Plastic Surgery, JIPMER, Pondicherry 605006, India.

**E-mail:** drchittoria@yahoo.com

**Received on:** 15.10.2022

**Accepted on:** 10.11.2022

**Abstract**

Breast augmentation continues to be the most frequently performed aesthetic surgical procedure worldwide. Improved implant design coupled with surgical advances mean that high quality results with few complications can now be expected in the majority and a precise of progress is perhaps timely. This article forms provide a history of breast augmentation, evolution of breast implant, standardized strategic steps of breast augmentation and compare breast augmentation techniques on an international level.

**Keywords:** Breast Augmentation; Breast; Silicone Implant; Aesthetic Breast; Breast Implant; Augmentation Mastopexy.

## INTRODUCTION

Breast augmentation continues to be the most frequently performed aesthetic surgical procedure worldwide, with a total of 1,488,992 cases reported in 2015.<sup>1</sup> Although there exists consensus regarding several aspects of the surgery, a plethora of controversies remain.<sup>2,3</sup> The surgeon has several choices regarding implant selection methodology, incisions, pocket plane, surgical technique, postoperative management, and the handling of various complications. During the past years, use of autologous fat, acellular dermal matrices, 3-dimensional imaging, insertion funnels, and anatomically shaped implants have added even more options to be considered.<sup>4-11</sup> In this review article, we will briefly describe about the history of

breast augmentation, evolution of breast implant, standardized strategic steps of breast augmentation and compare breast augmentation techniques on an international level.

## History of Breast Augmentation

Although today synonymous with silicone shelled prostheses, either silicone or saline filled, BA has seen the trial of numerous other materials. The list includes lipoma auto transplantation<sup>12</sup>, paraffin injections and such esoterica as ivory and glass balls, ground rubber, ox cartilage, guttapercha, polyethylene chips, polyurethane foam sponge (Ivalon),<sup>13</sup> silastic rubber and liquid silicone. Autologous tissues in the form of local thoracic flaps and distant gluteal adipodermal grafts<sup>14</sup>



This work is licensed under a Creative Commons Attribution-NonCommercial-ShareAlike 4.0.

were tried in the 1950s, but suboptimal results and donor scars prevented their widespread adoption. Interestingly, similar grafts have recently been revived for aesthetic contouring during cancer surgery.<sup>15</sup> The modern era of silicone prostheses commenced with Frank Gerow's implantation of the patient Timmie Jean Lindsey in 1962. Despite its ubiquity and generally inert nature, silicone based implants generated intense debate, and litigation, particularly in America. With large scale studies repeatedly confirming the lack of association with connective tissue disease and cancer<sup>16-21</sup>, the pendulum has swung back in silicone's favour. Its history is, however, an interesting one: Spear's 'inside view' makes a fascinating read of 'junk science, venality and incompetence'.<sup>22</sup> Tebbetts holds the trenchant view that the 'silicone debate' constituted 'one of the greatest hoaxes ever perpetrated on American women by the FDA and plaintiff lawyers'.<sup>23</sup> However, much needed scientific research was stimulated so we now have solid evidence on which to base and guide informed consent.

Reports of breast augmentation surgery, also known as augmentation mammoplasty, date back to 1895, when a fatty tumor (lipoma) was successfully transplanted from a patient's back to a breast defect in a mastectomy patient.<sup>24,25,26,27</sup> In the 1930s, implantation of a glass ball into a patient's breast marked the first implant based breast augmentation. By 1954, attempts at breast augmentation using local dermal fat flaps, adipose tissue, and even omentum were described. Alloplastic materials gained popularity throughout the 1950s and 1960s and included polyurethane, polytetrafluoroethylene (Teflon), and other synthetics. Adverse reactions associated with alloplastic materials were plentiful: local tissue reactions, distortion of the breast mound, increased firmness, and discomfort all contributed to the eventual discontinuation of their use. The history of alloplastic breast augmentation also included epoxy resin, shellac, beeswax, paraffin, rubber, petroleum jelly, and liquefied silicone. Outcomes were not good, and many patients ultimately needed mastectomy. The first modern breast prosthesis was developed in 1961, and since then, implant composition and design have evolved significantly.

#### *From Silicone to Saline, and Back Again*

The first silicone gel implants, introduced in the early 1960s,<sup>28-40</sup> had high complication rates some centres reported an incidence of capsular contracture of up to 70%. This is a foreign body

reaction in which pathologic scar tissue encases the implant, causing it to distort, appear misshapen, harden, and even become painful. Attempts to minimize this reaction led to later generations of silicone implants with polyurethane shells. Inflatable implants filled with sterile saline solution were originally developed in France in 1965. Unlike silicone implants, saline implants have undergone minimal changes since their inception, and grew in popularity during the 1970s in view of the high rates of capsular contracture with silicone implants. However, saline implants have their own problems, and as they became increasingly popular, deflation and the unnatural feel of saline sparked a renewed interest in silicone gel. By the late 1980s, the thinner shelled generation of silicone implants displayed its own frustrating complications including implant rupture, capsular contracture, infection, and possible systemic and disseminated granulomatous disease. From 1992 to 2006, the US Food and Drug Administration (FDA) placed a moratorium on silicone implants due to concerns about a possible link with autoimmune and connective tissue diseases and the possible carcinogenic nature of silicone. While silicone implants were prohibited in the United States, development continued abroad, and eventually the moratorium was lifted after several meta-analyses failed to reveal any link regarding the aforementioned concerns. Today, silicone gel implants dominate the world market. In the United States, approximately 60% of implants contain silicone gel filler, and trends are similar in Europe.

#### *Current Implant Options*

Currently, 3 companies (Allergan, Mentor, Sientra) manufacture and distribute breast implants and implant associated products such as tissue expanders and sizers in the US market.<sup>6</sup> Another company, Motiva, makes an implant that is available in Europe, Asia, and Australia, and the device is currently undergoing a 10 years clinical trial in the United States that began recruiting patients in 16 centers in April 2018.<sup>16</sup> Pending final approval, the Cleveland Clinic Department of Plastic Surgery may be among the centers involved in the clinical trial of the Motiva implant. Innovations in the Motiva implant include a high performance shell that maintains consistent strength and includes a proprietary barrier layer, improved silicone gel filler, 3-D imprinted surface texturing, and an implant shape that adapts with vertical and horizontal movement. It also contains radio frequency identification transponders that can transmit data about the implant wirelessly.

**Table 1:** Summarizes the evolution of silicone breast implants over the last 50 years.

<b>Silicone breast implants by generation</b>	
<i>First generation (1960s)</i>	
Shell	Thick, smooth, silicone elastomer in 2 pieces with Dacron patches posteriorly to facilitate positioning along the chest wall
filler	Silicone gel moderate viscosity
Shape	Anatomic or 'teardrop'
Complications	High capsular contracture rate (approached 100% at 10 years after implantation)
<i>Second generation (1970s)*</i>	
Shell	Thinner, smooth, seamless, no Dacron patches
Filler	Silicone gel thinner and less viscous
Shape	Round
Compilations	Rupture (nearly 60%) diffusion or "Weeding*" of silicone molecules into periprosthetic space and onto breast implant capsule
<i>Third generation (1980s)</i>	
Shell	Thicker, multilayer silicone elastomer, no Dacron patches
Filler	Silicone gel with larger particles increased cross-linking more viscous and thick
<i>Fourth and fifth generation (1990s to present)</i>	
Shell and Filler	Shell thickness and gel viscosity redesigned according to strict criteria by American Society for Testing Methodology and US Food and Drug Administration
Shape	Anatomic (teardrop)
a.	During this period subpectoral implant placement gained popularity, decreasing capsular contracture rates.
b.	Restricted from US market temporarily in 1992; textured surfaces were introduced during this period in an effort to decrease capsular contracture.
c.	Greater quality control during manufacturing; wider variety of implant shpaes and surface texturing available.

**Table 2:** Lists the advantages and disadvantages of silicone and saline breast implants.

<b>Advantages and disadvantages of silicone and saline breast implants</b>		
	<b>Advantages</b>	<b>Disadvantages</b>
Silicone	Consistency with palpation mimics dense, natural breast tissue	Exposure to silicone in the event of rupture, and rupture not immediately evident
	Quicker adjustment to alterations in the external environment	Higher initial cost (nearly double that of saline implants), including cost of recommended monitoring (imaging) to ensure implant integrity
Saline	Only a small incision is required for implant insertion (implant filled with saline to desired volume through a port)	Overfilling leads to increased firmness, palpability of the implant edge
	Saline is safely absorbed by the body in the event of rupture, and rupture is immediately evident (breast deflation)	Underfilling results in rippling and a higher risk of rupture from the shell folding upon itself
	No concern for silicone exposure in the event of rupture	Consistency with palpation mimics water (as opposed to natural breast tissue)
		Slow to adjust to alterations in the external environment (eg, feels cold after swimming)
		Slightly higher rate of rupture

Source @ Hidalgo et al., Current Trends in Breast Augmentation, Aesthetic Surgery Journal 2018, Vol 38(2) 133-148.<sup>41</sup>

### *Surface (Textured vs Smooth)*

Developed in the 1980s, texturing of the implant surface disrupts capsule formation around the prosthesis. Additionally, texturing stabilizes an anatomically shaped (teardrop) implant within the breast pocket, reducing malrotation.<sup>42,43</sup> The first textured implants were covered with polyurethane foam, but they were ultimately withdrawn from the US market because of concern for in vivo degradation to carcinogenic compounds. The focus subsequently turned to texturing implant shells by mechanically creating pores of different sizes. Smooth implants, by contrast, are manufactured by repeatedly dipping the implant shell into liquid silicone.<sup>2</sup> The capsular contraction rate has been shown to be lower with textured silicone than with smooth silicone (number needed to treat = 7 - 9), and evidence suggests a lower risk of needing a secondary procedure.

### *Form-Stable vs Fluid-Form*

Silicone is a polymer. The physical properties of polymers vary greatly and depend on the length of the individual chains and the degree to which those chains are cross-linked. Liquid silicone contains short chains and sparse cross-linking, resulting in an oily compound well suited for lubrication. Silicone gel contains longer chains and more cross-linking and is therefore more viscous.

In "form stable" implants, the silicone interior has sufficient chain length and crosslinking to retain the designed shape even at rest, but they require slightly larger incisions. "Fluid form" refers to an implant with silicone filler with shorter chain length, less cross-linking, and more fluidity.

### *Shell*

As with silicone fillers, the properties of silicone implant shells also depend on chain length and cross-linking within the polymer. Silicone elastomer shells contain extensively cross-linked chains that impart a flexible yet rubbery character. Silicone elastomers can also be found in facial implants and tissue expanders.

### *Implant shape (round vs anatomic)*

The shape of an implant is determined by the gel distribution inside of it. To understand gel distribution and implant shape, one must understand the gel shell ratio. This ratio increases as cohesivity of the filler increases, and it represents increased bonding of the gel filler to the shell and a preserved implant shape at rest. The gel shell ratio varies among manufacturers, and a less viscous

filler may be more prone to rippling or loss of upper pole fullness in some patients. For this reason, careful analysis, patient and implant selection, and discussion of complications remain paramount. No anatomically shaped implant is manufactured with a smooth shell, but rather with a textured shell that resists malrotation. However, in the United States, 95% of patients receive round implants.

## **Standardized Step Approach to Breast Augmentation**

### *Pre-operative Stages*

#### **Step 1:** *Ptotic versus Nonptotic Breasts*

Step 1 entailed a preoperative examination and evaluation of the breasts. Breast measurements and markings, including sternal notch to nipple distance, breast height, midclavicular point to nipple distance, and intermammary distance, were performed. The nipple to inframammary fold (N-IMF) distance, at rest and under maximum stretch, was measured as well. Skin laxity was assessed by a skin stretch test, or by calculating the difference between the N-IMF distance both at rest and during maximal stretch. If skin stretch and N-IMF fold distances on maximal stretch were less than 4 and 10 cm, respectively, the breast could be appropriately corrected with a breast augmentation alone and dual plane approach.<sup>44</sup> Patients with these measurements were not considered ptotic and were excluded from this study. Patients with an N-IMF fold distance greater than 10 cm on maximal stretch or skin stretch of greater than 4 cm were considered for augmentation mastopexy and underwent further assessment to devise a case specific management plan.<sup>45-48,50</sup>

#### **Step 2:** *Breast Volume Assessment, Synthetic versus Biological Fill*

In step 2, the breast volume was assessed to determine whether the patient required a breast augmentation mastopexy, they were simply dissatisfied with the shape of their breasts, or had adequate breast volume requiring a mastopexy alone. Dissatisfaction with current breast volume was determined by whether the patient needed to use bra padding or whether they sought a larger cup size; these patients were identified as having inadequate breast volume.



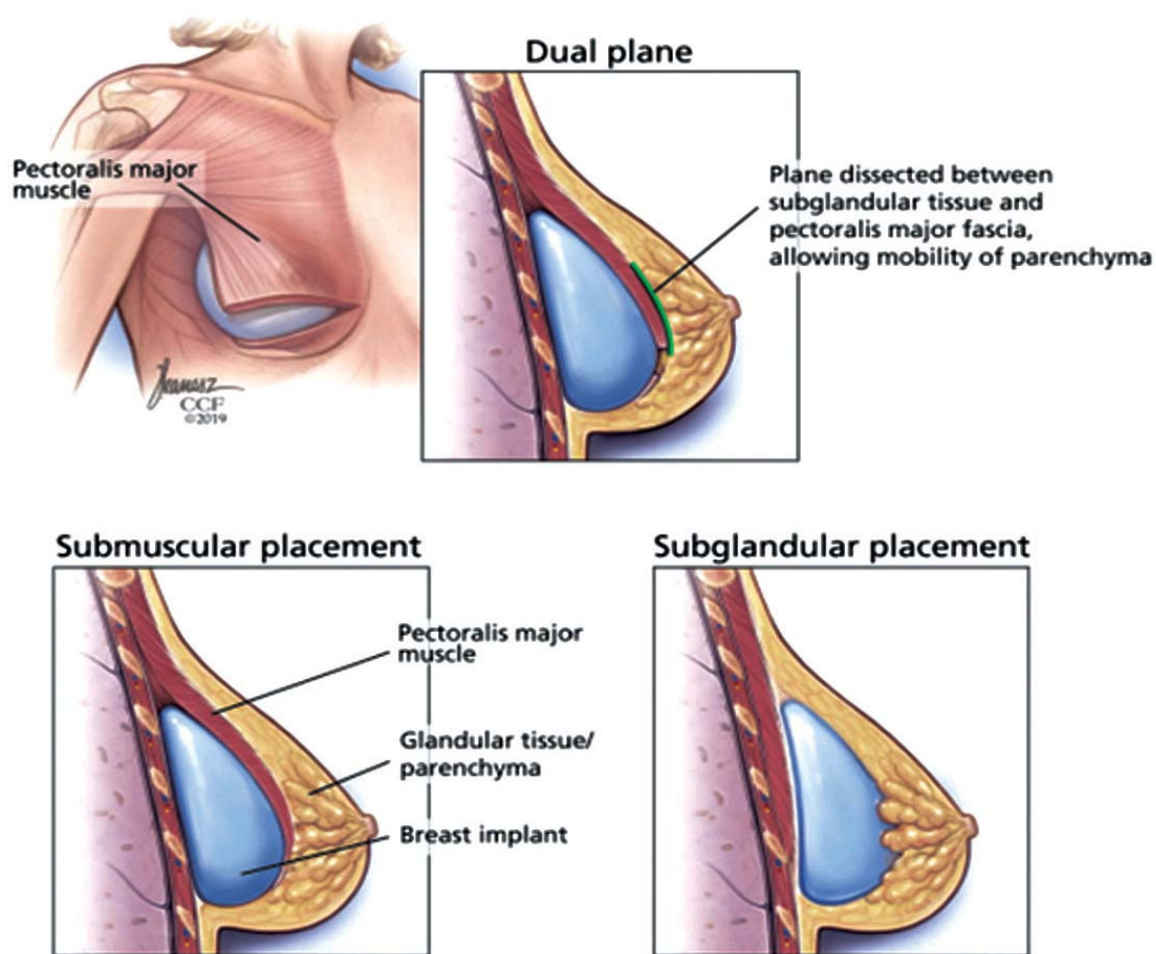
**Step 3: Implant**

The pocket plane was determined in step 3, according to the skin pinch test in the upper pole as well as the medial and lateral breast. Patients with a skin pinch test score greater than 2 cm were considered suitable for a subfascial pocket, whereas those with an upper pole pinch greater than 3 cm were planned for subglandular placement of the implant. (fig. 1) Patients with a pinch test score less than 2 cm and increased skin laxity were considered for submuscular implant placement. After that, the implant size, diameter, and projection were considered. In all patients, a rounded smooth cohesive gel implant with a medium projection profile was used. The patient's size preference was considered in terms of safely achieving the maximum volume possible. In deciding on

the width implant base, it was imperative to estimate how much the native glandular breast volume would contribute to the final achieved breast base width.<sup>7-10</sup> Therefore, the width of the base was measured while the skin was pinched to simulate breast dimensions after mastopexy. This maneuver effectively narrowed the base width and provided a close approximation of the outer limits of the implant diameter. The optimal implant width was calculated by measuring the desired final breast width (from the anterior axillary line to 1 cm short of the midline of the chest) and subtracting the breast soft tissue contribution, recorded during step 3.

**Step 4: Choice of Surgical Technique**

The choice of surgical technique for excess skin envelope reduction was based on



**Fig. 1:** Placement of Breast Implant

Source @ Raffi et al, Breast Augmentation Surgery, Cleveland Clinic Journal of Medicine, Volume 86, February 2019.51

calculations of the vertical excess and the appropriate skin pattern design sought through operative management, using breast markings and measurements. The key element was to mark the skin pattern from the midpoint of the clavicle, usually 7 cm from the sternal notch, and to mark the breast meridian through the desired nipple position. An ideal nipple is approximately 10 cm from the breast meridian, measured on a straight line. During this step, we calculated the vertical excess: the total measured distance from the desired nipple areolar complex (NAC) level to the N-IMF minus the desired nipple IMF distance, which in most cases ranged from 8 to 10 cm in length. The authors marked the NAC down by 2–3 cm in preoperative markings. The exact neo-NAC position was rechecked intraoperatively after implant insertion in accordance with the most projecting point of breast mound. A periareolar technique was used to reduce the skin envelope if the vertical skin excess was less than 3 cm, a circumvertical technique if the excess was 3–4 cm, and a wise pattern reduction technique if the excess was greater than 4 cm. The rest of the preoperative breast markings were drawn according to established techniques.

### *Intraoperative Stage*

#### **Step 5:** *Determining the Horizontal Skin Excess*

In step 5, the horizontal skin excess was assessed after implant insertion in the predetermined pocket. This involved pinching the excess horizontal component of the envelope and draping it over the implant.

### *Surgical Procedures*

Each patient was administered a standard dose of prophylactic antibiotics (1 g of ceftriaxone) 1 hour before the first incision. A field block was administered to reduce postoperative pain and limit the need for intraoperative narcotics. All surgical procedures were performed under general anesthesia. In the upright position, the patient's pectoralis muscles relax, enabling a more accurate assessment and positioning of the implant level to be made during surgery. With the patient in an upright position, proper re-draping of the skin envelope during assessment of the horizontal excess can be accomplished. A 42 mm diameter cookie cutter was used to mark the new NAC. The

skin was then incised according to the preoperative markings, and the implant placed in the pocket via a vertical incision, which was then sutured. After the implant was placed in position, de-epithelialization of the marked skin was carried out systematically according to the mastopexy technique decided in step 4 of the preoperative procedure. Step 5, to assess the horizontal skin excess, was performed intra-operatively and staples were used to outline the skin excess removal. The patient was tilted to the upright position to assess the implant height and overall shape.

### *Circumvertical Technique*

A varying amount of skin along the vertical limbs of the incision was used to address the horizontal skin excess. This was done by approximating the medial and lateral limbs of the vertical incision and assessing the amount of skin to be removed while adjusting the lower pole shape. In patients with little vertical excess, it was used to expand the periareolar opening. In the preoperative evaluation and assessment of each patient, we determined how to incorporate any excess skin into either a small horizontal scar or a j-shaped scar. As a result, none of the patients in this study required removal of a horizontal wedge of skin.

### *Inverted T-scar Mastopexy Technique*

A superior pedicle was used, allowing us to freely address the horizontal excess by removing tissue from the medial pillar of the vertical incision. The implant was placed in the dissected pocket and then the horizontal excess was accessed by bringing together the vertical limbs of the incision, starting at the base of the new areolar position and moving down to the distal point of the vertical scar (7–11 cm from the lower level of the new nipple position).

Finally, after proper hemostasis was ensured, wound closure was performed in multiple layers, starting with the underlying breast pillars closed with polyglactin 9102-0 sutures followed by interrupted 3-0, 3-0 polydioxanone dermal, and ending with running subcuticular 4-0 poliglecaprone 25 sutures along the incisions. The areola was sutured using polydioxanone 3-0 dermal sutures and a running circumareolar 4-0 Prolene suture. No surgical drains were placed. Patients were dressed, and a supportive medical brassier was put on.

### *Postoperative Satisfaction Assessment*

A patient satisfaction questionnaire formed by our department was administered at the 1 year follow-

up visit, allowing time for scar maturation and postoperative edema to subside. The questionnaire covered areas such as satisfaction with undressed appearance, satisfaction with dressed appearance, satisfaction with overall body image, and overall satisfaction with the surgery. A score of one indicated that the patient was not satisfied at all, and a score of five indicated that the patient was very satisfied.

Surgeon satisfaction was also rated at the 1 year follow up visit; it was based on the three objective measures of suprasternal notch to nipple distance (SSN-N), N-IMF, and nipple to midline distance (N-ML), and the occurrence of complications.

### *Compare Breast Augmentation in International level*

Breast augmentation is an increasingly common performed operation, but apparently there exists significant international discordance regarding several aspects of the procedure. This may be due to a variety of reasons, including:

1. Surgeons preference based on training, experience and tradition
2. Cost
3. Hesitance to embrace new technology for personal as well as potentially legal reasons (different healthcare systems)
4. Lack of knowledge regarding established standards

The assumption that trends are geographically based was one of the working hypotheses. It appears that such trends, be it fashion, design, or technology, and usually have a place of origin and then spread. Regarding aesthetic surgery, in many instances, trends arguably emerge in the United States. It was therefore one of the aims to evaluate if there exist current practice preferences in the United States which are, based on current literature, common standards and soon to be established elsewhere or vice versa. Comparing the United States to the rest of the world would be possible, but given the potential influence of different cultures and ethnic backgrounds, we opted to present the responses broken down. Unfortunately, information regarding location of practice of the surgeons was not obtained on a state level, so trends within the United States could not be analyzed in further detail. In this setting, the ongoing debate when to use which type of implant is certainly one of the most controversial and relevant issues, as choosing the right implant shape

is a key decision. Besides volume, breast proportion and shape play the major roles to achieve an aesthetically pleasing outcome. Anatomical and round prosthesis can be used successfully and the surgeon should assess the potential benefits of both types during the surgical planning process. In 2015, *Hedén* et al. discussed some misconceptions regarding anatomical implants and stated that they should primarily be used in cases of poor soft tissue coverage, tuberous breasts, or a short lower pole.<sup>15</sup> A wide spread opinion is that anatomic implants will create a more natural look, but are associated with the possibility of malrotation (estimated risk between 5.2% and 14%). However, with appropriate surgical planning and techniques, these risks can be minimized.<sup>52,53</sup> Despite these facts, when evaluating the aesthetic results and patient satisfaction comparing anatomically shaped and round implants,<sup>19</sup> several authors observed the inability to visually identify the type of implant used.<sup>20-22</sup> This discrepancy also becomes apparent in the presented survey population. About 90% of surgeons in the United States and Latin America never use anatomically shaped implants, whereas in Europe, Asia, and Oceania 22% to 46% of surgeons do. One third of European surgeons even use them more than half the time, and smaller implants tend to be used in lower BMI patients, which are potentially better suited for such devices. Autologous fat transfer for breast augmentation is a growing sector and a still developing technology. The safety of the technique has been evaluated extensively. Groen et al conducted a systematic review including a large series of patients having received a cosmetic breast augmentation with autologous fat, and showed that complication rates and radiological findings are similar to those after implant-based breast augmentation. In the setting of breast malignancies, as reported by *Kronowitz* et al., the only group in which the loco regional cancer recurrence rate was higher in the lipofilling cohort was a subgroup treated with hormonal therapy. The presented analysis revealed that autologous fat as a primary breast augmentation technique is used notably more often in Europe and Asia compared to the other countries. There was concern expressed by some respondents as write in comments, that the technique does not have FDA approval and may cause legal problems (eg, Australia) due to the potential interference with breast cancer screening and the current lack of long term experience. Regarding ALCL, while the absolute risk of developing it is extremely low among women with implant mammoplasties (about 1 to 3 cases per million women), this



malignancy occurs much more frequently in this group when compared with the general population (high relative risk). Despite being so rare, it appears interesting that according to the presented survey 2% to 14% of all plastic surgeons have encountered a case of ALCL in their practice, underscoring the importance of continuous retro and prospective data acquisition in order to allow for better risk stratification.<sup>54</sup> A higher risk patient population also includes Factor V Leiden patients. Affected heterozygote individuals have a 3 to 10 times higher risk for developing deep venous thrombosis compared with the general population. Regardless, about half of surgeons would operate on such a patient using sequential compression devices at the very least, while adding anticoagulation/chemoprophylaxis as an additional preventive measure. Only in Asia, most surgeons would avoid performing a breast augmentation in a heterozygous patient, which might be due the extremely rare prevalence in that region and the associated lack of experience regarding prevention and treatment. In the wide field of new technologies, many advances such as the introduction of ADMs, insertion funnels, or protective sheets have been described and promoted. Increased cost of the surgery and the lack of a clear consensus regarding their effectiveness might explain the international variation regarding the use of such products. Trying to preoperatively determine implant size on tissue based systems has several advantages over other methods like using externally applied sizers, rice bags, or similar. The latter techniques remain the most commonly employed however, both in the United States and abroad. Three dimensional imaging and preoperative surgical simulation have also been some of the newer emerging technologies, but have not caught on as one might have suspected and internationally, few surgeons use it. Compared to the United States, in other countries hardly any surgeons believe it to be a good marketing, educational, or preoperative sizing tool. Besides implant shape, few issues surrounding breast augmentation have been discussed more extensively than those regarding filling material. In all surveyed countries, over 80% of surgeons use 100% silicone implants only, whereas in the United States only 20% use that type only. Generally, it has been shown that silicone implants appear to be safe with a high degree of patient satisfaction. While better evidence from larger studies is still needed to clarify associations between silicone breast implants and health outcomes, silicone implants remain the internationally by far most preferred option. As over ten years have passed since silicone implants

were reimplemented in the United States, the profound discrepancy cannot easily be explained. Also considering the use of textured vs smooth breast implants there were striking differences, with at least 80% of surgeons in Europe, Latin America, and Asia using mostly textured implant shell surfaces, while in the United States 85% of respondents use mostly or even exclusively smooth implants. This appears of interest, as textured implants tend to have lower rates of capsular contracture, less risk of displacement, and lower rates of infection. However, they are currently thought to be associated with higher rates of ALCL development, as propagated by the ASPS and ASAPS.<sup>37</sup> Implant placement is another area of discordance, mostly regarding common practices in Latin America, where surgeons often use a subglandular or subfascial location. Originally described and popularized by *Graf* et al, several subsequent Latin American studies have commented on the advantages of subfascial implant placement, which might explain why it is more popular in those countries.<sup>39,40</sup> Current evidence regarding advantages of subfascial placement, however, is less conclusive. Despite not specifically commenting on subfascial placement, a recent meta-analysis performed by Egeberg et al<sup>55</sup> evaluating the outcomes of 17,520 breast augmentations, showed that a subglandular implant placement increases the chances of developing a capsular contracture 2-fold compared to submuscular placement. Ultimately, more data will be needed to better assess the value of subfascial implant placement. In order to prevent infection and potentially also biofilm formation, use of prophylactic antibiotics perioperatively and during the postoperative phase is common place, despite the fact that while there exists strong evidence that patients undergoing clean aesthetic breast surgery benefit from routine prophylaxis, there is currently only weak evidence regarding optimal antibiotic dose and duration or optimal irrigation type. Measures for prevention of capsule formation were also surprisingly diverse. For instance, in the United States and Europe almost half the surgeons use pharmacologic agents to prevent or treat capsular contracture regardless of the fact that 78% (United States) to 96% (Oceania) do not think that they work or are at least not sure about it, which goes in line with the little supportive evidence for such treatment. Reoperations are not uncommon in breast augmentation surgery, and while capsular contracture and size change were uniformly the most common reasons to perform such operations in all countries except for Oceania, treatment



approaches were very different. With ADMs mostly used in the United States to treat recurrent contractures, only when faced with double bubble deformities or bottoming out do such matrices seem to play a major role in other countries.

## CONCLUSION

Studies have shown that after undergoing breast augmentation surgery, patients note improvement in body image, and satisfaction rates range from 85% to 95% with respect to self-confidence and body image. An evaluation of patient responses on the validated Breast-Q Augmentation Questionnaire showed the following satisfaction rates: breasts 83%, psychosocial well being 88%, and sexual functioning 81%.<sup>15</sup> Although epidemiologic studies have reported higher suicide rates in women with cosmetic breast implants, this likely stems from preoperative psychological factors and underscores the role of psychiatric referral in patients with a mental health history or in those whom the surgeon deems it necessary. Several high quality studies have demonstrated that quality of life and psychosocial functioning (including depression) markedly improve after breast augmentation surgery. Among a cohort of Norwegian patients, breast implant surgery resulted in improved motivation to perform daily activities, as well as improved quality of life from both a psychosocial and aesthetic perspective. Interestingly, a recent study reported that patients who underwent breast implant surgery alone reported greater satisfaction and psychosocial quality of life than patients who underwent combination breast augmentation and mastopexy (breast lifting) surgery. Additional data are needed to refine our understanding of the complex interplay between psychosocial factors before and after surgery in patients seeking and undergoing breast augmentation procedures.

## REFERENCES

1. International Society of Aesthetic Plastic Surgery. ISAPS International Survey on Aesthetic/Cosmetic Procedures Performed in 2015. USA: 8. Accessed January 20, 2017.
2. Hidalgo DA. Breast augmentation: choosing the optimal incision, implant, and pocket plane. *PlastReconstr Surg.* 2000;105(6):2202-2216; discussion 2217.
3. Hidalgo DA, Spector JA. Breast augmentation. *PlastReconstr Surg.* 2014;133(4):567e-583e.
4. Chang JB, Small KH, Choi M, Karp NS. Three-dimensional surface imaging in plastic surgery: foundation, practical applications, and beyond. *PlastReconstr Surg.* 2015;135(5):1295-1304.
5. Del Vecchio DA, Bucky LP. Breast augmentation using preexpansion and autologous fat transplantation: a clinical radiographic study. *PlastReconstr Surg.* 2011;127(6):2441-2450.
6. Khouri R, Del Vecchio D. Breast reconstruction and augmentation using pre-expansion and autologous fat transplantation. *ClinPlast Surg.* 2009;36(2):269-80, viii.
7. Khouri RK, Eisenmann-Klein M, Cardoso E, et al. Brava and autologous fat transfer is a safe and effective breast augmentation alternative: results of a 6-year, 81-patient, prospective multicenter study. *PlastReconstr Surg.* 2012;129(5):1173-1187.
8. Kovacs L, Eder M, Zimmermann A, et al. Three-dimensional evaluation of breast augmentation and the influence of anatomic and round implants on operative breast shape changes. *Aesthetic Plast Surg.* 2012;36(4):879-887.
9. Maxwell GP, Gabriel A. Acellular dermal matrix for reoperative breast augmentation. *PlastReconstr Surg.* 2014;134(5):932-938.
10. Roostaeian J, Adams WP Jr. Three-dimensional imaging for breast augmentation: Is this technology providing accurate simulations? *AesthetSurg J.* 2014;34(6): 857-875.
11. Voglimacci M, Garrido I, Mojallal A, et al. Autologous fat grafting for cosmetic breast augmentation: a systematic review. *AesthetSurg J.* 2015;35(4):378-393.
12. Czerny V. Plastischer ersatz der Brustdrüsen. *ZentralblChir* 1895;27:72.
13. Nahabedian M. Explantation of 41-year-old implants following primary breast augmentation. *Ann PlastSurg* 2007;58:91e4.
14. Watson J. Some observations on free fat grafts: with reference to their use in mammoplasty. *Br J PlastSurg* 1959;12:263e74.
15. Kijima Y, Yoshinaka H, Owaki T, et al. Early experience of immediate reconstruction using autologous free dermal fat graft after breast conservational surgery. *JPlastReconstrAesthetSurg* 2007;60:495e502.
16. Gabriel SE, O'Fallon WM, Kurland LT, et al. Risk of connective tissue diseases and other disorders after breast implantation. *N Engl J Med* 1994;330:1697e702.
17. Sanchez-Guerrero J, Colditz GA, Karlson EW, et al. Silicone breast implants and the risk of connective-tissue diseases and symptoms. *N Engl J Med* 1995;332:1666e70.
18. Janowsky EC, Kupper LL, Hulka BS. Meta-analysis of the relation between silicone breast implants and the risk of connective-tissue diseases. *N Engl J Med* 2000;342:781e90.
19. Institute of Medicine. Safety of silicone breast implants. Washington, D.C.: National Academy

- Press; 1999.
20. Muzaffar AR, Rohrich RJ. The silicone gel-filled breast implant controversy: an update. *PlastReconstrSurg* 2001;109:742e7.
  21. Deapen DM, Hirsch EM, Brody GS. Cancer risk among Los Angeles women with cosmetic breast implants. *PlastReconstrSurg* 2007;119:1987e92.
  22. Spear S. The breast implant story. *Ann PlastSurg* 2006;56: 573e83
  23. Tebbetts JB, Tebbetts TB. *The best breast*. 1st ed. Dallas: CosmetXpertise; 1999.
  24. Derby BM, Codner MA. Textured silicone breast implant use in primary augmentation: core data update and review. *PlastReconstrSurg* 2015; 135(1):113-124.
  25. Maxwell GP, Gabriel A. Breast implant design. *Gland Surg* 2017; 6(2):148-153.
  26. Gabriel A, Maxwell GP. The evolution of breast implants. *ClinPlastSurg* 2015; 42(4):399-404.
  27. American Society of Plastic Surgeons. Procedural statistics trends 1992-2012. Accessed January 17, 2019.
  28. American Society of Plastic Surgeons. Plastic surgery statistics report 2016.-statistics-full-report-2016.pdf. Accessed January 17, 2019.
  29. Henderson PW, Nash D, Laskowski M, Grant RT. Objective comparison of commercially available breast implant devices. *Aesthetic PlastSurg* 2015; 39(5):724-732.
  30. Adams WP Jr, Mallucci P. Breast augmentation. *PlastReconstrSurg* 2012; 130(4):597e-611e.
  31. Spear SL, Jespersen MR. Breast implants: saline or silicone? *AesthetSurg J* 2010; 30(4):557-570.
  32. Cronin TD, Gerow FJ. Augmentation mammoplasty: a new "natural feel" prosthesis. In: *Transactions of the Third International Conference of Plastic Surgery: October 13-18, 1963, Washington, DC*.
  33. Maxwell GP, Gabriel A. The evolution of breast implants. *PlastReconstrSurg* 2014; 134(suppl 1):12S-17S.
  34. Hillard C, Fowler JD, Barta R, Cunningham B. Silicone breast implant rupture: a review. *Gland Surg* 2017; 6(2):163-168. doi:10.21037/gs.2016.09.12
  35. Derby BM, Codner MA. Textured silicone breast implant use in primary augmentation: core data update and review. *PlastReconstrSurg* 2015; 135(1):113-124.
  36. Tugwell P, Wells G, Peterson J, et al. Do silicone breast implants cause rheumatologic disorders? A systematic review for a court-appointed national science panel. *Arthritis Rheum* 2001; 44(11):2477-2484.
  37. Alpert BS, Lalonde DH. MOC-PS(SM) CME article: breast augmentation. *PlastReconstrSurg* 2008; 121(suppl 4):1-7.
  38. Hidalgo DA, Spector JA. Breast augmentation. *PlastReconstrSurg* 2014; 133(4):567e-583e.
  39. ClinicalTrials.gov. Study of the safety and effectiveness of Motiva Implants. Accessed January 17, 2019.
  40. EstablishmentLabs. MotivaImplants.https://motivaimplants.com/whymotiva/innovation-for-enhanced-safety/. Accessed January 17, 2019.
  41. Hidalgo et al, Current Trends in Breast Augmentation, *Aesthetic Surgery Journal* 2018, Vol 38(2) 133-148.
  42. Sforza M, Zaccheddu R, Alleruzzo A, et al. Preliminary 3-year evaluation of experience with silksurface and velvetsurface Motiva silicone breast implants: a single-center experience with 5813 consecutive breast augmentation cases. *AesthetSurg J* 2018; 38(suppl 2):S62-S73.
  43. Huemer GM, Wenny R, Aitzetmüller MM, Duscher D. Motiva ergonomix round silksurface silicone breast implants: outcome analysis of 100 primary breast augmentations over 3 years and technical considerations. *PlastReconstrSurg* 2018; 141(6):831e-842e.
  44. Choudry U, Kim N, Cunningham B. The BodyLogic™ system: intelligent implant selection in primary breast augmentation. *JSurg Res*. 2014;186:672.
  45. Khavanin N, Jordan SW, Rambachan A, et al. A systematic review of single-stage augmentation-mastopexy. *PlastReconstr Surg*. 2014;134:922-931.
  46. Nahai F, Fisher J, Maxwell PG, et al. Augmentation mastopexy: to stage or not. *AesthetSurg J*. 2007;27:297-305.
  47. Alderman AK, Hall-Findlay EJ. Principles of mastopexy. In: Calobrace MB, Kortesis BG, Bharti G, et al (Eds.) *AugmentationMastopexy*. Cham, Switzerland: Springer; 2020.
  48. Sanniec K, Adams WP. Principles of breast augmentation: the process of augmentation mastopexy and criteria for staging. In Calobrace MB, Kortesis BG (Eds.) *Augmentation Mastopexy*. Cham, Switzerland: Springer; 2020:11-29.
  49. Smith RA, Cokkinides V, von Eschenbach AC, et al; American Cancer Society. American Cancer Society guidelines for the early detection of cancer. *CA Cancer J Clin*. 2002;52:8-22.
  50. Brink RR. Management of true ptosis of the breast. *PlastReconstr Surg*. 1993;91:657-662.
  51. Raffi et al, Breast Augmentation Surgery, *Cleveland Clinic Journal of Medicine*, Volume 86, February 2019.
  52. Choudry U, Kim N, Cunningham B. The BodyLogic™ system: intelligent implant selection in primary breast augmentation. *JSurg*

- Res. 2014;186:672.
53. Persoff MM. Vertical mastopexy with expansion augmentation. *Aesthetic Plast Surg.* 2003;27:13-19.
54. de Jong D, Vasmel WL, de Boer JP, et al. Anaplastic large cell lymphoma in women with breast implants. *JAMA.* 2008;300(17):2030-2035.
55. Egeberg A, Sørensen JA. The impact of breast implant location on the risk of capsular contraction. *Ann Plast Surg.* 2016;77(2):255-259.

