

## Disseminated Intravascular Coagulation Induced Postpartum Hemorrhage complicating Pregnancy

Josephine Leshiini<sup>1</sup>, Priya Govil<sup>2</sup>, Kishalay Datta<sup>3</sup>

### How to cite this article:

Josephine Leshiini, Priya Govil, Kishalay Datta/Disseminated Intravascular Coagulation induced Postpartum Hemorrhage complicating Pregnancy /Indian J Emerg Med 2023;9(3):71-73.

### Abstract

DIC and obstetrical hemorrhage are leading causes of maternal death and fetal complications worldwide, especially in under developed and developing nations. DIC induced PPH is a rare complication seen in pregnancy, often fatal. In this case report, we discuss an interesting case where a primigravida had delivery at home (unregistered) with postpartum hemorrhage and how she was managed effectively.

**Keywords:** Disseminated Intravascular Coagulation; Postpartum Hemorrhage; Obstetrics Complications; Uterine Atony.

## INTRODUCTION

Postpartum hemorrhage is the most dreaded complication in pregnancy. It is defined as (as per 2017 American College of Obstetrics and Gynecology) a cumulative blood loss greater than 1000 ml with signs and symptoms of hypovolemia within 24 hours of the birth process, regardless of the route of delivery. Blood loss more than 500 ml during normal vaginal delivery should be considered abnormal. PPH can occur during the first 24 hours of delivery (called primary PPH) or between the 24 hours after delivery upto 12 weeks

postpartum period (called secondary PPH).<sup>1,2</sup>

Disseminated intravascular coagulation (DIC) is a severe complication in obstetric diseases characterized by an over activation of the coagulation and fibrinolytic systems leading to widespread microvascular and macrovascular thrombosis, thus causing disruption of blood supply to various vital organs. The activation of the coagulation cascade leads to over consumption and depletion of platelets and coagulation proteins, which can provoke concurrent severe bleeding/thrombosis.<sup>3,4</sup> In obstetrics, DIC often leads to bleeding complications rather than thrombosis.

Although DIC is well known by obstetricians, the underlying diseases of DIC associated organ failure in critically ill obstetrics patients are not well known.

## CASE

A 20 year old female was brought to the Emergency department of our hospital with severe vaginal bleeding. Based on the history by the attendants, the patient, a primigravida, had a

**Author's Affiliation:** <sup>1</sup>Post Graduate trainee, <sup>2</sup>Senior Consultant, <sup>3</sup>Director and HOD, Emergency Medicine, Max Super Speciality Hospital, Shalimar Bagh 110088, Delhi, India.

**Corresponding Author:** Josephine Leshiini, Post Graduate trainee, Emergency Medicine, Max Super Speciality Hospital, Shalimar Bagh 110088, Delhi, India

**E-mail:** josephineleshiinii@gmail.com

**Received on:** 25-02-2023

**Accepted on:** 28-03-2023



full term vaginal delivery at her home 1 day back. The antepartum period was unregistered and not followed in any medical setup. The per abdomen examination revealed a lax, non contracted uterus with vaginal bleeding. The patient had petechial rashes over the lower limbs. The patient was in hypotensive shock. Uterine massage was given, uterotonic medications were given, injection Tranexamic acid was given (anti fibrinolytic). Immediate blood transfusion with fresh frozen plasma and platelet transfusion were started, inotropic support with fluid management was given.

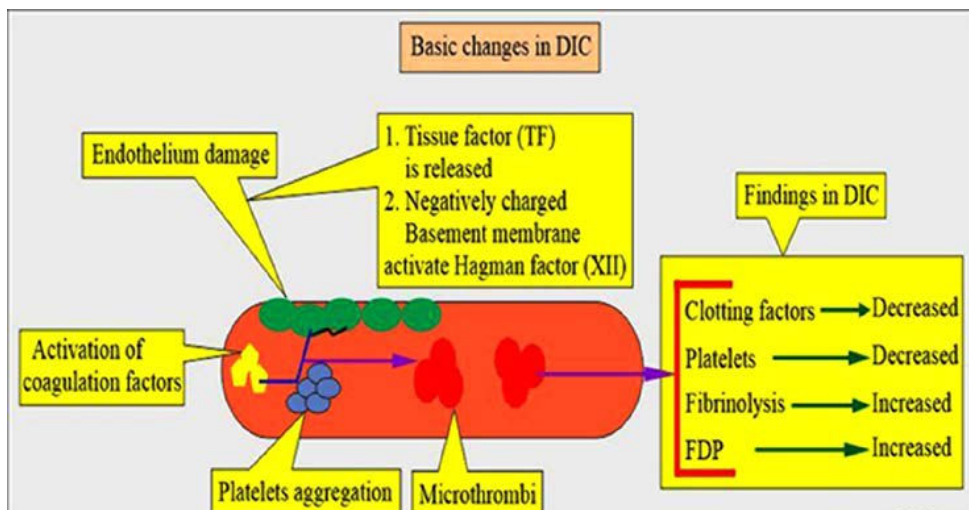
Patient uterine atony persisted leading to vaginal bleeding (reduced). Patient was taken up for an emergency hysterectomy (under high risk). The surgery was successful and the patient shifted to the critical care unit. Multiple blood transfusion, platelet transfusion and plasma

transfusion continued and injection of Tranexamic acid continued. Blood reports suggestive to raised D-dimer, fibrin degradation products with raised leukocyte count. Patient was diagnosed with DIC and treatment continued.

The patient recovered well after 7 days of ICU care. Post-discharge, the patient under went psychiatric session for the next 3 months.

### DISCUSSION

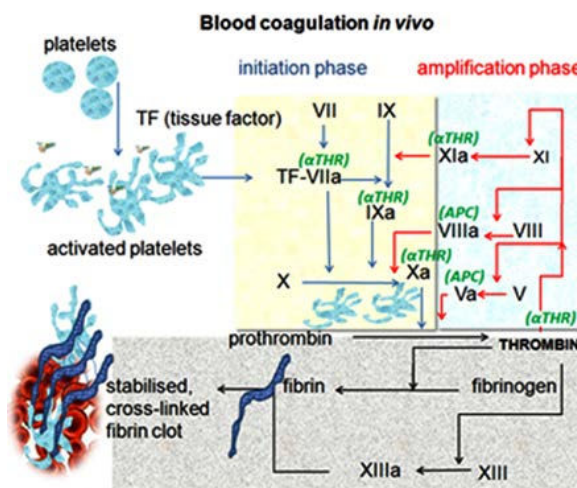
DIC is an independent and a reliable predictor of multiorgan failure in critically ill obstetrics. Till date, whether postpartum hemorrhage is the cause of DIC or the mechanism of DIC associated obstetric organ failure is not clear. Excessive and uncontrolled in-vivo thrombin generation is a major cause in the development of DIC.<sup>5</sup>



In this case, due to home delivery, the patient had an increased risk of sepsis. During sepsis, the coagulation system can be activated by leukocytes, platelets, inflammatory mediators and coagulation proteins participating in the processes leading to uncontrolled activation of coagulation cascade and DIC.<sup>6</sup> These cells release pro-inflammatory cytokines such as tumor necrosis factor-α (TNF-α), interleukin-1 (IL-1) and interleukin - 6 (IL-6), along with propagation of tissue factor (TF) expression on the surface of endothelial cell and leukocytes.<sup>7,8</sup> This can initiate an uncontrolled activation of the coagulation cascade via the TF/factor VIIa pathway leading to thrombin generation, and if this coagulation response is uncontrolled, it will lead to DIC.

The management of postpartum hemorrhage is focused on resuscitation of the patient while identifying and treating the specific cause.<sup>9</sup>

Maintenance of the hemodynamic stability of the patient is important to ensure continued perfusion to vital organs. Intravenous (IV) access should be obtained promptly.



<b>H</b>	Ask for <b>H</b> elp and <b>h</b> ands on uterus(uterine massage)
<b>A</b>	<b>A</b> ssess ( <b>A</b> BC) and resuscitate (crystalloids 2 L, colloids 1 L, oxygen by mask (15 L/min))
<b>E</b>	<b>E</b> stablish aetiology (atonic, traumatic, coagulopathy or trauma), <b>e</b> nsure availability of blood and administer <b>e</b> cbolics (drugs that contract the uterus – oxytocin, ergometrine or syntometrine intramuscularly)
<b>M</b>	<b>M</b> assage uterus
<b>O</b>	<b>O</b> xytocin infusion/prostaglandins – IV/IM/per rectal (second-line medications to contract the uterus)
<b>S</b>	<b>S</b> hift to theatre – aortic pressure or anti-shock garment/bimanual compression as appropriate
<b>T</b>	<b>T</b> amponade balloons/uterine packing – after exclusion of <b>t</b> issue and <b>t</b> rauma
<b>A</b>	<b>A</b> pply compression sutures – B-Lynch/ modified
<b>S</b>	<b>S</b> ystematic pelvic devascularisation – uterine/ovarian/quadruple/internal iliac
<b>I</b>	<b>I</b> nterventional radiology and, if appropriate uterine artery embolisation
<b>S</b>	<b>S</b> ubtotal/total abdominal hysterectomy

(PPH management, CREDIT: Google Image, William's Obstetrics Handbook)

If the PPH is due to uterine atony, treatment modalities include medical management with uterotonic agents, uterine tamponade, pelvic artery embolization, and lastly surgical management.<sup>9</sup>

DIC should be corrected promptly with blood transfusion, replacement of plasma products (coagulation factors) and platelets. Other supportive measures like antibiotic use, fluid resuscitation must be judiciously with close monitoring of the renal output. In this case, the patient was treated with plasma concentrates, blood transfusion and antibiotics, PPH was controlled by hysterectomy. Psychiatric support was done for the patient and her husband (with family) with the importance of adoption care. Knowledge and importance about the antepartum care regarding the proper check-up, vaccination, medications, was given to the family was given.

## CONCLUSION

DIC is a rare cause of PPH (0.2-0.5% population), mostly due to uterine atony. Uterotonic medications are used for preventing uterine atony during the parturition stage. Replacement of the decreased coagulation (blood) products must

be done promptly, and is the treatment of DIC. Proper antepartum health checkup stays the most important factor for preventing major obstetrics complications during peripartum.

## REFERENCES

1. Oliveira MI, da Costa VS, Mer S, Osório J, Martins AP. Thrombocytopenia in pregnancy, a challenge in the intensive care unit (ICU). *Rev Esp Anesthesiol Reanim (Engl Ed)*. 2019 Aug-Sep;66(7):385-389.
2. Alemu FM, Fuchs MC, Martin Vitale T, Abdalla Mohamed Salih M. Severe maternal morbidity (near-miss) and its correlates in the world's newest nation: South Sudan. *Int J Womens Health*. 2019;11:177-190.
3. Levi M, de Jonge E, van der Poll T, Ten Cate H. Advances in the understanding of the pathogenetic pathways of disseminated intravascular coagulation result in more insight in the clinical picture and better management strategies. *Semin Thromb Hemost*. 2001;27:569-575. doi: 10.1055/s-2001-18862.
4. Franchini M, Lippi G, Manzato F. Recent acquisitions in the pathophysiology, diagnosis and treatment of disseminated intravascular coagulation. *Thromb J*. 2006;4:4. doi: 10.1186/1477-9560-4-4.
5. Thachil J, Toh CH. Current concepts in the management of disseminated intravascular coagulation. *Thromb Res*. 2012;129 (Suppl 1):S54-9. doi: 10.1016/S0049-3848(12)70017-8.
6. Anas AA, Wiersinga WJ, de Vos AF, van der Poll T. Recent insights into the pathogenesis of bacterial sepsis. *Neth J Med*. 2010;68:147-152.
7. Erez O, Gotsch F, Mazaki-Tovi S, et al. Evidence of maternal platelet activation, excessive thrombin generation, and high amniotic fluid tissue factor immunore activity and functional activity in patients with fetal death. *J Mater Fetal Neonatal Med*. 2009;22:672-687. doi: 10.1080/14767050902853117.
8. Takai H, Kondoh E, Sato Y, Kakui K, Tatsumi K, Konishi I. Disseminated intravascular coagulation as the presenting sign of gastric cancer during pregnancy. *J Obstet Gynaecol Res*. 2011;37:1717-1719. doi: 10.1111/j.1447-0756.2011.01561.x.
9. Maswime S, Buchmann E. A systematic review of maternal near miss and mortality due to postpartum hemorrhage. *Int J Gynaecol Obstet*. 2017 Apr;137(1):1-7.