

Original Research Article

A Clinicopathological Spectrum of Soft Tissue Tumors in a Tertiary Care Centre with Emphasis on Role of Immunohistochemistry in Diagnosis of Soft Tissue Tumors

Vibhuti Goyal¹, Ranjan Agrawal², Bharat Chand Choudhary³

¹Assistant Professor, ²Professor, ³Professor and Head, Department of Pathology, Rohilkhand Medical College and Hospital, Bareilly, Uttar Pradesh 243006, India.

Corresponding Author:

Vibhuti Goyal, Assistant Professor, Department of Pathology, Rohilkhand Medical College and Hospital, Bareilly, Uttar Pradesh 243006, India.

E-mail: goyal.vibhuti@yahoo.com

Received on 24.07.2019,

Accepted on 21.08.2019

Abstract

Background: Soft tissue tumors (STTs) are a complex group of neoplasms and composed of nonepithelial supportive connective tissue. They are rare neoplasms, comprising $\leq 2\%$ of cases. Due to variable origin and overlapping histopathological features, they pose a great diagnostic challenge to histopathologists. **Aim:** To analyze the relative frequency of STTs in Rohilkhand region according to their nature and demographic profile and also to discuss the role of immunohistochemistry (IHC) in diagnosing and classification of STTs. **Materials and Methods:** The study included a total of 240 cases of STTs diagnosed at pathology department for a period of 2 years, at a tertiary care teaching hospital of Rohilkhand region. On H&E sections, tumors were classified on the basis of their origin according to WHO classification 2013. Sections were also subjected to IHC analysis using different antibodies, where indicated. **Result:** Out of the total 240 cases, 214 (89.2%) cases were benign, 8 (3.3%) intermediate and 18 (7.5%) malignant. Incidence of both benign and malignant STTs was more common in males. The peak incidence of benign STTs was observed in the age groups of 21-40yrs and that of malignant tumors in 41-60 yrs. Lipoma was the commonest benign STT (46.7%), while tumors of fibroblastic origin were most common (33.3%) among the malignant category. Few common benign tumors were also identified at rare sites. Out of 18 malignant cases, in 2 (11.1%) cases, no definite opinion could be obtained and were classified as spindle cell sarcomas. **Conclusion:** Diagnosis of STTs require uses of special stains, immunohistochemistry and molecular methods in addition to the routine microscopic examination of H & E stained slides due to the morphologic similarities with each other and also with carcinomas.

Keywords: Carcinomas; Hematoxylin and Eosin; Immunohistochemistry; Sarcomas; Soft tissue; Tumors.

How to cite this article:

Vibhuti Goyal, Ranjan Agrawal, Bharat Chand Choudhary. A Clinicopathological Spectrum of Soft Tissue Tumors in a Tertiary Care Centre with Emphasis on Role of Immunohistochemistry in Diagnosis of Soft Tissue Tumors. Indian J Pathol Res Pract. 2019;8(5):679-685.



Introduction

Soft tissue tumors (STTs) are a complex group of tumors and composed of non-epithelial supportive connective tissue ie mesenchymal in origin. They are heterogenous group of tumors and usual approach to their classification is as per the cell lineage. The WHO classification¹ system divide these entities in to fibroblastic/myofibroblastic tissue, fibrohistiocytic, adipose tissue, smooth muscle, skeletal muscle, blood vessels, lymphatics, pericytic and nerve sheath tumors according to their cell of origin.

STTs are rare neoplasms comprising $\leq 2\%$ of cases². STTs are classified into benign, intermediate and malignant forms. Intermediate group is liable for a higher rate of local recurrence and low to moderate risk of metastasis.

STTs can be seen in any age group and can arise anywhere in the body. The most common locations are the extremities followed by the trunk, abdominal cavity and head & neck region³. Due to the wide variety of STTs and frequent overlap in their histopathological features, they extend the pathologists diagnostic ability to a limit.

Immunohistochemistry (IHC) plays an important role in the diagnosis of STTs. The first approach is to rule out a non-mesenchymal tumor and then define a cell lineage. IHC has greatly enhanced our capabilities to properly classify soft tissue tumors. Immunohistochemical evaluation must be employed in conjunction with the clinical picture and morphology and when necessary, other ancillary techniques such as molecular genetics and/or cytogenetics⁴.

The present study was conducted to evaluate the relative frequency of STTs according to their nature and demographic profile and also to assess the role of IHC in the diagnosis and classification of soft tissue tumors.

Materials and Methods

A prospective, observational and cross-sectional study was conducted in the department of Pathology at Rohilkhand Medical College &

Hospital, Bareilly. Institutional ethical committee clearance was taken.

All clinically suspected soft tissue tumor specimens sent for histopathological examination in the department of pathology of a tertiary care teaching hospital of Rohilkhand region, for a period of 2 years, from September 2016 to August 2018, were included in this study. A total of 240 cases were studied.

Inclusion criteria

All the cases, where soft tissue tumor was suspected, irrespective of their age, sex and site. Same patient with biopsies performed on different occasions was considered as single case only.

Exclusion criteria

Tumor like lesions, uterine and gastro-intestinal soft tissue tumors were not included in this study.

Detailed clinical data including age, sex and site of each patient was recorded. Informed consent was taken from all the patients. Specimens thus obtained were first grossly examined for their size, consistency, presence or absence of capsule and areas of haemorrhage, necrosis and calcification. Multiple sections were taken and processed and stained with routine Hematoxylin & Eosin. The sections were studied under light microscopy for features like the cell type, arrangement, cellular and nuclear pleomorphism and the number of mitotic figures per 10 high power field, necrosis and hemorrhage. IHC was done to confirm the diagnosis and classification of tumors when diagnosis was in dilemma on routine microscopy.

Results

A total of 240 cases of soft tissue tumors were included in the present study. Out of 240 cases, 214 (89.1%) cases were benign, 08 (3.4%) cases were intermediate and 18 (7.5%) cases were malignant (Table 1). Among all the soft tissue tumors, adipocytic tumors were the commonest in 108 (45.0%) followed by vascular tumors in 55 (22.9%) and nerve sheath tumors in 26 (10.8%) cases (Table 1).

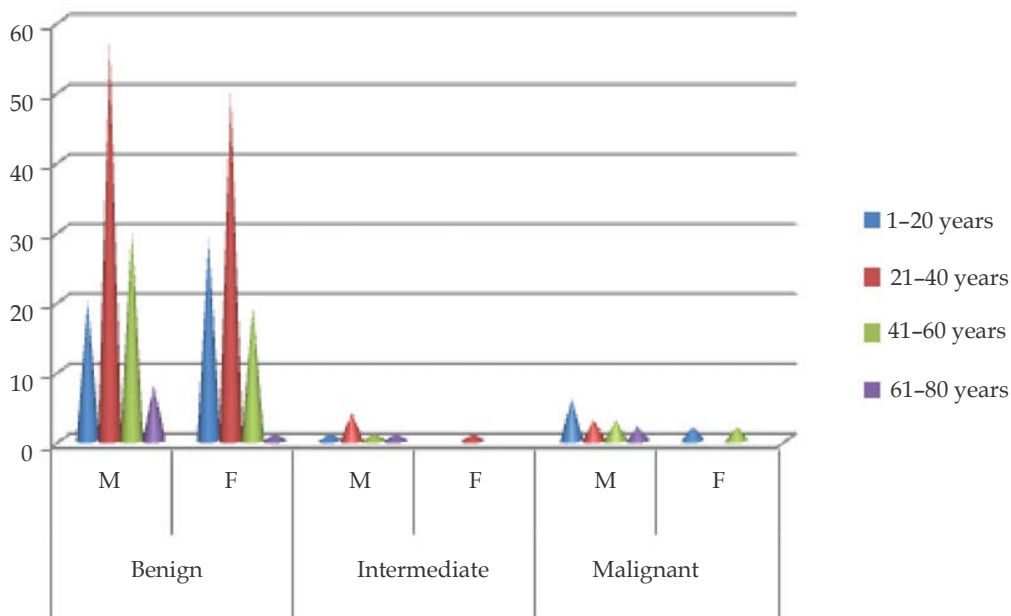
Table 1: Distribution of cases as per type and grade

Soft tissue tumors	Benign	Intermediate	Malignant	Total
Adipocytic tumors	106	01	01	108
Fibrohistiocytic tumors	04	03	02	09

Soft tissue tumors	Benign	Intermediate	Malignant	Total
Fibroblastic tumors	13	03	06	22
Nerve sheath tumors	25	00	01	26
Vascular tumors	55	00	00	55
Pericytic tumors	01	00	00	01
Smooth muscle tumors	07	00	02	09
Skeletal muscle tumors	00	00	02	02
Tumors of uncertain differentiation	03	01	04	08
Total cases (n)	214	08	18	240
(%)	(89.1%)	(3.4%)	(7.5%)	

Benign soft tissue tumors were common in the age group of 21–40 years while malignant soft tissue tumors showed two peaks, one in 1–20 years and the other in the 41–60 years age group

as depicted in Graph 1. Soft tissue tumors showed a male dominance, of these 136 (56.6%) were male and 104 (43.3%) were female with male to female ratio 1.3:1 (Graph 1).



Graph 1: Age & sex wise distribution of cases

The most common location of soft tissue tumors were extremities (48.7%) followed by head and

neck (35.8%), shoulder and back (18.7%), trunk and abdomen (10.8%) and others (2.5%) (Table 2).

Table 2: Distribution of Soft tissue tumors according to site

Site	Benign	Intermediate	Malignant	Total
Extremity	103	04	10	117
Head & neck	85	-	01	86
Shoulder & back	40	02	03	45
Trunk & abdomen	20	02	04	26
Others	06	-	-	06
Total	214	08	18	240

S TTs were then divided on the basis of their histological subtypes. Among benign soft tissue tumors, lipoma was the commonest (46.7%) entity, followed by capillary hemangioma (18.6%). Among intermediate S TTs, solitary fibrous tumor (37.5%)

and dermatofibrosarcoma protuberance (37.5%) were the most common lesions. Among malignant sarcomas, fibroblastic tumors were the commonest (33.3%), including fibrosarcoma, myxofibrosarcoma and low grade fibromyxoid sarcomas (Table 3).

Table 3: Distribution of tumors

Soft tissue tumors category	Benign (No.)	Intermediate (No.)	Malignant (No.)
Adipocytic tumors	Lipoma (100)	Atypical lipomatous tumor (01)	Myxoid liposarcoma (01)
	Spindle cell lipoma (06)		
Fibroblastic tumors	Nodular fasciitis (08)	Solitary fibrous tumor (03)	Myxofibrosarcoma(01) Low grade fibromyxoid sarcoma (02) fibrosarcoma (03)
	Fibroma (03)		
	Angiofibroma (01)		
	Angiomyofibroblastoma (01)		
Fibrohistiocytic tumors	Giant cell tumor of tendon sheath (02)	Dermatofibrosarcoma protuberans (03)	Malignant fibrous histiocytoma (02)
	Benign fibrous histiocytoma (02)		
Smooth muscle tumors	Leiomyoma (06)		Leiomyosarcoma (02)
	Angioleiomyoma (01)		
Vascular tumors	Capillary Hemangioma (40)		
	Cavernous hemangioma (07)		
	Intramuscular hemangioma (02)		
	Epithelioid hemangioma (01)		
	Lymphangioma (05)		
Pericytic tumors	Glomus tumor (01)		
Nerve sheath tumors	Neurofibroma (13)		Low grade MPNST (01)
	Schwannoma (11)		
	Neuroma (01)		
Skeletal muscle tumors			Embryonal rhabdomyosarcoma (02)
Tumors of uncertain differentiation	Fibromyxoma (02)	Myoepithelioma (01)	Extra skeletal PNET (01)
	Intramuscular myxoma (01)		Clear cell sarcoma (01) Spindle cell tumor (02)

Discussion

Soft tissue tumors include a large variety of tumors having many similar histopathological features with minimal differences. The immunohistochemical identification of various cells and tissue has led to a more accurate diagnosis and classification of these tumors.

In the present study, benign S TTs were more common than malignant tumors with a ratio of about 11.8:1, similar to other studies done by Batra P *et al* who reported benign to malignant ratio as 8.2:1.⁵ Also S TTs were found more commonly in males, with M:F as 1.3:1 in our study which is comparable with studies of Beg S *et al*.⁶ while other studies showed an equal sex distribution.⁷

S TTs can arise in any age group. In our study benign tumors were common in the 21-40 years age group accounting for 50.0% cases correlating with the findings of Batra P *et al*. who found incidence as 61.80%.⁵ However, in the present study malignant tumors showed a dual peak, first in less than 20years and second in 41-60 year age group as compared to other studies which showed a peak incidence between 5th and 6th decade.³ The largest number of sarcomas was observed in the 41-60 years age group. Our study showed that soft tissue sarcomas are also known to occur in the younger age (<20 yrs) in our population as similar findings was observed by R Jha *et al* in their study on soft tissue sarcomas.⁸ We observed extremities to be the commonest site (48.7%), followed by head and neck (35.8%) and shoulder and back (18.7%).

These findings were in correlation with the studies of Batra *P et al.* and Jain *P et al.*^{5,9}

The most common benign tumor was lipoma (46.7%) followed by hemangioma (18.6%) which is comparable to the study by Jain *P et al.*⁹ In malignant tumors fibroblastic tumors were the commonest in our study, accounting for 33.3% cases of all soft tissue sarcomas with an average age of 45 years as compared to the other studies, which showed malignant fibrous histiocytoma and liposarcoma as the most common soft tissue sarcomas.¹⁰ Fibrosarcomas constituted an incidence of 16.6% of sarcomas as compared to Markhede *G et al.*, who found the incidence of fibrosarcomas as 5–10% of sarcomas.¹¹ This observation could be a chance observation and maybe because of ours being a tertiary care centre.

According to WHO classification, STTs also have an intermediate group which shows repeated local recurrences and low to moderate risk for metastasis. The incidence of intermediate tumors in our study was 3.3% which was comparable with the study of Navya *et al* who also found the incidence of intermediate tumors as 3.4%¹² while in a study done by Petersen *et al.*, the incidence was 11.4%.¹³

STTs are diagnostically challenging. Some diagnoses are evident on morphology, where the tumor is well differentiated. However, many STTs are seen microscopically as spindle cell, epithelioid cell, small round cell or pleomorphic tumors which can only provide a differential diagnosis, and then IHC becomes extremely useful.

The application of IHC falls into 3 main categories: Identification of rare/ "atypical" benign tumors, exclusion of non-sarcomatous neoplasms and classification of sarcomas. It is also used to support diagnosis of a rare tumour type and also support diagnosis when tumour arises in unusual location or age.¹⁴ There are some pitfalls also in IHC. Fibrous STTs are a group of spindle cell neoplasms, composed of fibroblast and myofibroblast. Most fibrous tumors including both benign and malignant, express vimentin, actin and variable coexpression of desmin, thus fibrous tumors are best distinguished by their morphology while the role of IHC in fibrous tumor is only to rule out non-fibrous tumor. We had a rare¹⁵ case of paratesticular low grade fibromyxoid sarcoma in a 14 years old male patient. Microscopy revealed bland spindle like fibroblastic cells and a whorled pattern along with collagen and myxoid areas. Pleomorphism and mitoses was present focally. On IHC, cells

were positive for vimentin (Fig. 2b). Low grade fibromyxoid sarcomas are rare and most common in trunk and upper extremity.¹⁶

Angiomyofibroblastoma is a rare benign tumor, occurring most commonly in the vulvovaginal region.¹⁷ In our study a 34 years old female patient presented with a swelling in the right perineal region since 4 years and was clinically diagnosed as a case of bartholin cyst. Grossly it was a well circumscribed mass. Microscopy revealed spindle cells with some hypercellular areas mainly around the blood vessels while few areas were hypocellular. IHC showed positivity for vimentin, desmin, ER, PR and weak positivity for CD34 (Fig. 1a). Based on this the diagnosis of angiomyofibroblastoma vulva was confirmed.

IHC is very useful in determining vascular lineage. Commonly used vascular markers are CD34, CD31 and Factor VIII. Hemangiomas were the second most common benign tumor preceded by lipoma in our study and the most common site was head and neck comparable to other studies.¹⁸

Nerve sheath tumors were the next after hemangiomas constituting an incidence of 11.6% among benign soft tissue tumors comparable to the studies of Navya *et al.* who found the incidence as 6.9%.¹² On IHC S-100 is a useful marker for nerve sheath tumors. The most common site was head and neck and upper extremity comparable to other studies¹⁸. However in our study we also had 1 rare case of intraoral schwannoma (Fig. 1b). The incidence of intraoral schwannoma is ~1%.¹⁹

Leiomyoma occurs in all age group. In the present study we had 1 case of vulval leiomyoma in a 38 year old female patient. This tumor showed positivity for vimentin and desmin (Fig. 1c). Extruterine leiomyomas are very rare.²⁰

In our study we also found 1 case of myoepithelioma in a 41 year old male patient, presenting with a swelling in the left forearm which was clinically diagnosed as neurofibroma. Grossly it was a yellow-brown and well circumscribed. Microscopy revealed sheets of epithelioid cells with vacuolated cytoplasm in fibrous and hyaline stroma. Nuclear atypia was mild. On IHC, tumor cells expressed CK, S-100, CD3, CD45, CD5 and vimentin (Fig. 1d). Negative results were noticed with CD30, CD56, CD10, tdt and TTF1. CD4, CD15 and CD19 were equivocal. Myoepithelioma or mixed tumor of soft tissue is a rare neoplasm.²¹ They are the tumors of uncertain differentiation and they have been included in the intermediate category as they are not malignant but can metastasise.

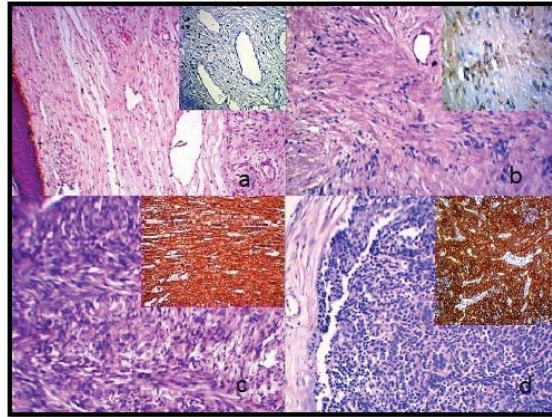


Fig. 1: (a) Angiomyofibroblastoma (H&E 100X) inset showing ER (IHC 100X), (b) Schwannoma (H&E 100X) inset showing S100 (IHC 100X), (c) Leiomyoma (H&E 100X) inset showing vimentin (IHC 100X), (d) Myoepithelioma (H&E 100X) inset showing CK (IHC 100X),

Only 3 cases of solitary fibrous tumor were observed in our study. One of them was found in tongue in a 35 year old male patient. Solitary fibrous tumors are rare STTs of intermediate category with unpredictable behavior.²² On IHC strong CD34 positivity was expressed in these tumors (Fig. 2a).

Extra skeletal Ewing's sarcoma is a rare STT and is more common in young adults less than 30 years of age with a male predominance.²³ In the present study we found a case of swelling in the paravertebral region in a young female. Microscopy showed tumor cells arranged in sheets with rosette formation at places. Tumor cells had high N:C and scanty cytoplasm. The

possibility of round cell tumor was considered. IHC was then extremely useful as CD99 showed strong membranous immunoreactivity and thus a diagnosis of extraskeletal Ewing's sarcoma/PNET was offered (Fig. 2c).

In our study we also found one rare case of congenital embryonal rhabdomyosarcoma in a 15 month old boy, presenting with a huge mass in the foot. Biopsy showed an infiltrating tumor composed of sheets and cords of malignant small round blue cells. The cells had scant eosinophilic cytoplasm and hyperchromatic nuclei. On IHC tumor cells showed strong positivity for desmin (Fig. 2d). Embryonal rhabdomyosarcoma is rare in the extremities.²⁴

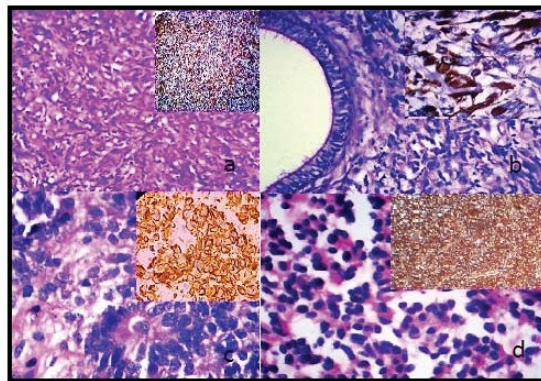


Fig. 2: (a) Solitary fibrous tumor (H&E 100X) inset showing CD34 (IHC100X), (b) Low grade fibromyxoid sarcoma (H&E 100X) inset showing vimentin (IHC 400X), (c) Extraskeletal PNET (H&E 400X) inset showing CD99 (IHC 400X), (d) Rhabdomyosarcoma (H&E 100X) inset showing desmin (IHC 100X),

Conclusion

The diagnosis of soft tissue tumors mainly sarcomas require uses of special stains,

immunohistochemistry and molecular methods in addition to the routine microscopic examination of Hematoxylin and Eosin stained slides because of the morphologic similarities with each other and

also with carcinomas. This study showed that an increase in the use of IHC has contributed to improve diagnostic accuracy. The use of progressively small amounts of tissue for diagnosis, highlights the importance of this method. The sensitivity and crispness of IHC stains have progressively improved with the advent of new techniques.

Conflicting Interest: No

References

1. Fletcher CDM, Unni K, Mertens K eds. Pathology and genetics of tumours of soft tissue and bone. Lyon, France: IARC Press; 2013:120. (World Health Organization Classification of Tumours; Vol 5).
2. Chakrabarti PR, Chakrabarti S, Pandit A, *et al.* Histopathological Study of Soft Tissue Tumors; A three year experience in tertiary care centre. *IJPO*. 2015;2(3):141-9.
3. Umarani MK, Prima SL, Bharathi M. Histopathological spectrum of Soft Tissue Tumors in a Teaching Hospital. *IOSR -JDMS*. 2015;14(4):74-80.
4. Gown MA, Folpe LA. Immunohistochemistry for analysis of soft tissue tumor. In Enzinger and Weiss' Soft tissue tumors. 5th Edition; China; Mosby Elsevier publications. 2008;129-74.
5. Batra P, Gupta DO, Batra R, *et al.* Pattern of Soft Tissue Tumors in a Rural Population of central India. *IJMHS*. 2013;3(3):124-6.
6. Beg S, Vasenwala SM, Haider N, *et al.* A comparison of cytological and histopathological findings and role of immunostains in the diagnosis of soft tissue tumors. *J Cytol*. 2012;29(2):125-30.
7. Myhre-Jensen O. A Consecutive 7-years series of 1331 benign soft tissue tumors. Clinicopathologic data. Comparison with sarcomas. *Acta Orthop Scand*. 1981;52(3):287-93.
8. R Jha. Difficulties in the diagnosis of soft tissue sarcomas. *Jiom*. 2010;32(2):26-9.
9. Jain P, Shrivastava A, Malik R. Clinicomorphological Assessment of Soft Tissue Tumors. *Sch J App Med Sci*. 2014; 2(2D):886-90.
10. Mack TM. Sarcomas and other malignancies of soft tissue, retroperitoneum, pleura, heart, mediastinum and spleen. *Cancer, (Supplement)*. 1995;75(21):1-41.
11. Markhede G, Angervall L, Stener B. A Multivariate analysis of prognosis after surgical treatment of malignant soft tissue tumor. *Cancer*. 1982;49(8):1721-33.
12. Narayana N, Sapna M, Sumangala B. Spectrum of soft tissue tumors in a tertiary care centre- A 5 year study. *Natl J Med Dent Res*. 2016;4(2):83-8.
13. Petersen I, Gunther B, Mildner K, *et al.* Update from the soft tumor registry in Jena. *Pathologe*. 2011;32(1):40-6.
14. Heim-Hall J, Yohe SL. Application of immunohistochemistry to soft tissue neoplasms. *Arch Pathol Lab Med*. 2008;132(3):476-89.
15. Sheela KM, Lailaraji N, Anitha Asokan C. Pleomorphic sarcoma in paratesticular region. *World J Pathol*. 2017;6:61-5.
16. Vernon SE, Bejarano PA. Low grade fibromyxoid sarcoma: A brief review. *Arch Pathol Lab Med*. 2006;130:1358-60.
17. Seo JW, Lee KA, Yoon NR, *et al.* Angiomyofibroblastoma of the vulva. *Obstet Gynecol Sci*. 2013;56(5):349-51.
18. Vahini G. A Clinicopathological Study of Soft Tissue Tumors in Correlation with Immunohistochemistry. *IOSR - JDMS*. 2015;14(1):31-40.
19. Aswath N, Maningandan T, Sankari SL, *et al.* A rare case of palatal schwannoma with literature review. *J Oral Maxillofac Pathol*. 2019;23:36-9.
20. Amudha P, Kalarani E, Karthikadevi A, *et al.* Vulval leiomyoma: a rare clinical entity. *Int J Reprod Contracept Obstet Gynecol*. 2016;5(4):1254-56.
21. Colombat M, Lesourd A, Moughabghab M, *et al.* Soft tissue myoepithelioma, a rare tumor. A case report. *Ann Pathol*. 2003;23(1):55-8.
22. Vafiadou M, Dimitrakopoulos I, Georgitzikis I, *et al.* Solitary fibrous tumor of the tongue: A case report and literature review. *Int J Oral maxillofac Sur*. 2008;37(11):1067-69.
23. Sharma C, Nath K, Kumawat BL, *et al.* Paraspinal extraskeletal Ewing's Sarcoma: a rare clinical entity. *BMJ Case Rep*. 2014 May 22;2014. pii: bcr2014205010.
24. Shrutha SP, Vinit GB. Rhabdomyosarcoma in a Pediatric Patient: a rare case report. *Contemp Clin dent*. 2015;6(1):113-15.