

Original Research Article

Uterine Leiomyoma : A Clinicopathological Study in Hysterectomy Specimen

VD Dafle¹, DN Kokode², SV Jagtap³, SS More⁴^{1,2}Assistant Professor, ⁴Professor and Head, Department of Pathology, DY Patil Medical College, Kolhapur, Maharashtra 416006, India. ³Professor, Department of Pathology, Krishna Institute of Medical Sciences, Karad, Maharashtra 415539, India.

Corresponding Author:

DN Kokode, Assistant Professor,
Department of Pathology, DY Patil Medical
College, Kolhapur, Maharashtra 416006, India.E-mail: virendradafle@gmail.com

Received on 20.05.2019,

Accepted on 11.07.2019

Abstract

Introduction: The leiomyomas are common benign tumors in uterus. It is composed of proliferation of smooth muscle cells and fibrous connective tissue. The various interactions of sex steroid hormones and local growth hormones are important for development of these tumors. Also genetic cause related to mutations in the normal myometrium is considered as the other etiological factor. **Aims and Objectives:** To study and analyse various histopathological patterns of uterine leiomyomas in surgically excised hysterectomy specimens. **Material and Methods:** The present study was done at the Department of Pathology, DY Patil, Medical College, Kolhapur, Maharashtra, India, for the period of three years from Jan 2016 to December 2018. **Results:** A total of 116 surgically excised hysterectomy specimens which were clinically and radiologically suspected of uterine leiomyomas were studied. The maximum numbers of patients in this study were between 41-50 years (46.5%). The clinical sign and symptoms of menorrhagia being the most common indication for hysterectomy. The intramural location was common site of leiomyomas in this study. **Conclusion:** We observed in female reproductive tract uterine leiomyomas are the most common tumors. Most of the cases were asymptomatic. The intramural location was common site of leiomyomas in this study.

Keywords: Hysterectomy; Leiomyoma; Menorrhagia

How to cite this article:

VD Dafle, DN Kokode, SV Jagtap *et al.* Uterine Leiomyoma : A Clinicopathological Study in Hysterectomy Specimen. Indian J Pathol Res Pract. 2019;8(4):502-506.

Introduction

The leiomyomas are commonest benign tumor in female. These are commonly called as fibroid uterus. It is composed of proliferation of smooth muscle cells and fibrous connective tissue in various

proportion forming well circumscribed tumors.

Leiomyomas are related to hormonal influence which are studied by molecular basis that they have more estrogen receptors than normal myometrium [1]. The long standing estrogenic effect manifests as hyperplasia in the development of leiomyomas [2].



This work is licensed under a Creative Commons
Attribution-NonCommercial-ShareAlike 4.0.

The leiomyomas are oestrogen- and progesterone-dependent tumors. These are more noted in oral contraceptive user and at reproductive life. Also noted that, after menopause tumors may regress in size rapidly. The etiopathogenesis of uterine fibroids remain unclear and multifactorial [3]. Symptoms of fibroids are abnormal uterine bleeding, pelvic pain, dyspareunia, urinary and gastrointestinal compression effects. In few cases it is related to cause of infertility. The size of leiomyoma is not related to its clinical symptoms [4]. The development of severe anaemia may be observed in cases of neglected severe vaginal blood loss [5]. The various surgical modalities are in the form of hysterectomy or myomectomy. The surgical intervention is depends on the size, localization, number and extent of leiomyoma. Also the patient’s status of fertility will determine the appropriate treatment modality [6]. Surgical treatment takes the form of hysterectomy or myomectomy, the choice depending on the size, number and extent of fibroids, and on the patient’s wishes with regard to fertility [7,8,9].

Aims and Objectives

To study and analyse various histopathological features within uterine leiomyomas in surgically excised hysterectomy specimens.

Materials and Methods

The present study was conducted in the Department of Pathology, DY Patil, Medical College, Kolhapur, Maharashtra, India. Study duration over a period of three years from Jan 2016 to December 2018.

A total of 116 surgically excised hysterectomy specimens which were clinically and radiologically suspected of uterine leiomyomas were examined. The clinical data was retrieved from patients case record files. The age, parity, sign and symptoms, systemic manifestations, radiological and supporting investigations findings were noted for diagnosis. All the surgical specimen received were fixed in 10% neutral buffered formalin for 24–48 hours. A detailed gross examination of uterus, cervix with or without bilateral adnexae were carried out. On cut open the well circumscribed, firm, grey to tan lesions with whorled appearance was considered as leiomyoma. The details related to tumor location, number and secondary changes were noted. The sections al from tumor along two sections from cervix, endomyometrium and one section each of fallopian tubes and ovaries were taken for histopathological study.

The additional sections from abnormal areas were also taken. Routine histopathological processing was done. Paraffin embedded tissue blocks were sectioned and stained with hematoxylin eosin stain. A complete microscopic histopathological examination related to endometrium, stromal changes, myometrium were noted. The leiomyoma, its pattern, any secondary changes were noted. Fallopian tubal and ovarian findings were noted. The final histopathological diagnosis was given. Any other associated pathological findings were noted.

Results

The total of 116 hysterectomy specimens with uterine leiomyomas were studied, out of which 89 (76.7%) were abdominal hysterectomy with bilateral salphingo-opharectomy specimens, remaining 27 (23.3%) were only hysterectomy specimens as shown in Table 1.

Patients with leiomyomas were aged between 2nd and 5th decade of life. The youngest was 26 years and oldest was 64 years. The majority were multiparous women (112 cases 9). 4 cases were nulliparous women (Table 2 & 3). In 55.5% cases the menorrhagia was the commonest clinical manifestation noted in this study, followed by pain in abdomen in 30 cases), dysmenorrhea in 13.5%, and retention of urine in 1% cases (Table 4).

Most of the uterus showed intramural leiomyomas accounting for 54 cases and subserosal, submucosal in one or more than one location (Table 5).

Table 1: Type of Hysterectomy

Sr. No.	Type of Hysterectomy	Number	Percentage
1	Abdominal hysterectomy with bilateral salphingo-ophorectomy specimens	89	76.7%
2	Only hysterectomy specimens	27	23.3%
Total		116	100%

Table 2: Age wise distribution of patients with leiomyoma

Sr. No.	Age in years	Number	Percentage
1	20–30	03	02.58
2	31–40	48	41.37
3	41–50	54	46.55%
4	51–60	06	05.17
5	> 60	05	04.31
Total		116	100

Table 3: Parity of patients with Leiomyoma

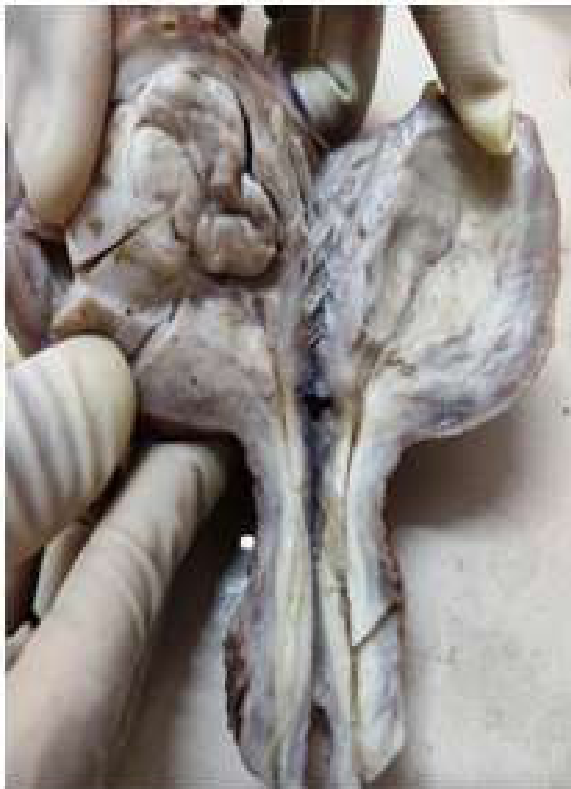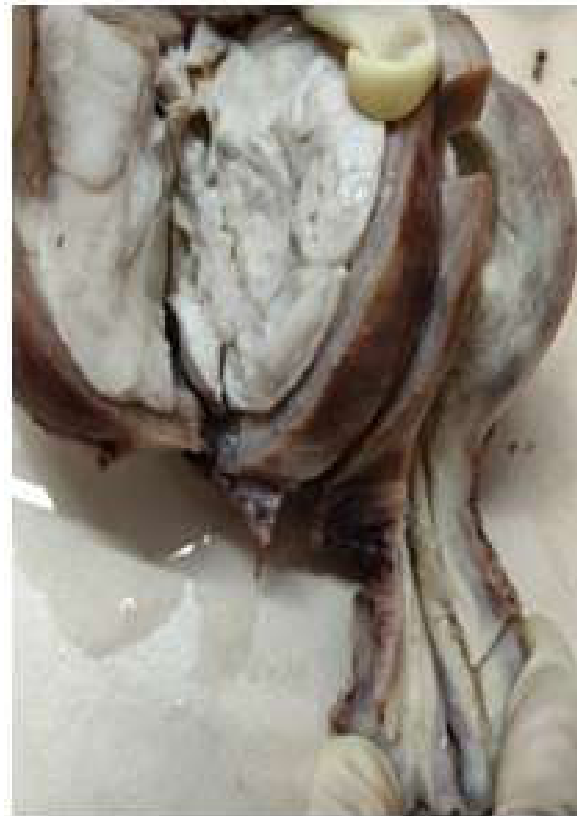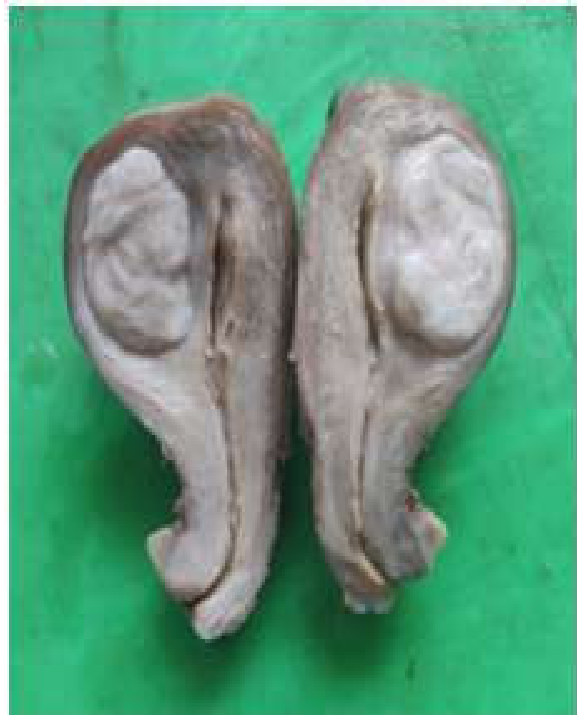Sr. No.	Parity	Number	Percentage
1	Nulliparous	3	2.5 %
2	Primipara	01	0.9 %
3	Multipara	112	96.6 %
	Total	116	100

Table 4: Clinical manifestation in patients with leiomyoma

Sr. No.	Clinical manifestations	Number	Percentage
1	Menorrhagia	64	55.5 %
2	Pain abdomen	35	30 %
3	Dysmenorrhea	16	13.5 %
4	Retention of urine	01	1 %
	Total	116	100

Table 5: Location of leiomyomas in hysterectomy specimen

Sr. No.	Location of leiomyomas	Number	Percentage
1	Intramural	54	46.5 %
2	Subserosal	21	18.1 %
3	Submucosal	03	2.5 %
4	More than one location	38	32.9 %
	Total	116	100 %

**Fig. 1:** Uterus cutopen showing intramural location of tumor-leiomyoma**Fig. 2:** Cut section of tumor grey white, circumscribed intramural location**Fig. 3:** Cut section of tumor grey white, circumscribed intramural location

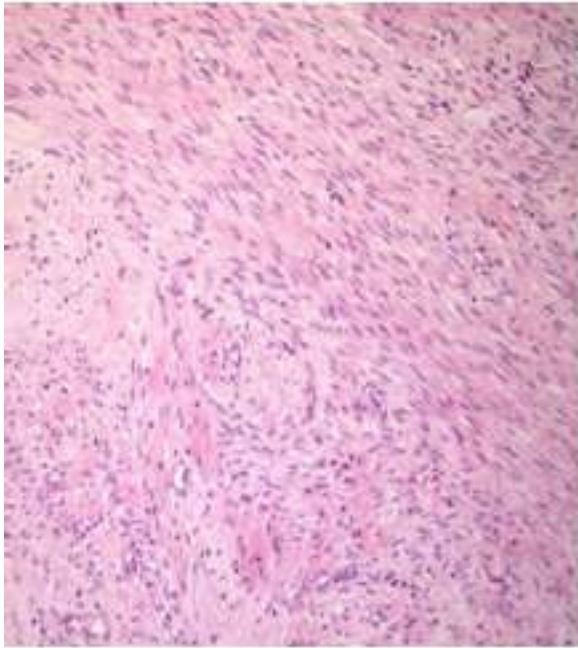


Fig. 4: On microscopic examination tumor cells arranged in sheaths, bundles, whorled pattern etc (H&E Stain, 100x)

Discussion

Uterine leiomyomas are also called myomata or fibroids. These are the most common gynecologic tumors all over the world. The prevalence of leiomyomas is high in women in developing country. These tumors arise in any part of the uterus. The major gynaecological surgery done throughout the world is hysterectomy. The subtotal and total hysterectomy was first done in Manchester, England in 1843 and 1929 was respectively by Charles Clay [10]. The hysterectomy is a successful procedure to symptomatic relief, cure and disease free life.

The hysterectomies are indicated in various conditions like like leiomyoma, dysfunction uterine bleeding, adenomyosis etc. Long standing pelvic inflammatory disease, endometriosis, pelvic organ prolapse which account for major indication for hysterectomies. Neoplastic cervical, endometrial, tubal and ovarian masses are another indications. Among these benign lesion leiomyoma followed by adenomyosis are the commonest indication for hysterectomy.

The maximum number of patients in this study were in between 41-50 years (46.5%). These findings were similar to that observed by Gupta *et al.* (51.40%), Rather *et al.* (47.27%) [11, 13]. In other studies, 31-40 years age group was mainly affected like in study by Gowri *et al.* (41.3%) [14]. In this study, menorrhagia was the commonest presenting symptom seen in

55.5% cases, followed pain in abdomen in 30% cases. The location of leiomyoma gives various clinical manifestations usually intramural type remains asymptomatic or with pelvic pain, while submucous type cause p/v bleeding, may interfere with conception, or gives PID.

In the present study, out of 116 cases of leiomyomas, (67.1%) were single and (32.9%) were multiple. In a study by Rather (35.43%), Gowri (49.03%) as a single location [13,14]. The study by Sarfraz *et al* showed multiple site leiomyomas in 60.87% cases [15]. Abraham and Saldanha observed solitary leiomyoma in 42.5% cases and multiple leiomyomas in 57.5% [16]. Uterine leiomyomas are usually well circumscribed, firm, spherical masses of variable sizes. On microscopic examination tumor cells rare elongated, spindle-shaped, with a cigar-shaped nucleus. Tumor cells are arranged in sheaths, bundles, whorled pattern etc. (Fig. 4). These cells are uniform in size and shape, with occasional mitoses. There may be seen are bizarre (atypical), cellular and secondary changes. The variety of histologic subtypes of leiomyomas are Epithelioid, Myxoid, Cellular, Atypical, plexiform, vascular and lipoleiomyoma are noted [17].

The location of leiomyoma is mostly uterine, rarely at extrauterine site. The most common site of leiomyomas in our study was intramural (46.5%) (Figs. 1,2,3), followed by subserosal leiomyomas (18.1%) and sub mucosal leiomyomas (2.5%). Jung *et al.* observed intramural fibroids in 55.7% cases, subserous fibroids in 16.3% cases, 15.6%, and submucosal fibroids in 12.4% cases respectively [18]. Intramural leiomyomas were also the commonest types in studies by Gowri *et al.* (48%) [14]. Abraham and Saldanha observed intramural fibroids in 61.5% cases, subserosal leiomyomas in 9% cases and submucosal leiomyomas in 5% cases [16]. Rare site for extrauterine leiomyoma at broad ligament have been reported [19]. In pregnancy related leiomyoma shows rapid growth, changes of red degeneration and chances of spontaneous miscarriage. It is observed that secondary changes such as hyaline degeneration, mucoid degeneration, cystic changes, and fatty changes are seen mostly with intramural leiomyoma [20]. Overall prognosis is good in treated cases. Very few cases show malignant change. The histopathological study is essential to diagnose various leiomyoma and will be helpful for patient care.

Conclusion

We observed in female reproductive tract uterine

leiomyomas are the most common tumors. Most of the cases were asymptomatic. The intramural location was common site of leiomyomas in this study. The histopathological evaluation is important to diagnose various leiomyoma.

References

1. Wu X, Serna VA, Thomas J, *et al.* Subtype-Specific Tumor-Associated Fibroblasts Contribute to the Pathogenesis of Uterine Leiomyoma. *Cancer Res* 2017;77:6891–01.
2. Abraham R. Manual of clinical problems in Obstet Gynaecol. 4th ed. Uterine fibroids; 1994. pp.227–9.
3. Abdulla LS. Hysterectomy: A clinicopathological correlation, Bahrain Medical Bulletin. 2006 June; 28(2):1–6.
4. Ackerman, Gull B, Karlsson B, Milsom I, Granberg S. Factors associated with endometrial thickness and uterine size in random sample of postmenopausal women. *Am J Obstet Gynecol* 2001 Aug;185(2): 386–91.
5. Rosai J, editor. 9th ed. Vol. 2. Missouri: Elsevier; Female reproductive system. In: Rosai and Ackerman's Surgical Pathology; 2004. pp.1603–8.
6. Gull B, Karlsson B, Milsom I, Granberg S. Factors associated with endometrial thickness and uterine size in a random sample of postmenopausal women. *Am J Obstet Gynecol*. 2001;185:386–91.
7. Zimmermann A, Bernuit D, Gerlinger C, *et al.* Prevalence, symptoms and management of uterine fibroids: an international internet-based survey of 21,746 women. *BMC Womens Health*. 2012;12:6. 10.1186/1472-6874-12-6.
8. Donnez J, Dolmans M. Uterine fibroid management: from the present to the future. *Hum Reprod Update*. 2016;22(6):665–86.
9. Ashraf T. Management of uterine leiomyoma. *J Coll Physicians Surg Pak*. 1997;7:160–62.
10. Nausheen F, Iqbal J, Bhatti FA, Khan AT, Sheikh S. Hysterectomy. The patient's perspective. *Annal Gynecol*. 2004;10:339–41.
11. Gupta S, Manyonda I. Hysterectomy for benign gynaecological diseases. *Curr Obstet Gynaecol*. 2006;16:147–53.
12. Rani SV, Thomas S. Leiomyoma, a major cause of abnormal uterine bleeding. *J Evol Med Dent Sci*. 2013;2:2626–30.
13. Rather GR, Gupta Y, Bardhwaj S. Patterns of Lesions in Hysterectomy Specimens: A Prospective Study. *JK Science*. 2013;15(2):63–8.
14. Gowri M, Mala G, Murthy S, Nayak V. Clinicopathological study of uterine leiomyomas in hysterectomy specimens. *J Evol Med Dent Sci*. 2013;46(2):9002–9.
15. Sarfraz T, Tariq H. Histopathological findings in menorrhagia - a study of 100 hysterectomy specimens. *Pak J Pathol*. 2005;16(3):83–5.
16. Abraham J, Saldanha P. Morphological variants and secondary changes in uterine leiomyomas – Is it important to recognise them? *Int J Biomed Res*. 2013;4:639–45.
17. Jung JK, Koi MS, Jung BW, Lee HH, Choi HJ, Shin SK. A clinical analysis of uterine myoma. *Korean J Obstet Gynecol*. 1998;41(1):210–9.
18. Jagtap SV, Phalke A, Kshirsagar NS, Jagtap SS, Nasre N. Uterine Lipoleiomyoma: a rare variant of benign uterine neoplasm. *Int J Reprod Contracept Obstet Gynecol* 2019;8:2553–5.
19. Jagtap SV, Khatib WGM, Jagtap SS, Kshirsagar NS. Large leiomyoma of the broad ligament. *Journal of Medical & Allied Sciences*, 2013;3(2), 85–88.
20. Lahori M, Malhotra AS, Sakul, Khajuria A, Goswami KC. *Int J Reprod Contracept Obstet Gynecol*. 2016; 5(7):2295–99.