

## Accessory Piriformis Muscle: Anatomical Variant & it's Clinical Imolications

<sup>1</sup>Suganitha Balasundaram, <sup>2</sup>Priya Ranganath, <sup>3</sup>Sumathi S, <sup>4</sup>Latha J

### How to cite this article:

Suganitha Balasundaram, Priya Ranganath, Sumathi S et. al./Accessory Piriformis Muscle: Anatomical Variant & it's Clinical Imolications/Indian J Anat. 2022;11(2):49-51.

**Author's Affiliation:** <sup>1</sup>Tutor, <sup>2</sup>Professor and Head, <sup>3</sup>Associate Professor and Head, Department of Anatomy, Medical College and Research Institute, Bangalore, Karnataka 560034, India, <sup>4</sup>Guest Lecturer, Department of Physiotherapy, UCA College of Physiotherapy, Chennai, Tamil Nadu 600031, India.

**Corresponding Author:** Suganitha Balasundaram, Tutor, Department of Anatomy, Medical College and Research Institute, Bangalore, Karnataka 560034, India.

**E-mail:** snithabala@gmail.com

**Received on:** 19.05.2022

**Accepted on:** 15.06.2022

### Abstract

The piriformis muscle originates from the anterior part of sacrum and inserts into the greater trochanter. Then it passes transversely through the greater sciatic foramen via the sciatic notch and inserts on the greater trochanter. It is one of the lateral rotator muscle of the hip & an important land mark in the gluteal region. Since the sciatic nerve descends to the thigh by passing deeper to the piriformis muscles, it is mostly associated with the irritation of nerve which is known as piriformis

syndrome. In this study the accessory piriformis muscle was observed in a 59 year-old female cadaver. The abnormality reported in the present study may lead to neurovascular compression syndrome in the upper limb. Knowledge of anatomical variations in the muscular structure and its related neurovascular entrapment is important surgically for orthopaedic surgeons, neurologists and also physiotherapists clinically.

**Keywords:** Accessory Piriformis Muscle, Piriformis Muscle, Piriformis Syndrome, Pseudo Sciatica, Sciatic Nerve Entrapment.

### Introduction

Piriformis muscle is one of the lateral rotators of the hip. It originates from the anterior part of the sacrum between the sacral foramen by digitations, then it passes transversely through the greater sciatic foramen via sciatic notch, and it inserts on the greater trochanter.<sup>1</sup> the pyramidal shaped piriformis muscle almost covers the foramen.

The neurovascular bundle related above to the muscle is superior gluteal nerve & vessels. The neurovascular bundle related below to the muscle

is sciatic nerve, inferior gluteal vessels and nerve and pudendal nerve and vessels.<sup>1</sup>

Since the proximal part of sciatic nerve is covered by a trunk of piriformis muscle, compression or inflammation of the proximal part of sciatic nerve within this muscle is called as piriformis syndrome. Rarely, accessory fibres of piriformis muscles are also present in some cases which is an most important factor to increase the percentage of entrapment of sciatic nerve.

Hence the present study was done to observe the



anatomical variation in the gluteal region related with sciatic nerve.

### Materials & Method

The study was conducted on 30 lower limbs from embalmed cadavers in the Department of Anatomy, Bangalore Medical college & Research Institute, Bangalore. After reflecting the gluteus maximus muscle, the deeper layers of muscles were exposed including piriformis. Photographs were taken for proper documentation and ready reference.

### Results

In 30 specimens (96.6%), the piriformis was present as a single trunk with 4 cm thickness in the middle trunk. Interestingly in one specimen (3.34%) another trunk of muscle, the accessory piriformis, was noticed immediately below the main trunk of piriformis. The thickness of the accessory muscle was 2.5 cm in the middle. The sciatic nerve was passing deeper to these two trunks of muscles. The accessory head was also inserted immediately 1mm below the piriformis over the greater trochanter. The course of all other neurovascular structures were normal. Other gluteal and neurovascular

structures were normal.

### Discussion

Many authors<sup>2,3,5</sup> have observed accessory piriformis muscle located inferior to the proper muscle. Belly of the accessory muscle was crossing under the trunk of the n. ischiadicus. Since the main trunk or branches of the nerve is not piercing the muscle but passing between the muscle bellies, this makes this topographical relationship an unclassified variation according to Benson's classification. Belly of the accessory muscle was thick and mostly tendinous. Direction of the fibers was not similar to the proper muscle which makes the case different from previously reported muscle slips, double or three-bellied variations.

Ravindranath et al<sup>4</sup> have reported three cadaver cases of accessory piriformis muscle originating from the sacrotuberous ligament or the fascia overlying the gluteus medius. Accessory slips of these cases merged with the main tendinous part of piriformis muscles. However, the sciatic nerve was deeply related to the accessory slip and the main piriformis muscle.

Natsis et al<sup>6</sup> reported an extremely rare cadaver

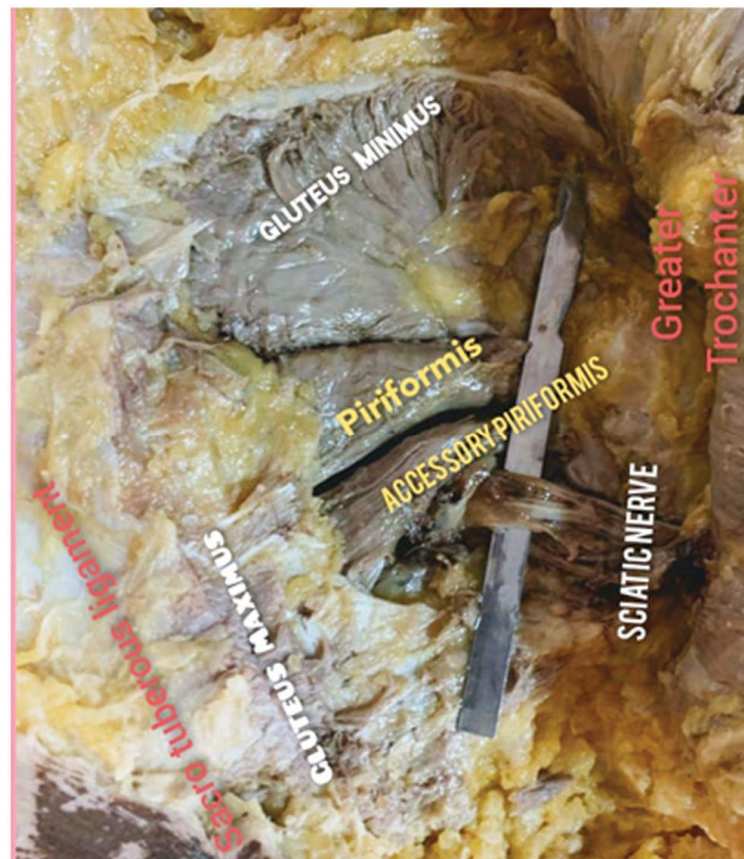


Fig. 7: Shows the anatomical variant of Accessory piriformis and it's relation with the Sciatic nerve

case of anatomical variation, showing that the piriformis muscle has three muscle bellies. Unlike other cases described previously, their patient had an accessory belly of the piriformis muscle which originated at the inferior aspect and the proximal third portion of the main piriformis muscle coursed deep to the sciatic nerve, and attached separately into the greater trochanter.

Beaton and Anson<sup>3</sup> classified possible anatomical relationships between sciatic nerve and piriformis muscle into six types. However, only a few cases of anatomic variation of the piriformis muscle have been reported as a cause of piriformis syndrome, especially regarding the accessory piriformis muscle.<sup>7</sup>

The present study was different from that of Beaton and Anson classification.

### Conclusion

Recent study stated that the accessory trunk of piriformis muscles was present immediately below the main trunk of piriformis muscle which also covered the upper part of sciatic nerve. It is very important clinically for those suffering with low back pain radiating down to the leg the abnormality reported in the present study may lead to neurovascular compression syndrome in the lower limb. Knowledge of anatomical variations in the muscular structure and its related neurovascular entrapment is important surgically for orthopaedic surgeons, neurologists, and also physiotherapists clinically. Therefore, the knowledge about this kind of rare variations are important for surgeons to

avoid mislead diagnosis and treatment.

### Acknowledgement

My sincere thanks to Dr. Anju Paul and I MBBS students for their valuable help and support.

### References

1. Standring S, Ellis H, Wigley C. Gray's Anatomy: The Anatomical Basis of Clinical Practice. New York, Elsevier Churchill Livingstone, 2005
2. Sen A, Rajesh S. Accessory piriformis muscle: an easily identifiable cause of piriformis syndrome on magnetic resonance imaging. *Neurol India* 2011;59:769-771
3. Polesello GC, Queiroz MC, Linhares JPT, Amaral DT, Ono NK. Anatomical variation of piriformis muscle as a cause of deep gluteal pain: diagnosis using MR neurography and treatment. *Rev Bras Ortop* 2013;48:114-117
4. Ravindranath V, Manjunath KY, Ravindranath R. Accessory origin of the piriformis muscle. *Singapore Med J* 2008;49 :17-218
5. Yeoman W. The relation of arthritis of the sacroiliac joint to sciatica, with an analysis of 100 cases. *Lancet* 1928;2:1119-1122
6. Natsis K, Totlis T, Konstantinidis GA, Paraskevas G, Piagkou M, Koebeke J. Anatomical variations between the sciatic nerve and the piriformis muscle: a contribution to surgical anatomy in piriformis syndrome. *SurgRadiolAnat* 2014;36:273-280
7. Lee EY, Margherita AJ, Gierada DS, Narra VR. MRI of piriformis syndrome. *AJR Am J Roentgenol* 2004;183:63- 64.8. Sedatdeveli, Faithyazar, Accessory piriformis muscle., *Cukurova Medical Journal* 2017;42(1):182-183

