

Bilateral Synchronous Breast Cancer: A Case Report based on Rare Presentation

Yusuf Malik¹, Jayant Pratap Singh², Vividha Dubey³, Saurabh Karnawat⁴, Virender Bhandari⁵

Author's Affiliation: ^{1,2,3}Registrar, ⁴Assistant Professor, ⁵Professor & Head, Department of Radiation Oncology, Sri Aurobindo Medical College and PG Institute, Indore, Madhya Pradesh 453555, India.

Corresponding Author: Virender Bhandari, Professor and Head, Department of Radiation Oncology, Sri Aurobindo Medical College and PG Institute, Indore, Madhya Pradesh 453555, India.

Email: virencancer@yahoo.co.in

How to cite this article:

Yusuf Malik, Jayant Pratap Singh, Vividha Dubey et al./ Bilateral Synchronous Breast Cancer: A Case Report based on Rare Presentation./ Indian J Canc Educ Res 2021;9(1):47-50.

Abstract

Bilateral Breast Carcinoma (BBC) is rare in itself with synchronous carcinoma having incidence of only 2-5% of all breast cancers, which is quite less than metachronous carcinoma. Synchronicity/metachronicity are typically associated with local and lymphatic spread and with hematogenous spread to lungs, bones and liver. Furthermore, BBC are mostly lobular carcinomas, but we report a case of 44-year-old female who presented with lump in left breast since 8-9 months and eruptions in bilateral breast since 20-25 days. Trucut biopsy was done which revealed Mucinous carcinoma in left breast and Infiltrating ductal carcinoma in right breast. Patients are usually treated with bilateral mastectomy but in our case, patient presented with advanced disease so we planned for neoadjuvant chemotherapy first.

Keywords: Bilateral Breast Cancer; Mucinous Carcinoma; Rare Presentation

Introduction

Bilateral breast cancer is not a rare entity now, as there is increased long term survival in patients due to better management and prognosis¹. Predisposing factors for bilateral breast cancer are young age, family history, lobular carcinoma, multicentric disease, histologic differentiation, parity and PR positive status. Bilateral breast cancer may be synchronous (1-2%) or metachronous (5-8%)². Understanding these factors contributing in the development of contralateral tumour is important to improve its changed clinical course, exaggerated treatment course and expense, aggravated prognosis in contrast with unilateral tumour³.

Case Report

A 44-year-old female presented to us with multiple

grape like eruptions over bilateral breast since 20-25 days (Fig.1). Patient had initial complaints of lump in left breast 8-9 months back which gradually increased in size associated with intermittent pain which was pricking in nature.

There was no significant past medical or family history. On clinical examination there was palpable lump in left breast central quadrant approx. 10x10 cm not fixed to chest wall with bullous lesions over skin. Palpable lump in right breast in central quadrant 7x8 cm fixed to skin with grape like lesions and peau d' orange appearance. Axillary lymph nodes were not palpable bilaterally. Left side supraclavicular node was palpable approx. 2x3 cm soft to firm in consistency.



This work is licensed under a Creative Commons Attribution-NonCommercial-ShareAlike 4.0.

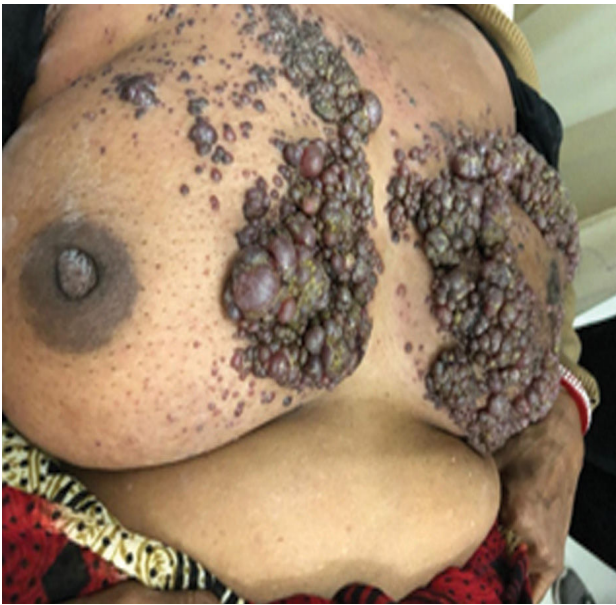

Fig. 1: Lump in both breast with skin lesions

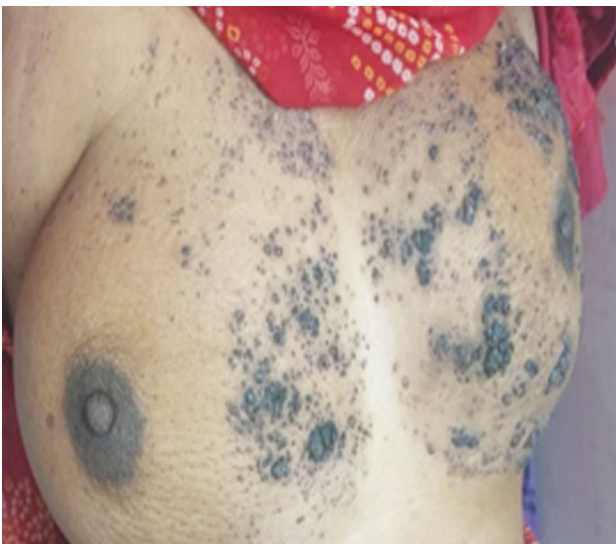

Fig. 2: Post Chemotherapy results

Mammography revealed 63x45 mm soft tissue lesion in left breast upper outer quadrant with irregular margins with no axillary lymphadenopathy - BIRADS III.

Cytology Reportsuggestive of Duct Carcinoma Breast

Trucut biopsy from Left breast reveal edabundant mucin material, infiltrating stroma with occasional small clusters of atypical cells having high N:C ratio, hyperchromatic nuclei - Suggestive of Mucinous carcinoma (Fig. 4) and from Right breast showed round to polygonal cells with high N:C ratio, hyperchromatic nuclei, eosinophilic cytoplasm, forming tubules infiltrating fibrous stroma - Suggestive of Infiltrating ductal carcinoma (Fig. 3).

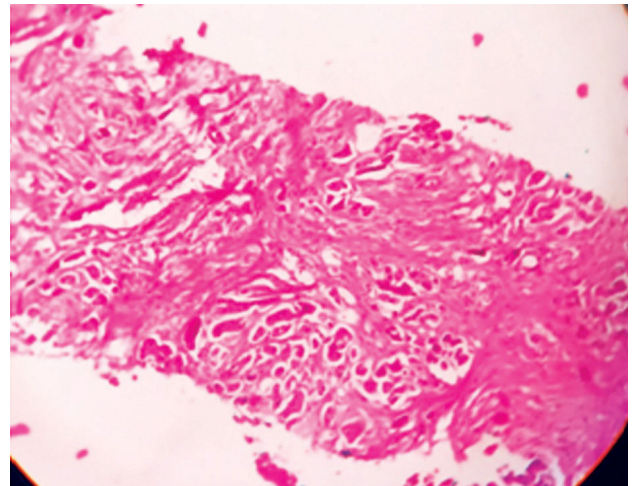


Fig.3: Right breast HPE

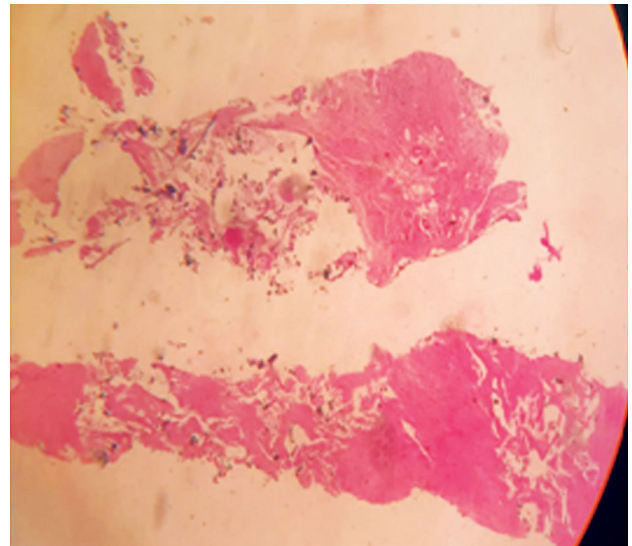


Fig.4: Left Breast HPE


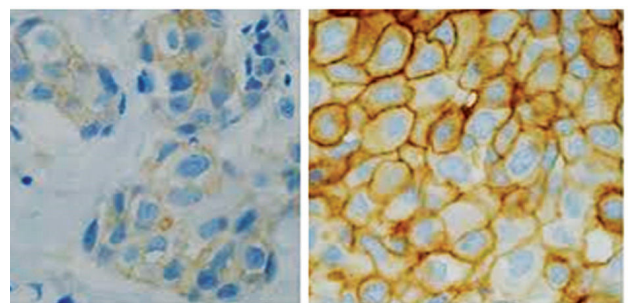


Fig. 5: IHC (both breast)

Skin biopsy from Right breast which microscopically revealed dilated spaces containing tumour lobule in superficial dermis; composed of cuboidal to round cells with high N:C ratio, hyperchromatic nuclei, eosinophilic cytoplasm; suggestive of metastatic carcinoma- skin.

Immunohistochemistry revealed ER/PR negative and HER2/NEU positive status in both breasts.

Patient was taken for neoadjuvant chemotherapy. Patient received 4 cycles of FEC (5 fluorouracil, epirubicin, cyclophosphamide) and then 2 cycles of paclitaxel. There was significant reduction in size of lump and skin lesions also subsided (Fig. 2).

However patient then defaulted to treatment and was lost to follow up.

Discussion

Bilateral breast carcinoma is not an uncommon entity with an incidence of 2-5% of all breast malignancies (Chandrika et al.).

The second tumour in contralateral breast can be six months (within six months of primary tumour) or metachronous (after six months of primary tumour).

Women previously diagnosed with breast cancer are at increased risk of developing contralateral breast cancer with 2-6 times greater relative risk⁴.

Risk factors associated with bilateral breast cancer are: familial or hereditary breast cancer, young age at primary breast cancer diagnosis, lobular invasive carcinoma, multicentricity, radiation exposure, histologic differentiation of primary tumour, parity and PR positive status^{2,3}.

One challenge in management of breast cancer is identifying whether second tumour is an independent event or metastasis from the index tumour. A criteria has been proposed by Chaudary et al. in 1984 for diagnosis for second primary breast cancer it is as follows

1. There must be in situ change in the contralateral tumour
2. The tumour in the second breast is histologically different from the cancer in the first breast
3. The degree of histological differentiation of the tumour in the second breast is distinctly greater than that of the lesion in the first breast.
4. There is no evidence of local, regional or distant metastases from the cancer in the ipsilateral breast.

Despite new methods such as cDNA microarray based comparative genomic hybridization, Chaudary's criteria is most widely accepted method to distinguish second primary lesion from metastatic lesion⁵.

We reported a case of bilateral breast cancer in which rare entity i.e. mucinous breast carcinoma was found in one breast and the most common entity i.e. infiltrating ductal carcinoma (IDC) was found in second breast. IDC accounts for 65-80% of invasive breast lesions⁶. Mucinous breast carcinoma has been observed in old women with relatively long duration of symptoms. It accounts for 2% of all breast cancers. Mucinous breast cancer carries a favourable prognosis with low frequency of lymph node metastasis and low rate of recurrence. The 5-year DFS rate ranges from 81% to 94% but in our department patient presented with locally advanced lesion with clinically palpable left supraclavicular node.

The origin of mucinous breast cancer is multifactorial and involves diet, reproductive factors and hormones. The definitive diagnosis and classification of mucinous breast cancer are based on histopathological examination.

Mucinous carcinoma is positive for oestrogen and progesterone receptor while androgen receptors are expressed at a low level and HER2 is not amplified and also expresses predominantly MUC2 and MUC6 among the family of MUC genes⁷.

A circumscribed margin in mammography would favour the diagnosis of pure mucinous carcinoma but tissue biopsy is mandatory in evaluation of mucinous breast carcinoma.

The treatment of mucinous breast carcinoma is usually surgery followed by post-operative hormone therapy in hormone responsive tumours. For bilateral breast cancer also, treatment is usually bilateral breast conservation or mastectomy. There is no reported relation between ER and PR status and bilaterality of the tumour. But Her2 Neu overexpression is more commonly seen in bilateral breast cancers. Synchronous breast carcinoma is having a poorer prognosis than metachronous breast carcinoma⁸. Our case was locally advanced with bullous lesion over skin with palpable supraclavicular node thus neoadjuvant chemotherapy was planned initially followed by further line of management.

Conclusion

Conscientious diagnosis and apt management help to ameliorate longevity and improved quality of life.

References

1. Naveen Padmanabhan, Ann apurneswari Subramanyan, Selvi Radhakrishna. Synchronous Bilateral Breast Cancers. *Journal of Clinical and Diagnostic Research*. 2015 Sep, Vol-9(9): XC05-XC08.
2. Sharad Goyal, Thomas Buchholz, Bruce G. Haffty. Breast Cancer: Early Stage. In: Edward C. Halperin, David E. Wazer, Carlos A. Perez and Luther W. Brady. *Principles and Practice of Radiation Oncology seventh edition*. Wolter Kluwer; 2019; p1331
3. Bhushan Anil Shah, Nagendra Yadav, Kandarpa Akhil, Firoz Alam. A rare case report of bilateral synchronous carcinoma breast. *International Surgery Journal* | September 2017 | Vol 4 | Issue 9 Page 3153.
4. Vijay Kumar Shankarrao Kappikeri, and Akshay Mahesh Kriplani. Bilateral synchronous carcinoma breast- a rare case presentation. *SpringerPlus* (2015) 4:193.
5. Soo Jung Gong, Sun Young Rha, HeiCheulJeung, Jae Kyung Roh, Woo Ick Yang and Hyun Cheol Chung. Bilateral Breast Cancer: Differential Diagnosis Using Histological and Biological Parameters. *Jpn J Clin Oncol* 2007;37(7):487-492.
6. Singla A, Kaur N, Walia DS, Singla D. Bilateral metachronous breast carcinoma: A rare case report. *Int J App Basic Med Res* 2018;8:126-8.
7. Limaie F, Ahmad F. Mucinous Breast Carcinoma. [Updated 2020 Oct 16]. In: *StatPearls* [Internet]. Treasure Island (FL): StatPearls Publishing; 2020 Jan. Available from: <https://www.ncbi.nlm.nih.gov/books/NBK538334/>
8. Kheirleiseid EA, Jumustafa H, Miller N, Curran C, Sweeney K, Malone C, McLaughlin R, Newell J, Kerin MJ (2011) Bilateral breast cancer: analysis of incidence, outcome, survival and disease characteristics. *Breast Cancer Res Treat* 126(1):131-140