

Prognostic Value of CD44s Expression in Oral Squamous Cell Carcinoma

Dvijendra Nath¹, Boki Yuto², Pallavi Agarwal³

¹Professor and Head, ²Junior Resident, ³Associate Professor, Department of Pathology, M.L.B. Medical College, Jhansi, Uttar Pradesh 284001, India

Abstract

Introduction: Aim of the study is to assess the CD44s expression in oral squamous cell carcinoma and its correlation with various histomorphological grades of the tumor and its prognostic significance. **Material and Method:** 42 Cases of Oral squamous cell carcinoma were included in the study. Histological grading of tumor was done on Haematoxylin and eosin stained tissue sections. Immunohistochemical study was done with CD44s antigen Marker. The histomorphological grades of tumors were correlated with CD44s expression based on degree of intensity and distribution of CD44s immunostaining. Correlation was evaluated statistically using Yate's Chi Square test. **Result and Conclusion:** The study showed decrease in the intensity of CD44s expression with increase in tumor grade. This suggests that CD44 plays an important role in cell-cell and cell-matrix interaction and helps in cell adhesion, which decreases with increasing cancer stage. Thus it can be concluded that CD44s expression can be useful in evaluating the tumor progression and be of value in predicting the prognosis of the disease.

Keywords: CD44s; Oral squamous cell carcinoma; Cell adhesion.

Corresponding Author:

Boki Yuto, Junior Resident, Department of Pathology, M.L.B. Medical College, Uttar Pradesh 284001, Jhansi, India.

E-mail: ashapurohit54@gmail.com

Received on 23.03.2019,

Accepted on 04.05.2019

How to cite this article:

Dvijendra Nath, Boki Yuto, Pallavi Agarwal. Prognostic Value of CD44s Expression in Oral Squamous Cell Carcinoma. Indian J Pathol Res Pract. 2019;8(4):425-429.

Introduction

Oral cancer is one of the most common causes of cancer deaths in many countries. It has a heavy toll on global public health because of the functional impairment and high mortality rate [1]. Oral squamous cell carcinoma accounts for more than 90 percent of all Oral malignancies [2]. The cluster of differentiation CD44s is a trans-membrane cell adhesion molecule [3]. It binds with hyaluronan,

extracellular matrix and growth factor, thus help in cell-cell adhesion and cell-matrix interaction. Aberration of these adhesion molecules is important in tumorigenesis as well as tumor progression [4]. Many studies suggest close relation between CD44s expression and metastasis in various tumors, but such evidence is inconclusive in oral squamous cell carcinomas [5,6]. In oral squamous cell carcinoma, majority of the patients presents in late stages of the disease [7,8]. This is the main reason for increased



morbidity and mortality. Prognosis of the disease is much better in patients who receive treatment early stage of the disease. The 5 years survival is as high as 90 percent in such cases. The purpose of this study was to evaluate the correlation of CD44s expression with histomorphological grades of the tumor and evaluate if it could be of value in the diagnosis and prognostic evaluation in oral squamous cell carcinoma.

Material and Method

A total of 42 cases of oral squamous cell carcinomas diagnosed in department of Pathology, MLB Medical College, Jhansi were included in the study. Paraffin blocks of these cases stored in the department archives were taken and two sets of tissue sections cut at 5 microns thickness were prepared on polylysine-coated glass slides. One set sections prepared were stained histopathological evaluation using Haematoxylin and eosin stains. The lesions were categorized into well differentiated, moderately differentiated and poorly differentiated squamous cell carcinomas, CD44s Staining and evaluation of was done by ready to use CD 44 std./HCAM Ab 4 [156-3C11] supplied by THERMO Scientific. The sections were kept in hot plate overnight for heat fixation. Sections were deparaffinised using xylene and hydrated. Antigen retrieval was done by microwave treatment, slides were washed three times with PBS solution and than peroxide block was added for 15 min in moist chamber, slides were again washed with PBS solution three times, Next power block was added and incubated for 15 minutes in moist chamber. Primary antigen was applied for 60 minutes at room temperature and washed in PBS solution. Secondary antigen was applied for 30 minutes and washed with PBS solution and DAB chromogen was added for two minutes, and finally the sections were counter stained with haematoxylin and mounted with DPX. The most representative areas were selected for evaluating the intensity of CD44s expression.

IHC interpretation: Cytoplasmic staining was taken as positive. Based on the degree of positive staining they were graded as negative, mild, moderate and maximum intensity. The intensity of CD44s expression were then correlated with histomorphological grades of the tumor.

Statistical analysis: Yate's Chi Square Test was performed to analyze the correlation of the tests carried out. p value was 0.000862 (p value < 0.005 is significant).

Results

Expression of CD 44 was found in 92.85% (39/42) Oral Squamous Cell Carcinoma cases and Negative in 3 cases (7.15%).

Table 1: Presence of CD 44 in epithelium of Oral Squamous Cell Carcinoma.

S. No.	Result	Oral squamous cell carcinoma	
		No.	%
1	Absent	3	7.15%
2	Present	39	92.85%

Table 2: Differentiation based distribution of CD44 expression in Squamous cell carcinoma cases studied.

Tumour grade	CD44 Intensity							
	-		+		++		+++	
	No.	%	No.	%	No.	%	No.	%
Well differentiated (20)	0	0	1	5%	6	30%	13	65%
Moderately differentiated (15)	0	0	2	13.3%	9	60%	4	26.7%
Poorly differentiated (7)	3	42.8%	4	57.2%	0	0	0	0
-	Negative							
+	Mild Staining							
++	Moderate staining							
+++	Maximal staining							

No expression of CD44 was seen in 42% (3/7) of cases in poorly differentiated OSCC. No negative cases were recorded in well differentiated or Moderately Differentiated OSCC.

Mild intensity of CD44 Expression was seen in 57.2% (4/7) of Cases in poorly differentiated OSCC, 13.3% (2/15) of cases in moderately differentiated OSCC and 5% (1/20) of cases in well differentiated OSCC.

Moderate intensity of CD44 expression was seen in 30% (6/20) of cases in well differentiated OSCC, 60% (9/15) of cases in moderately differentiated carcinoma and none of the poorly differentiated OSCC.

Maximal Intensity of CD44s Expression was seen in 65% (13/20) of cases in well differentiated OSCC, 26.7% (4/15) cases in moderately differentiated OSCC and none of the poorly differentiated OSCC. Intensity of CD44 expression decreased with increasing tumor grade, most of well differentiated OSCC showing maximum intensity while poorly differentiated OSCC were either negative or showed mild immunoreactivity.

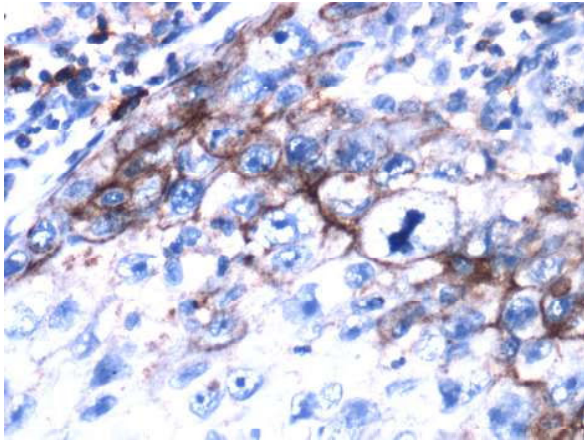


Fig. 1: CD44 expression in moderately differentiated SCC

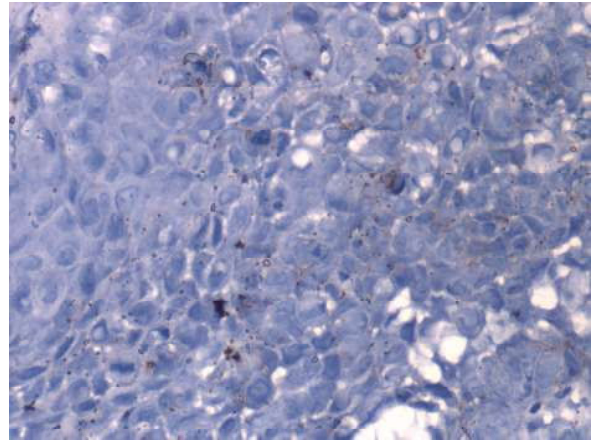


Fig. 2: CD44 expression in poorly differentiated SCC.

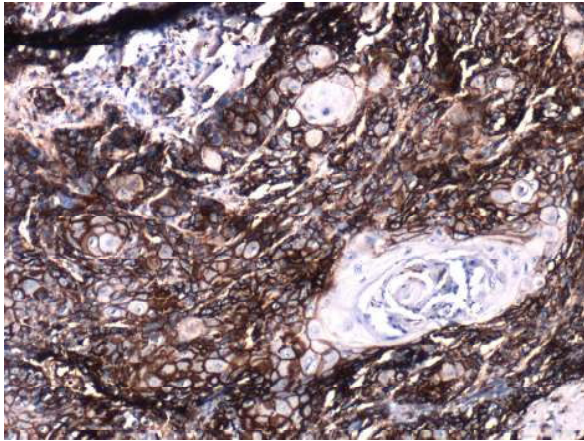


Fig. 3: CD44 expression in well differentiated SCC.

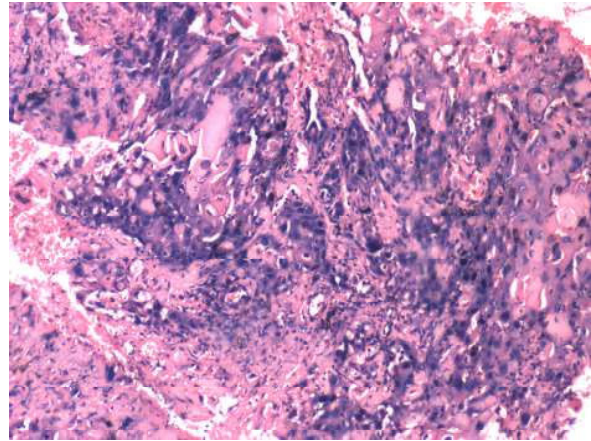


Fig. 4: H & E stained section (40X): moderately differentiated SCC

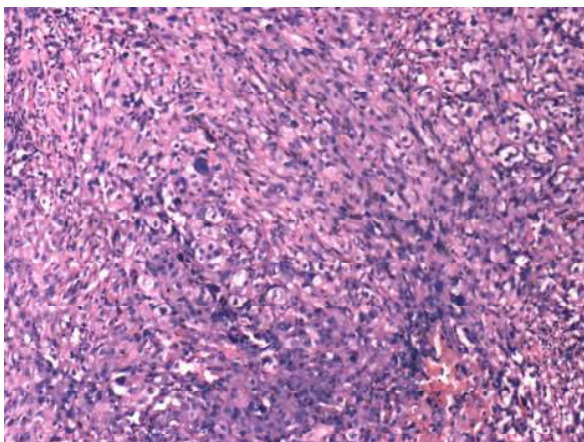


Fig. 5: H & E stained Section (10X): poorly differentiated SCC.

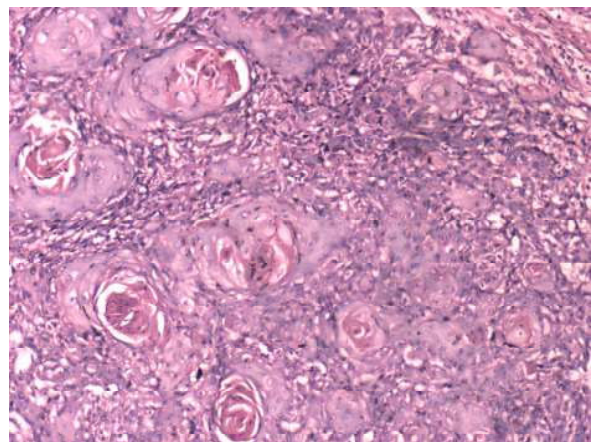


Fig. 6: H & E stained section (10X): Well differentiated SCC

Discussion

Oral cancer is one of the ten most common cancers in the world, in India it is the 3rd most common cancer, accounting for about 30% all malignancies [9]. Squamous cell carcinomas accounts for over 90 percent of all oral malignancies. The mean age of diagnosis of oral cancer is 65 Years [10]. In a study from Eastern India, mean age was 52.07 years. The peak incidence of Oral squamous cell carcinoma in our study was found to be in the 5th and 6th decade of life, 61.9% of our cases belonged in this age group. The frequency of Oral cancer in India is at least a decade earlier than that described in the western literature [10]. Epidemiological study of oral cancer in India by Chattopadhyay *et al.* and Mathew *et al.* gave similar reports that in developing countries, oral cancer may affect younger men and women more frequently than seen in the western world. The same holds true for population in Bundelkhand region because of rampant use of Tobacco and its products. Tobacco and Alcohol are two most common precipitating factors.

The cluster of differentiation 44 (CD44) is a transmembrane cell adhesion molecule involved in cell-to-cell and cell-to matrix interactions by binding with hyaluronan, extracellular matrix proteins, and growth factors. CD44 is thought to undergo structural and functional alterations during malignant transformation, which lends the cancer cells to detach from the site of tumor growth and invade the surrounding tissues [11].

CD44 expression was seen in 92.85% of the case and only 7.25% showed negative CD44 expression. This was in agreement with observations made by Christiana Simionscu, CL. Margatitescu *et al.*, 2008. Again, Srilalitha Kaza, Lalith P.C. Kantheti *et al.*, 2018 observed similar result of CD44 expression in OSCC [12].

In the present study the intensity of CD44 decreased with increase in tumor grade (Table XX). In well differentiated OSCC (65%) of the cases showed maximum intensity, 30% showed moderate intensity and only 5% showed negative or minimal intensity. In moderately differentiated OSCC 26.7% case showed maximum intensity, 60% case showed moderate intensity and 13.3% cases were either negative or minimal intensity. And in poorly differentiated OSCC, 57.2% cases showed minimal intensity, and 42.8% of the cases showed no immunoreactivity for CD44.

Srilalitha Kaza, Lalith P.C. Kantheti *et al.*, 2018, observed similar results; $69.42 \pm 14.55\%$ positive in well differentiated OSCC, $34.9 \pm 7.84\%$ in

moderately differentiated OSCC, and only $10.88 \pm 3.44\%$ in poorly differentiated OSCC. Christiana Simionscu, CL. Margatitescu *et al.*, 2008 too in their study observed that most of the cases showing loss of immunoreactivity to CD44 belonged to poorly differentiated OSCC [13].

The above finding including ours indicated that the loss of cell adhesion is correlated to the decrease of CD44 expression which can be used as prognostic indicator in the evolution of OSCC.

Over the years, most studies of CD44 expression in OSCC have demonstrated some prognostic value. Reduced expression of CD44 was a significant predictor of poor prognosis.

Carinci F, Stabellini M *et al.*, 2002, and Garcia M Peria, Val-Bermal JF *et al.*, 2005, also made similar observations. On the other hand Kokko LL, Hurme S *et al.*, 2011, and Joshua B, Kaplan MJ *et al.*, 2012 observed that strong expression of CD44 is associated with poor prognosis of OSCC.

These variability in results may due to lack of standardization in research on this subject particularly in relation to the anatomical region of the lesion. There is significant difference in CD44 expression and its prognostic influence according to anatomical location of SCC in head and neck region [14].

Gonzalez-Moles MA, Gil Montoya *et al.* 2007 observed that the low expression of CD44s on tumor cells was significantly correlated with poor prognosis in tongue carcinomas, whereas Bankfalvi *et al.* observed that loss of CD44 expression was associated with poorer prognosis in OSCC.

In our study out of 7 poorly differentiated OSCCs 3 were negative and 4 showed minimal CD44 expression while most of the well differentiated cases showed strong CD44 expression. Thus our study was in agreement with those studies that observed that loss of CD44 expression is associated with poorer prognosis.

Since our study constituted only 42 cases and long term follow up could not be done, the final outcome of the disease could not be determined. A bigger study group (more no. of cases) and long follow up of the cases studied is required to reach a definitive conclusion.

Conclusion

There are discrepancies in various literatures regarding the prognostic influence of CD44 expression in relation to OSCC. Many studies

have showed decrease in CD44s expression with increasing tumor grades while many other studies suggest strong CD44 expression in Higher Grade OSCC. Thus, standardized additional studies are needed to validate the CD44s molecule as a reliable biomarker of prognosis in OSCC.

However our study suggests an altered expression of CD44 in OSCC with weak immunostaining in poorly differentiated squamous cell carcinoma. It implies that the adhesive functions of CD44 in cell-cell and cell-matrix interactions are needed in the maintenance of the normal architecture of the epithelium. The downregulation of CD44 could pave way for the cells to detach and invade. Hence it could be used to determine the status of cancer progression, and thus be of value in predicting the prognosis of the disease.

References

1. Siegel R, Ma J, Zou Z, Jemal A. Cancer statistics, 2014. CA: a cancer journal for clinicians. 2014;64: 9-29.
2. Bray F, Sankila R, Ferlay J, Parkin DM. Estimates of cancer incidence and mortality in Europe in 1995. European journal of cancer (Oxford, England: 1990). 2002;38:99-166.
3. Lyon AJ, Jones J, *et al.* Cell adhesion molecules, the extracellular matrix and oral squamous cell carcinoma. International journal of oral maxillofacial surgery. 2007;38(8):671-679.
4. Luka Z, Dvorak K. Review of article adhesion molecules in biology and oncology. Acta Vet Brno. 2004;73:93-104.
5. Hudson DL, Speight PM, Watt FM. Altered expression of CD44 isoforms in squamous cell carcinoma and cell lines derived from them. International Journal of Cancers. 1996;66:457-63.
6. Hema KN, Rao K, Devi HU, Priya NS, Smitha T, Sheethal HS. Immunohistochemical study of CD44s expression in oral squamous cell carcinoma—Its correlation with prognostic parameters. J Oral Maxillofac Pathol. 2014;18:162-8.
7. Wenig B. 1st edition. Philadelphia: WB Saunders; 1993. Atlas of head and neck pathology; PP715-8.
8. Tytar M, Oloffson J. Prognostic factors in oral cavity carcinomas. Acta Otolaryngology. 1992;492 (suppl.):75-8.
9. Elano JK, Gangadharan P, Sumithra S, Kuriakose MA, Trends of head and neck cancers in Urban and Rural India. Asian pac J Cancer Preview. 2006 Jan-Mar;7(10):108-12.
10. Chattopadhyay A. Epidemiology study of oral cancer in eastern India. Indian J Dermatol. 1989;34:59-65.
11. Ziober BL, Silverman SS Jr, *et al.* Adhesive mechanisms regulating invasion and metastasis in oral cancer. Crit Rev Oral Biol Med. 2001;12(6):499-510.
12. Srilalitha Kaza, Lalith P.C Kantheti *et al.* study of CD44 adhesion molecule in oral squamous cell carcinoma and its correlation with tumor histological grade. 2018;10(1):42-49.
13. Satoa S, Miyasuchia M, Takekoshia T, Zhaoa M, Kudoa Y, Ogawab I, *et al.* Reduced expression of CD44 variant 9 is related to lymph node metastasis and poor survival in squamous cell carcinoma of tongue. Oral Oncol. 2000;36:545-9.
14. Kokko LL, Hurme S, Maula SM, Alanen K, Grénman R, *et al.* Significance of site-specific prognosis of cancer stem cell marker CD44 in head and neck squamous-cell carcinoma. Oral Oncol. 2011;47:510-516.