

## Comparative Study to Evaluate the Efficacy of Intrathecal Clonidine Versus Clonidine with Fentanyl in Laparoscopic Surgeries Under General Anaesthesia

Surekha C<sup>1</sup>, Nazneen Makhbool<sup>2</sup>, Anurita Konnur<sup>3</sup>

<sup>1</sup>Assistant Professor <sup>2</sup>Post Graduate Student <sup>3</sup>Assistant Professor, Department of Anaesthesiology, Bangalore Medical College and Research Institute, Bengaluru, Karnataka 560002, India.

### Abstract

**Background:** Laparoscopic surgeries are known to cause hemodynamic repercussions due to pneumoperitoneum despite being minimally invasive surgeries. Various studies have been conducted to minimize hemodynamic alterations in laparoscopic surgeries. **Aim:** The aim was to compare the efficacy of intrathecal clonidine versus intrathecal clonidine with fentanyl in maintaining hemodynamic stability and to assess postoperative analgesia in patients undergoing laparoscopic surgeries under general anesthesia. **Materials and Methods:** A randomized double-blind study was done in 60 patients of either sex, with American Society of Anesthesiologists Grade I and II, aged between 18 and 55, posted for laparoscopic surgeries. Group CL ( $n = 30$ ) received intrathecal clonidine 150 micrograms and Group CF ( $n = 30$ ) received intrathecal clonidine 75 micrograms followed by intrathecal fentanyl 25 micrograms before general anesthesia. Assessment parameters included hemodynamics, postoperative analgesia and sedation scores. **Results:** Intraoperative heart rate, systolic, diastolic and mean arterial blood pressures at intubation, pneumoperitoneum and extubation were significantly reduced in Group CL ( $p < 0.05$ ) when compared to Group CF. Mean duration of postoperative analgesia was significantly prolonged in Group CL ( $10.30 \pm 1.24$  hours,  $p < 0.001$ ) when compared to Group CF ( $5.53 \pm 1.11$  hours). Mean sedation score was significantly higher in Group CL ( $2.07 \pm 0.25$  versus  $1.90 \pm 0.31$ ;  $p = 0.025$ ). No adverse effects were recorded during study. **Conclusions:** Intrathecal clonidine 150 micrograms is highly effective in maintaining intraoperative hemodynamic stability during laparoscopic surgeries under general anesthesia along with prolonged postoperative analgesia in comparison to combination of intrathecal clonidine 75 micrograms with fentanyl 25 micrograms.

**Keywords:** Intrathecal Clonidine; Fentanyl; Hemodynamics; Analgesia.

### How to cite this article:

Surekha C, Nazneen Makhbool, Anurita Konnur. Comparative Study to Evaluate the Efficacy of Intrathecal Clonidine Versus Clonidine with Fentanyl in Laparoscopic Surgeries Under General Anaesthesia. India J Anesth Analg. 2020;7(1 Part -II):354-360.

### Introduction

Minimally invasive surgeries such as laparoscopic procedures offer the advantage of less trauma and shorter hospital stay to the patients. Laparoscopic

surgeries are usually performed by insufflation of gases like carbon dioxide into the abdominal cavity.<sup>1</sup>

However, the creation of pneumoperitoneum along with frequent change in patient positions

**Corresponding Author:** Nazneen Makhbool, Post Graduate Student, Department of Anaesthesiology, Bangalore Medical College and Research Institute, Bengaluru, Karnataka 560002, India.

**E-mail:** [singwduv@gmail.com](mailto:singwduv@gmail.com)

**Received on** 12.12.2019, **Accepted on** 16.01.2020



This work is licensed under a Creative Commons Attribution-NonCommercial-ShareAlike 4.0.

resulted in marked pathophysiological alterations which includes significant cardiovascular and respiratory effects.<sup>2</sup> Intrathecal clonidine (partial alpha 2 receptor agonist) is found to reduce the hemodynamic stress response and anesthetic requirements in a laparoscopic surgery with prolonged postoperative analgesia.<sup>3,4</sup> As a matter of fact, we know that clonidine can cause hypotension and bradycardia. Fentanyl is a synthetic opioid agonist with profound analgesia and no significant motor blockade.<sup>5</sup> A combination therapy of opioid and alpha 2 adrenoreceptor agonist has been under utilized clinically in spite of a large body of evidence describing their synergistic action.<sup>6</sup> So, we attempted to combine these two drugs hypothesizing that there will be lesser side effects and hemodynamic disturbances without compromising the quality of postoperative analgesia. Hence, we compared between a single-dose of clonidine (150 micrograms) *versus* half-dose of clonidine (75 micrograms) along with an opioid such as fentanyl (25 micrograms) to investigate if this addition provided a better hemodynamic stability with increased duration of postoperative analgesia.

### **Aims of Study**

The major aims of the study were to compare the intraoperative hemodynamic variables along with the hemodynamic response to intubation and extubation. Duration of postoperative analgesia and postoperative sedation was also assessed.

### **Materials and Methods**

After approval of the Institutional Ethics Committee, a prospective double blinded randomized study was conducted in 60 patients, aged between 18 and 50 years, of either sex, with Body Mass Index between 18 and 30 kg/m<sup>2</sup>, who belonged to American Society of Anesthesiologists Grade I and II posted for elective laparoscopic general surgeries lasting less than or equal to two hours. They were selected and divided into two groups of 30 each by using computer generated randomization table. Patients with contraindication to spinal technique, known allergy to clonidine and all patients with significant cardiovascular and respiratory diseases were excluded from our study.

Group 'CL' included 30 patients who received intrathecal clonidine 150 micrograms followed by conventional general anesthesia.

Group 'CF' included 30 patients who received intrathecal clonidine 75 micrograms followed by

intrathecal fentanyl 25 micrograms followed by conventional general anesthesia.

Preanesthetic examination including detailed history and systemic examination as well as airway examination were conducted prior to enrollment of the patient for the study. Informed written consent was obtained from the patients after explanation of the anesthesia technique. All patients received premedication with Tablet Ranitidine 150 mg and Tablet Anxit 0.5 mg the night before surgery. The selected patients were kept fasting overnight for a period of eight hours.

An 18-gauge intravenous line was secured onto either of the upper limbs. The patients were preloaded with 500 milliliters (ml) of Ringer's lactate. On shifting the patient to the operation theater, monitors including electrocardiogram, noninvasive blood pressure monitor and pulse oximeter were connected. Baseline heart rate, systolic blood pressure, diastolic blood pressure, mean arterial pressure, oxygen saturation and end tidal carbon dioxide were measured and recorded.

Under aseptic precautions, a lumbar puncture was performed in the patients in the left lateral position using 25-gauge Quincke type spinal needle at the L3-L4 intervertebral space by midline approach to get a free flowing, clear cerebrospinal fluid. Patients allotted to the Group CL received Injection clonidine 150 micrograms (1 ml) which was kept loaded in two separate syringes as 75 micrograms (0.5 ml) each, injected intrathecally one after the other. Whereas, patients allotted to Group CF received Injection clonidine 75 micrograms (0.5 ml) followed by Injection fentanyl 25 micrograms (0.5 ml), one after the other intrathecally. In either of the two groups, a trained anesthesiologist different from the anesthesiologist performing lumbar puncture was made to load the injections required for intrathecal administration in two separate syringes so as to ensure proper blinding. The patients were made supine immediately. A five minutes interval was given for recording of post injection hemodynamic parameters prior to general anesthesia.

Patients were premedicated with Injection Glycopyrrolate 0.004 mg/kg, Injection Midazolam 0.02 mg/kg and Injection Fentanyl 2 micrograms/kg. After adequate preoxygenation, conventional general anesthesia was administered to the patients. The intravenous induction agent propofol was given in graded doses so as to attain a Bispectral Index (BIS) value of 60 after which it was stopped. The volatile inhalational agent, isoflurane was used in lowest possible concentration necessary to keep

the mean arterial pressure and heart rate within 20 percentage (%) of baseline and at the same time maintaining bispectral index between 40 and 60. At the end of the procedure, residual neuromuscular blockade was adequately reversed and patients were extubated after adequate recovery. Heart rate, systolic blood pressure, diastolic blood pressure, mean arterial pressure, end tidal carbon dioxide and oxygen saturation were recorded during intubation, appropriate intervals during surgery and during extubation. Any incidence of hypotension, hypertension, bradycardia and tachycardia was also noted. Duration of surgery was recorded at the end of surgery. Patients were shifted to the postoperative ward and monitored for heart rate, blood pressure and oxygen saturation. Level of pain and sedation was assessed using Visual Analog Scale (VAS) and Ramsay Sedation Score (RSS) respectively. Time to the first rescue analgesic was noted as the duration of postoperative analgesia which corresponded to VAS > 3. Rescue analgesia was given with Injection paracetamol 1 g intravenous infusion over 15 minutes. Sedation was assessed in the postoperative period ten minutes post extubation.

Variation in basal mean arterial pressure less than 20% was treated with intravenous Injection Ephedrine 6 mg and more than 20% was managed with increase in volatile inhalational agent. Heart rate less than 60 beats per minute was treated with intravenous Injection atropine 0.6 mg. Heart rate more than 20% of the baseline was treated with intravenous Injection fentanyl 0.5 micrograms/kg. Postoperative nausea and vomiting was treated with intravenous Injection Ondansetron 4 mg.

The qualitative parameters were represented using frequencies and percentage and the

quantitative parameters were depicted using Mean (Standard Deviation) and Median (Inter Quartile Range). Student's *t*-test was used for normally distributed quantitative data and Mann Whitney *U* test was used for skewed data. Chi-square or Fisher's exact probability test was used for qualitative variables. Data was analyzed by using SPSS 22 Version Software and *p* - value less than 0.05 was considered statistically significant.

## Results

A total of 60 patients were randomly assigned into two groups of 30 each. None of these patients were excluded from the study.

Mean age in Group CL was  $39.9 \pm 8.2$  years and  $38.5 \pm 9.5$  years in Group CF ( $p = 0.5$ ). There were 13 males and 17 females in Group CL and 15 males and 15 females in group CF ( $p = 0.6$ ). The duration of surgery ( $62.5 \pm 10.1$  minutes *versus*  $62.25 \pm 10.8$  minutes) was also similar in both groups ( $p = 0.96$ ). Mean body mass index was  $23.8 \pm 1.9$  kilogram per meter square ( $\text{kg}/\text{m}^2$ ) in Group CL whereas it was  $24.0 \pm 1.6$   $\text{kg}/\text{m}^2$  in Group CF ( $p = 0.6$ ). Baseline hemodynamic data were recorded in both the groups. Demographic data were comparable in both the groups and none of them were statistically significant.

After intubation, heart rate showed a median decrease of 6 beats/minute in Group CL whereas a median increase of 4 beats/minute was seen in Group CF which was statistically significant. ( $p < 0.001$ ). At Pneumoperitoneum, a median decrease of 11 beats/minute in Group CL and 10 beats/minute in Group CF was observed which was of no statistical significance

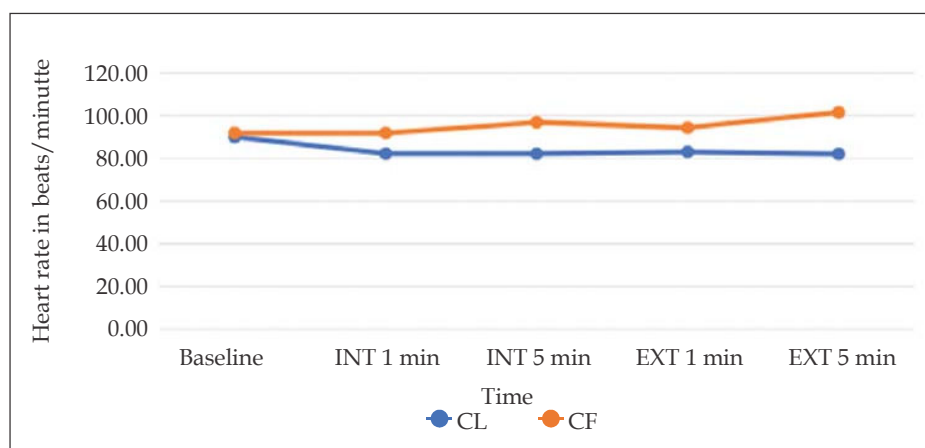


Fig. 1: Graph showing the comparison of Heart rates during intubation and extubation between both the groups.

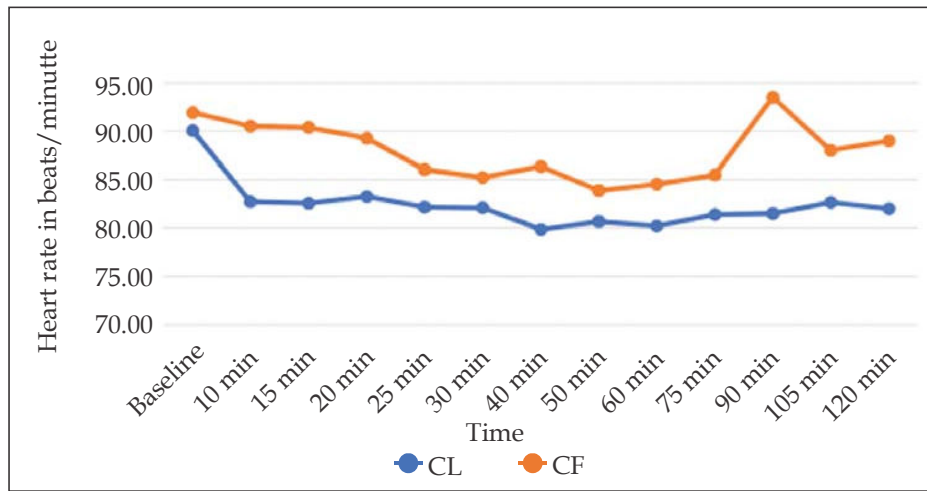


Fig. 2: Graph showing the comparison of Heart rates during pneumoperitoneum between both the groups.

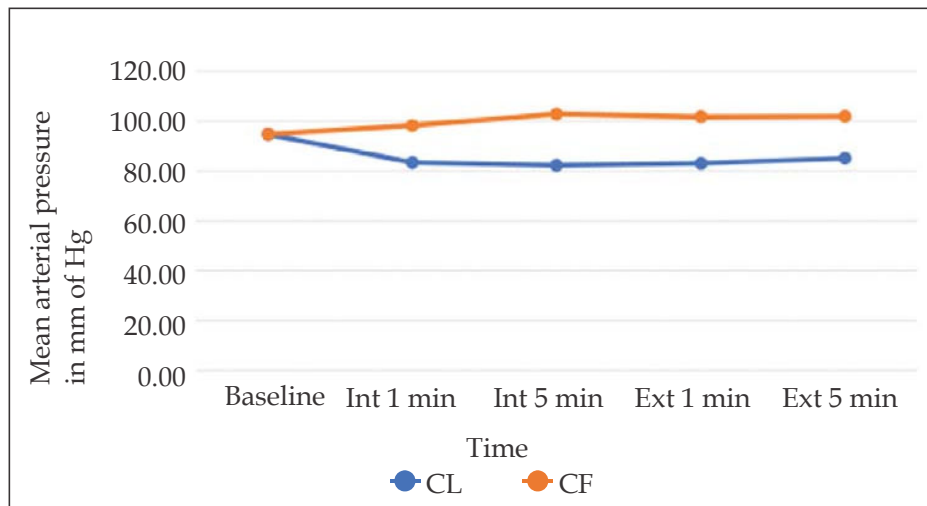


Fig. 3: Graph showing the comparison of Mean arterial pressures during intubation and extubation between both the groups.

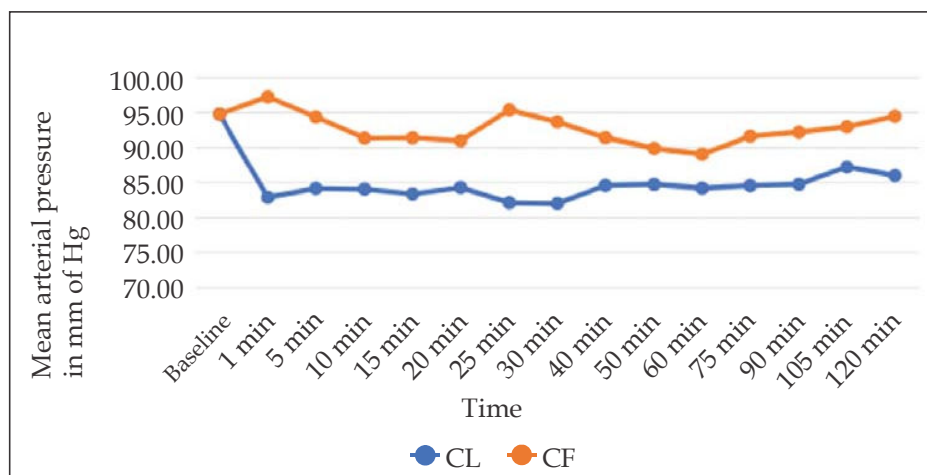


Fig. 4: Graph showing the comparison of Mean arterial pressures during pneumoperitoneum between both the groups.

( $p = 0.75$ ). Also, at extubation, a median decrease of 6 beats/minute in Group CL was found and a median increase of 11.5 beats/minute in the Group CF was observed which was statistically significant. ( $p < 0.001$ ), (Figs. 1 and 2).

Systolic blood pressure after intubation showed a median decrease of 16 mm Hg in Group CL and a median increase of 10 mm Hg in Group CF ( $p < 0.001$ ) whereas at extubation showed a median decrease of 15 mm Hg in Group CL and a median increase of 13.5 mm Hg in Group CF was noticed ( $p < 0.001$ ), both of which were of statistical significance.

Diastolic blood pressure after intubation showed a median decrease of 6 mm Hg in Group CL and a median increase of 9 mm Hg in Group CF ( $p < 0.001$ ). At extubation, a median decrease of 6 mm Hg in Group CL and a median increase of 10 mm Hg in Group CF was observed in the diastolic blood pressure ( $p < 0.001$ ). These were considered significant statistically.

In the values of mean arterial pressure after intubation, a median decrease of 9 mm Hg in Group CL and a median increase of 9.5 mm Hg in Group CF was observed ( $p < 0.001$ ). However, at extubation, a median decrease of 10 mm Hg in Group CL and median increase of 11.5 mm Hg in the Group CF was noticed ( $p < 0.001$ ) which were of statistical significance.

At pneumoperitoneum, a median decrease of 16 mm Hg in Group CL and a median decrease of 13 mm Hg in Group CF was observed ( $p = 0.09$ ) which was not significant statistically. Similarly, at pneumoperitoneum, systolic and diastolic blood

pressures showed a median decrease, how so ever, both of these were not of statistical significance ( $p < 0.05$ ), (Figs. 3 and 4).

The duration of postoperative analgesia is significantly greater in Group CL ( $10.30 \pm 1.24$  hours) in comparison to Group CF ( $5.53 \pm 1.11$  hours), (Fig. 5).

Hypertension was seen in 11 Patients of Group CF ( $p = 0.001$ ) which was statistically significant. 6 patients had tachycardia in Group CF. 2 patients had hypotension and 1 patient had hypertension in Group CL. No patients had bradycardia episodes. None of the other side effects were statistically significant.

Sedation was comparatively greater in Group CL than Group CF (Mean RSS  $2.07 \pm 0.25$  versus  $1.90 \pm 0.31$ ;  $p = 0.025$ ) but none of the patients in both the groups had RSS  $> 3$ .

## Discussion

The creation of pneumoperitoneum in a laparoscopic surgery increases the systemic vascular resistance and blood pressure thereby producing significant hemodynamic alterations along with nociception. The use of different class of drugs like opioids, beta blockers, dexmedetomidine and nitroglycerine have been tried to minimize these changes but they have their own demerits.

Clonidine being an alpha 2 adrenoreceptor agonist is known to reduce the sympathetic outflow. Also, alpha 2 agonists induce analgesia by acting

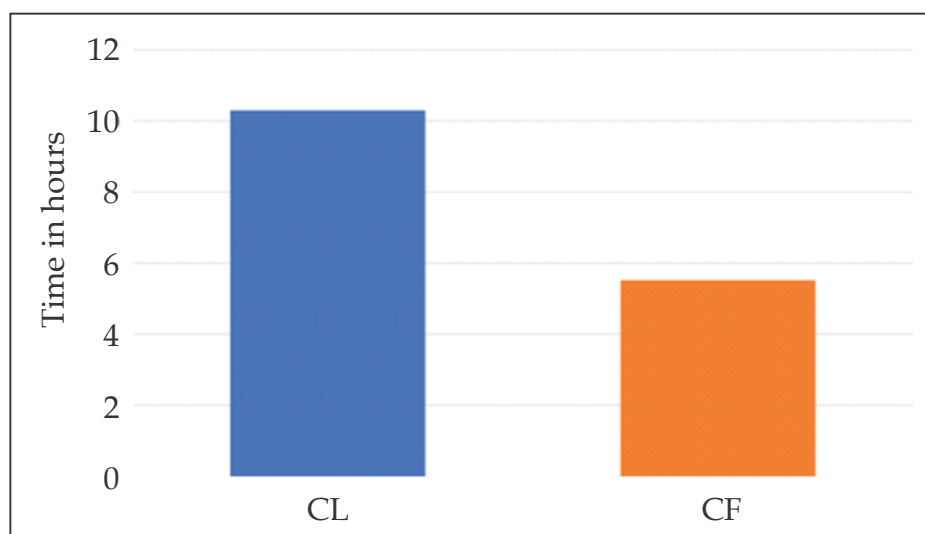


Fig. 5: Bar Diagram showing the comparison of Mean duration of postoperative analgesia between both the groups.

at different sites such as brain, brain stem, spinal cord and peripheral nerves.<sup>7</sup> Clonidine can be administered *via* various routes – oral, intramuscular, intravenous, epidural, intrathecal etc.

However, less literature is available with regard to the effect of intrathecal clonidine in laparoscopic surgeries under general anesthesia. The combination of two anesthesia techniques was chosen to add to their advantages and limit the side effects of each drug.

Also, clonidine is known to cause side effects like bradycardia, hypotension, sedation etc. So, we decided to compare the combination of two drugs, intrathecal fentanyl with clonidine *versus* intrathecal clonidine alone to observe if addition of fentanyl could help us reduce the dose of clonidine thereby limiting its side effects without a compromise in the intraoperative hemodynamic stability and postoperative analgesia.

Intrathecal fentanyl was chosen for combination in our study because of its rapid clearance from spinal cord sites and no motor paralysis.<sup>8</sup> We have avoided the use of local anesthetics through spinal route to prevent motor blockade thereby helping in early ambulation of the patients making it useful in a day care surgery.

The present study was done in 60 patients in two groups posted for elective laparoscopic surgeries under general anesthesia. Group 'CL' received intrathecal clonidine 150 micrograms whereas Group 'CF' received intrathecal clonidine 75 micrograms with fentanyl 25 micrograms followed by conventional general anesthesia.

A similar study was conducted in 2012 by Mohamed AA et al. which was a double-blind randomized trial in 90 patients to assess the safety profile and analgesic efficacy of intrathecally administered dexmedetomidine or dexmedetomidine combined with fentanyl in patients undergoing major abdominal cancer surgery.<sup>9</sup> They found that intrathecal dexmedetomidine improved the quality and duration of postoperative analgesia and provided analgesic sparing effect in patients undergoing major abdominal cancer surgery. They observed that addition of fentanyl had no valuable clinical effect. In our study, we also found that clonidine 150 micrograms alone was superior in maintaining hemodynamic stability along with prolonged postoperative analgesia. We observed that addition of fentanyl did not abolish the response to intubation and extubation but it maintained hemodynamic stability during pneumoperitoneum.

Our study results are in agreement to the work of Sripriya R et al. in 2018 in a study to compare the stress response attenuating effect of equal doses of intrathecal and intravenous clonidine on pneumoperitoneum in 75 patients.<sup>7</sup> The results of the study showed that intrathecal clonidine was more effective than intravenous clonidine in suppressing hemodynamic stress response without causing much sedation.

In 2015, Sharma AN et al. studied the hemodynamic stability with intrathecal fentanyl 25 micrograms alone in laparoscopic hysterectomies under general anesthesia in 60 patients.<sup>8</sup> In their study, they concluded that intrathecal fentanyl (25 micrograms) is superior to intravenous fentanyl in maintaining hemodynamic stability in patients undergoing laparoscopic hysterectomies under general anesthesia. We have also done a similar study with a dose of intrathecal fentanyl 25 micrograms in combination with clonidine to assess the hemodynamic stability in laparoscopic surgeries.

There have been a few studies with the usage of high-doses of sole intrathecal clonidine. Chiari et al, in a study on analgesic and hemodynamic effects of intrathecal clonidine as the sole analgesic agent conducted in 1999, studied the effects on three different doses of clonidine 50, 100 and 200 micrograms on parturients.<sup>10</sup> They concluded that intrathecal clonidine produced a dose dependent analgesia with the duration and quality of analgesia being more pronounced with 100 and 200 micrograms. Also, the hypotension required significantly more often treatment with ephedrine only in the group of 200 micrograms in their study. We observed hypotension only in two patients of Group CL which was treated with one dose of intravenous injection ephedrine.

In contrast to this study, Filos et al. compared 150, 300 and 450 micrograms intrathecal clonidine as a sole agent for postoperative analgesia following cesarean section and observed a decrease in mean arterial pressure of more than 20 % from baseline with intrathecal clonidine.<sup>11</sup> However, we have observed hypotension only in two patients in our study with a dose of 150 micrograms of clonidine (not significant statistically) probably due to our patients being subjected to surgical stress and pneumoperitoneum in laparoscopic surgeries that encountered the vasodilating properties of clonidine unlike other studies.

We observed in our study, that the two groups, intrathecal clonidine with fentanyl combination and intrathecal clonidine group alone did not show

any statistically significant difference with regard to the heart rate, mean arterial pressure, systolic blood pressure and diastolic blood pressure at pneumoperitoneum. This implied that the intrathecal clonidine and fentanyl combination is effective and hence can be used to blunt the hemodynamic responses to pneumoperitoneum in laparoscopic surgeries even though it could not abolish the hemodynamic response to intubation and extubation.

The limitation of our study was that we had not monitored sedation for a longer duration in the postoperative period as a result of which we cannot comment upon the discharge of the patient from the postanesthesia care unit. Also, the other side of effects of clonidine such as dry mouth, constipation, postural hypotension etc. was not followed up.

### Conclusion

A single dosage of Intrathecal clonidine 150 micrograms is associated with better hemodynamic stability throughout the intraoperative period and prolonged postoperative analgesia when compared to combination of clonidine 75 micrograms and fentanyl 25 micrograms.

### Key Messages

The study aimed to observe the effect of sole intrathecal clonidine to attenuate the hemodynamic alterations in laparoscopic surgeries along with quality of analgesia offered. Fentanyl was used in combination with a low-dose clonidine to look for any synergistic response in terms of attenuation of hemodynamic response and enhancement of analgesia

*Source(s) of support:* Nil

*Presentation at a meeting:* Nil

*Organisation:* Nil

*Conflicting Interest (If present, give more details):* Nil

### References

1. Kavanagh BP, Hedenstierna G. Respiratory Physiology and Pathophysiology. In: Miller RD, editor. Miller's Anesthesia, 8<sup>th</sup> edition Vol 1. Philadelphia: Churchill Livingstone Elsevier Inc; 2015.p.470-71.
2. Gutt CN, Oniu T, Mehrabi A, et al. Circulatory and respiratory complications of carbon dioxide insufflation. Digestive surgery 2004;21(2):95-105.
3. Mazdisnian F, Palmieri A, Hakakha B, et al. Office microlaparoscopy for female sterilization under local anesthesia. A cost and clinical analysis. The Journal of reproductive medicine 2002;47(2):97-100.
4. Elsharkawy H, Naguib MA. Centrally acting nonopioid analgesics. In: Flood P, Rathmell JP, Shafer S, editors. Stoelting's Pharmacology and Physiology in Anesthetic practice, 5<sup>th</sup> edition. Philadelphia: Wolters Kluwer; 2016.p.257-58.
5. Koehler RP, Keenan RJ. Management of postthoracotomy pain: Acute and chronic. Thoracic Surgery Clinics 2006;16(3):287-97.
6. Chabot-Doré AJ, Schuster DJ, Stone LS, et al. Analgesic synergy between opioid and  $\alpha_2$ -adrenoceptors. British Journal of Pharmacology 2015;172(2):388-402.
7. R Sripriya, A Arjun, P Rani, et al. Comparison of intrathecal and intravenous clonidine on attenuating hemodynamic response to capnoperitoneum. Sri Lankan Journal of Anesthesiology 2018;26(2):111-17.
8. Sharma AN, P Shankaranarayana. Hemodynamic stability with intrathecal fentanyl alone in laparoscopic hysterectomies under general anesthesia: A pilot study. Karnataka Anesthesia Journal 2015;1(2):46-49.
9. Mohamed AA, Fares KM, Mohamed SA. Efficacy of intrathecally administered dexmedetomidine *versus* dexmedetomidine with fentanyl in patients undergoing major abdominal cancer surgery. Pain physician. 2012;15(4):339-48.
10. Chiari A, Lorber C, Eisenach JC, et al. Analgesic and hemodynamic effects of intrathecal clonidine as the sole analgesic agent during first stage of labor: A dose-response study. Anesthesiology 1999;91(2):388-96.
11. Filos KS, Goudas LC, Patroni O, et al. Intrathecal clonidine as a sole analgesic for pain relief after cesarean section. Anesthesiology 1992;77(2):267-74.