

Esophageal Carcinoma with Synchronous Renal Cell Carcinoma: A Case Report

Shyamji Rawat¹, Pinky Sarahiya², Preeti Solanki³, Aishwarya Raj⁴

How to cite this article:

Shyamji Rawat, Pinky Sarahiya, Preeti Solanki *et al.* Esophageal Carcinoma with Synchronous Renal Cell Carcinoma: A Case Report/Ind J Canc Educ Res 2024;12(1):35-38.

Abstract

Synchronous malignancies often coincide with esophageal cancer, primarily within the upper aerodigestive tract. The coexistence of esophageal cancer and renal cell carcinoma (RCC) is exceptionally rare, with only 12 documented cases worldwide. Esophageal carcinomas accompanied by synchronous malignancies exhibit a poorer prognosis than isolated esophageal carcinoma, underscoring the significance of detecting synchronous RCC, as it significantly influences the choice of treatment strategy.

Presented here is a case involving synchronous esophageal and RCC in a 62-year-old Indian male. Following a review of literature, we propose that this case is likely the first reported instance from India. The patient has been scheduled for radical nephrectomy, followed by preoperative chemoradiation and esophagectomy.

This case report holds potential relevance in the expanding realm of research on possible carcinogens in synchronous malignancies development. The simultaneous onset of esophageal malignancy and RCC may be linked to the ingestion of a carcinogen excreted by the kidneys.

Keywords: Esophageal Carcinoma; Renal Cell Carcinoma; Synchronous Malignancy.

INTRODUCTION

Multiple cancers often co-occur with esophageal cancer, with Poon *et al.* reporting a 9.5% occurrence rate and Makuuchi reporting 27.1%.^{1,2} Most synchronous malignancies occur in the upper

aerodigestive tract due to shared carcinogens like tobacco smoke³, but synchronous presence of esophageal and renal cell carcinoma (RCC) is extremely rare. Only 12 cases of synchronous esophageal and RCC have been reported, in world literature.^{4,9} Detecting synchronous RCC is crucial since it can influence treatment strategy choice. So, we report a case of a squamous cell carcinoma (SCC) of the esophagus with synchronous RCC. After a thorough review of the available literature, we can assert that this is likely the first reported case from India.

CASE REPORT

A 62-year-old Indian male with a 20-pack year history of smoking presented with a history of difficulty in swallowing both solids and liquids for

Author Affiliation: ¹Professor, ^{2,4}Senior Resident, ³Resident, Department of Radiation Oncology, State Cancer Institute, Government Medical College, Jabalpur 482003, Madhya Pradesh, India.

Corresponding Author: Pinky Sarahiya, Senior Resident, Department of Radiation Oncology, State Cancer Institute, Government Medical College, Jabalpur 482003, Madhya Pradesh, India.

E-mail: Pinkysarahiya@gmail.com

Received on: 07.12.2023

Accepted on: 19.02.2024



This work is licensed under a Creative Commons Attribution-NonCommercial-ShareAlike 4.0.

the past one month, along with a 15-day history of chest pain during swallowing.

Esophagogastroduodenoscopy demonstrated a circumferential, ulceroproliferative, friable mass starting 31 cm from the upper incisor. Biopsy of the esophageal mass revealed a moderately differentiated keratinizing squamous carcinoma. A metastatic work-up, including a computed tomography (CT) scan of the chest and abdomen, revealed asymmetric circumferential mural thickening involving approximately 12 cm of the lower thoracic esophagus at the thoracic spine vertebra level 8 to 12, extending into the gastroesophageal junction (GEJ) with few

periesophageal lymph nodes. Another well-defined lesion measuring 3.9 x 4.2 cm was observed in the anterior lower pole region of the left kidney. A positron emission tomography-computed tomography (PET-CT) scan was also performed, revealing a lesion in the lower thoracic esophagus, GEJ, and proximal cardia of the stomach (with a maximum standardized uptake value [SUV Max] of 8.79) (Fig. 1) with few regional nodes and a mass in the left kidney (SUV Max 2.40) (Fig. 2), suggesting a possible second primary. An Ultrasound-guided fine needle aspiration cytology (FNAC) of the renal mass revealed RCC. After urological surgery consultation, we have scheduled the patient for a

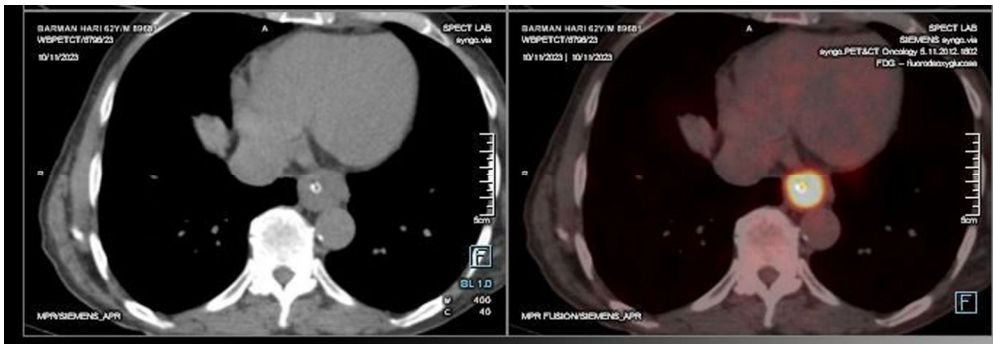


Fig. 1: PET-CT showing lesion in the lower thoracic esophagus

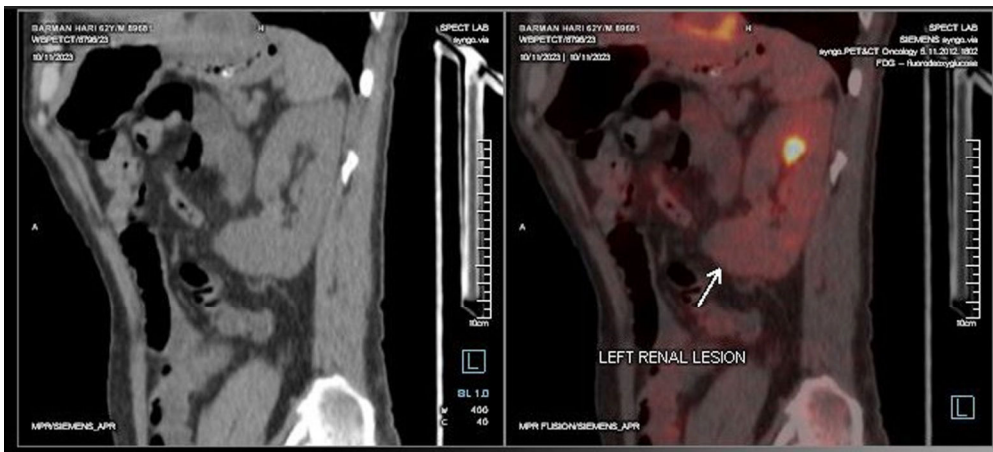


Fig. 2: Pet-Ct Showing a Mass in the Left Kidney

left radical nephrectomy, followed by preoperative chemoradiation and esophagectomy for esophageal carcinoma.

DISCUSSION

Synchronous esophageal and RCC is extremely rare. In the study conducted by De Hingh and

colleagues,⁴ they reported an incidence of 2.1% (4 out of 192) of synchronous RCC in patients who underwent surgery for esophageal malignancy. Prior to this study, there have been isolated case reports of four instances where patients had both esophageal malignancy and synchronous RCC.⁵⁻⁷ Furthermore, Kumagai *et al.* conducted a retrospective study between 1985 and 1998, involving 744 patients,

and identified three additional cases of esophageal malignancy with synchronous RCC.⁸ Notably, in all of these cases, the esophageal malignancy was either adenocarcinoma or of the squamous cell subtype. Only one case of small cell carcinoma of the esophagus accompanied by a synchronous primary RCC has been documented until now.⁹ So, in the world literature, we identified just 12 cases of synchronous esophageal and RCC. We are reporting another new case (likely the first reported case from India) of this rare synchronous malignancy, involving esophageal carcinoma and RCC.

In cases of esophageal cancer co-occurring with other primary cancers, the prognosis is chiefly influenced by the esophageal cancer itself. The 5-year survival rates for such patients are notably worse than those for individuals with solitary esophageal cancer.⁸ Distinguishing between a renal metastasis and a primary RCC is crucial in order to make an informed decision regarding the surgical approach for the renal mass.

The co-occurrence of esophageal malignancy and RCC may be linked to exposure to a carcinogenic substance excreted by the kidneys. This exposure could affect both the esophagus and the kidneys. Notably, our patient has a connection to mushroom farming. The carcinogenic compound "hydrazine"¹⁰ is known to be present in raw mushrooms¹¹ and is also found in tobacco products.¹⁰ Considering our patient's history of tobacco smoking, it is plausible that the potential carcinogen may be attributed to the presence of hydrazine, originating from either tobacco smoke or exposure to raw mushrooms. Nevertheless, further research is necessary to validate this hypothesis.

Detecting synchronous RCC alongside esophageal cancer poses treatment challenges. Priority is placed on curative esophageal tumor removal due to immediate risk. In our case, prioritizing nephrectomy before esophagectomy was driven by positive regional nodes. Preoperative chemoradiation is necessary before esophagectomy to render this locoregionally advanced disease resectable. Due to the lengthy 5–6-week duration, we chose to prioritize nephrectomy first. Individual patient circumstances should guide treatment decisions.

CONCLUSION

The coexistence of esophageal cancer and renal cell carcinoma (RCC) is exceptionally rare, but it can occur. Therefore, it is important to be vigilant about esophageal carcinomas that are accompanied

by synchronous RCC. These synchronous malignancies tend to have a poorer prognosis compared to isolated esophageal carcinoma and significantly influence the choice of treatment strategy.

Ethics Statement:

The patient's daughter provided verbal consent for this publication.

Conflict of Interest:

The authors declare that they have no conflict of interest.

REFERENCES

1. Poon RT, Law SY, Chu KM, Branicki FJ, Wong J. Multiple primary cancers in esophageal squamous cell carcinoma: incidence and implications. *Ann Thorac Surg.* 1998;65(6):1529-1534. doi:10.1016/s0003-4975(98)00177-5.
2. Makuuchi H, Tanaka H, Shimada H, *et al.* Esophageal cancer and multiple primary cancer. *Jpn J Cancer Chemother.* 1997;24:1-7.
3. Van Oijen MG, Slootweg PJ. Oral field cancerization: carcinogen-induced independent events or micrometastatic deposits? *Cancer Epidemiol Biomarkers Prev.* 2000;9:249-256.
4. De Hingh IH, van Berge Henegouwen MI, Laguna Pes MP, Busch OR, van Lanschot JJ. Synchronous esophageal and renal cell carcinoma: incidence and possible treatment strategies. *Dig Surg.* 2008;25(1):27-31. doi:10.1159/000117820.
5. Crack J, Finkelstein L, Marks B. Simultaneous renal cell carcinoma, adrenal adenoma, and carcinoma of the esophagus: Report of a case. *J Am Osteopath Assoc.* 1983;83(4):89-94. https://doi.org/10.1515/jom-1983-830415.
6. Koike T, Honda H, Kimikawa M, *et al.* A case of double primary malignant neoplasm in the esophagus and kidney. *Shokaki Naishikyo No Shinpo.* 1991;39:293-295.
7. Kobayashi S, Kabuto T, Doki Y, Yamada T, Miyashiro I, Murata K, Hiratsuka M, Kameyama M, Ohigashi H, Sasaki Y, Ishikawa O, Imaoka S. Synchronous esophageal and renal cell carcinoma: Esophageal and renal cell carcinoma. *Dis Esophagus.* 2008;13:305-310.
8. Y, Kawano T, Nakajima Y, *et al.* Multiple primary cancers associated with esophageal carcinoma. *Surg Today.* 2001;31(10):872-876. doi:10.1007/s005950170025.
9. Deepak P, Devi R, Pillai H. Esophageal small cell carcinoma with synchronous renal cell carcinoma: a case report with review of the literature. *Case Rep Gastroenterol.* 2011;5(1):196-200. Published 2011 Apr 13. doi:10.1159/000326958.

10. The Occupational Safety and Health Administration. Skin Exposures and Effects. <https://www.n.cdc.gov/TSP/PHS/PHS.aspx?phsid=499&toxid=89>.
11. Toth B. Hepatocarcinogenesis by hydrazine mycotoxins of edible mushrooms. *J Toxicol Environ Health.* 1979;5(2-3):193-202. doi:10.1080/15287397909529744.

