

## Carcinoma Prostate Metastasizing to Penis: A Rare Case Report

Paragi Goyal<sup>1</sup>, Amit Verma<sup>2</sup>, Virendra Bhandari<sup>3</sup>

### How to cite this article:

Paragi Goyal, Amit Verma, Virendra Bhandari. Carcinoma Prostate Metastasizing to Penis: A Rare Case Report. Ind J Canc Educ Res 2024;12(1):31-33.

### Abstract

Carcinoma of the prostate metastasizing to the penis is rare. These patients have a poor prognosis receiving various treatment modalities. This report describes a rare case of penile metastasis from prostate cancer, indicating that clinicians need to improve their understanding and discrimination of this disease.

**Keywords:** Carcinoma Prostate; Metastasis to Penis; Prostate Cancer.

## INTRODUCTION

Prostate cancer, the second most common type of cancer worldwide, is frequently observed in males more than 50 years of age. With current medical advances and improved screening methods, the detection rate of prostate cancer has become significantly higher than before. However, most patients are diagnosed when they are asymptomatic. Also due to advancement in surgery and Radiotherapy treatment facilities the

survival also remains very good. The common sites of metastasis from prostate cancer are the bones and lymph nodes, less frequently to the lungs, brain and very rarely to other sites including the penis. Metastasis to the penis is associated with poor prognosis.<sup>1</sup> The most likely route of dissemination is thought to be retrograde venous blood flow because of the presence of significant traffic between the pelvic venous plexus and the deep dorsal penile venous plexus. It is a debilitating and near terminal condition at presentation because of dismal prognosis and poor survival rates. Treatment options depend on the general condition of the patient, site and extent of the primary tumor, presence of metastases and symptomatology. Conservative management is generally advocated with emphasis on improvement of quality of life. The treatment options include local excision of the tumor, radiation therapy, bilateral orchiectomy, additional hormonal and chemotherapy, and partial or total amputation of the penis.<sup>1,4,8,11</sup> Supportive and palliative care is generally recommended to improve the quality of life of patients.

**Author Affiliation:** <sup>1</sup>Registrar, Department of Radiation Oncology, <sup>2</sup>Professor, Department of Pathology, <sup>3</sup>Professor, Department of Radiotherapy, Sri Aurobindo Medical College and PG Institute, Indore 453555, Madhya Pradesh, India.

**Corresponding Author:** Virendra Bhandari, Professor, Department of Radiotherapy, Sri Aurobindo Medical College and PG Institute, Indore 453555, Madhya Pradesh, India.

**E-mail:** virencancer@yahoo.co.in

**Received on:** 26.10.2023

**Accepted on:** 30.11.2023



This work is licensed under a Creative Commons Attribution-NonCommercial-ShareAlike 4.0.

## CASE REPORT

In this Retrospective study 564 Patients of Carcinoma Prostate with distant metastasis who presented to us between 2012 to 2021 were studied. Patients with Common sites of metastasis were excluded and only unusual sites of metastasis were considered. We found only one patient of unusual metastasis that too to the Penis. He was a 59 year old male and was diagnosed as a case of carcinoma Prostate in 2013 when he had a history of dribbling of urine, pain in Abdomen, along with history of hypertension. MRI of the pelvis showed lesions in the peripheral zones of prostate. His PSA value during this time is not known. Patient underwent Transurethral resection of Prostate (TURP). The Histopathology was suggestive of Adenocarcinoma, Gleason Score 3+4=7. Post operatively the patient was lost to follow up and again presented after 4 months with complaints of Burning micturation and retention of urine. Again he underwent Optical internal urethrotomy, Transurethral resection of Prostate and Bilateral subcapsular Orchidectomy in November 2013. Repeat Biopsy was suggestive of Prostatic Adenocarcinoma with Gleason Score of (4+5) 9 ie there was progression of disease. Again he was lost to follow up and presented to us with complaints of multiple nodules, burning sensation and pain on penis in January 2015. On examination he had multiple small nodules over glans penis which was associated with redness. There were no inguinal lymph node palpated and other systemic examination was also normal. PSA was 0.117. Because of urethral stricture he underwent Optical Urethrotomy, circumcision and Urethropasty along with biopsy from Penis lesions. Histopathology was suggestive of Invasive Basaloid Squamous cell carcinoma. Block from penis was reviewed at Tata Memorial Hospital Mumbai and was suggestive of Malignant tumor with epithelial differentiation Metastatic Prostate Adenocarcinoma. Patient was again lost to follow up and started taking treatment outside. He took 9 weekly cycles of docetaxel and his PSA was 0.68 and PET CT Scan was suggestive of no Residual disease and no metabolic activity any where. MRI Abdomen done in January 2016 showed Residual Prostatic tissue around 2.2x1.8x1.44 cm, no lymphadenopathy, with tiny penile lesions. His Urinary bladder appear distended with diffuse circumferential wall thickening approximately 18mm showing Muscular Hypertrophy. This patient was discussed in Tumor Board meeting of the institute and it was decided that patient should undergo Total Penectomy. Patient Underwent Penectomy in March 2016. Post Operative the specimen showed a residual tumor 2x1.5x1 cm

and histopathology was suggestive Metastatic Adenocarcinoma Glans Penis. The patient was then kept on metromonic therapy and expired in October 2016 with a total survival of 22 months after developing penile metastasis.

## RESULTS

Metastasis from Carcinoma Prostate to Glans Penis is very rare. According to literature, the overall survival rate of penile metastasis is generally poor, with approximately 9 months of average survival but in our case the patient survived for 22 months.

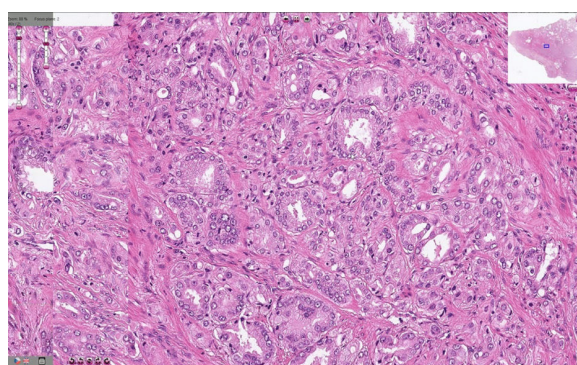


Fig. 1: Histology of Adenocarcinoma in biopsy from Prostate

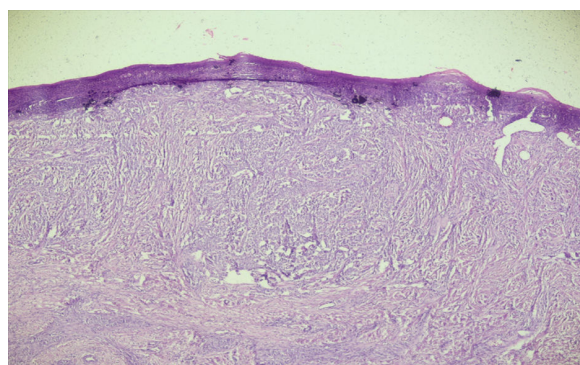


Fig. 2: Sections of Penis from biopsy

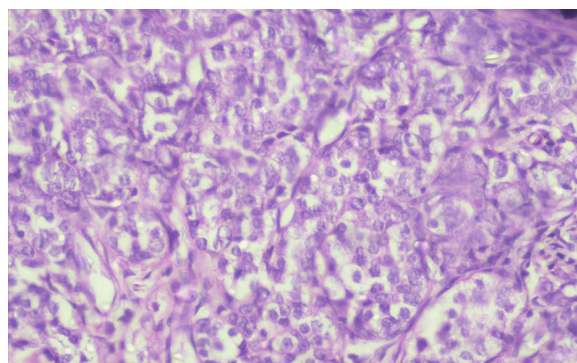


Fig. 3: Sections of Penis showing Metastatic Adenocarcinoma

## DISCUSSION

According to the literature, till now only 219 cases of penile metastases have been reported among which genitourinary cancers were the most common primaries<sup>2</sup> and very few cases are from primary in the prostate. The poor prognosis of penile metastasis do not have the explanatory cause but we know the dissemination of the metastasis of carcinoma Prostate is direct invasion, implantation, haematogenous dissemination and lymphatic dissemination.<sup>3</sup> The prognosis remains poor in this group of patients. In one of the studies conducted in Japan, 71% of patients died within 6 months of such a diagnosis<sup>4</sup>, but in our study the patient survived for more than 22 months with extensive use of all the treatment modalities. According to Dijkstra S *et al.*<sup>5</sup> penile metastasis was seen in Patients but rare, similarly in our study out of 564 patients with metastatic Prostate Cancer only 1 patient was found to have Penile metastasis, so we should not consider decreasing level of PSA only to rule out metastasis or progression of disease but detailed general and systemic examination should be done and to consider symptoms, do not be neglected them at all, consider nodules on penis, burning micturation, redness as classical symptoms of penile metastasis. If required other investigations including PSMA (PET CT) Scan should be done.

Patients with prostate carcinoma and testicular or penile metastases have unique clinical and pathologic characteristics. Many of these patients' tumors are compatible with a subtype of prostate carcinoma known as ductal adenocarcinoma<sup>6</sup> so was in our study the histology report suggest metastatic adenocarcinoma. In the Study by soma *et al.*<sup>7</sup> patient just survived for 4 months where as in our study the patient survived for more than 22 months, but in both the study patient presented with the same presenting complaint i.e Nodules on penis and redness and itching.

## CONCLUSION

564 cases of Carcinoma Prostate with different metastasis were identified, out of which only 1 (0.17%) patient was identified with metastasis to Penis which is very rare. We must keep in mind the rare presentation of the metastasis, and so regular follow up is necessary with complete examination and investigations should be done like PET CT scan. Management of patients with penile metastases should focus on improving their quality of life with multitude of palliative options rather putting the patient through a morbid systemic/surgical therapy.

## REFERENCES

1. Dai Y, Shi BL, Zhang J, Liu SN, Jia YT. Penile metastasis from prostate cancer misdiagnosed as Peyronie disease: A case report. *Sexual Medicine*. 2023 Feb 1;11(1):qfac011.
2. Ansari H, Prasant R, Franks A. Prostatic carcinoma metastasis to the penis – an uncommon site. *Lancet Oncol*. 2003;4:705–06.
3. Abehouse BS GA. Metastatic tumours of the penis; a review of literature and report of two cases. *J Urol*. 1961;86:99.
4. Kotake Y, Gohji K, Suzuki T, Watsuji T, Kusaka M, Takahara K, *et al.* Metastases to the penis from carcinoma of the prostate. *Int J Urol*. 2001;8:83–86.
5. Dijkstra S, van der Heijden AG, Schaafsma HE, *et al.* Synchronous penile metastasis from a high-grade adenocarcinoma of the prostate. *Case Rep Urol*. 2012;2012:193787.
6. Tu SM, Reyes A, Maa A, Bhowmick D, Pisters LL, Pettaway CA, Lin SH, Troncoso P, Logothetis CJ. Prostate carcinoma with testicular or penile metastases. Clinical, pathologic, and immunohistochemical features. *Cancer*. 2002;94:2610–2617.
7. Soma S, Reddy PC, Bhat R, Prabhu S. Penile Metastases From Prostate Adenocarcinoma: A Rare Presentation. *J Clin Diagn Res*. 2015;9(9):PD03-PD4.

