

## Invasive Mucormycosis in an Adolescent Female with Type-I Diabetes Mellitus

Sunil V Jagtap<sup>1</sup>, Shubham S Jagtap<sup>2</sup>, Devika Suresh Borade<sup>3</sup>, Gauri Avinash Patil<sup>4</sup>,  
Shuchita Gaur<sup>5</sup>

### How to cite this article:

Sunil V Jagtap, Shubham S Jagtap, Devika Suresh Borade, *et al.*/Invasive Mucormycosis in an Adolescent Female with Type-I Diabetes Mellitus/Indian Journal of Pathology: Research and Practice 2023;12(1) 29-33.

### Abstract

Mucormycosis is aggressive and potentially fatal in patients particularly among diabetic patients suffering from ketoacidosis. A 16 year female patient came to medicine department with a complaint of fever since 15 days, cough and breathlessness and chest pain and palpitation since 10 days also having left orbital and facial swelling since 3 days. Patient is known case of type 2 diabetes mellitus. On CT Scan PNS (Plain) showed a soft tissue thickening causing complete opacification of left maxillary sinus extending to left frontal, left ethmoid and left hemisphenoid sinuses. The treatment of debridement of necrotic tissue from left maxillary sinus was done. On histopathology diagnosed as invasive mucormycosis. We are presenting this case of mucormycosis in a diabetic patients suffering from ketoacidosis for its the clinical, radiological, histopathological findings and management of the disease. Early diagnosis and prompt treatment significantly improves survival and decreases morbidity.

**Keywords:** Mucormycosis; Diabetic Ketoacidosis; Opportunistic Infection; Rhinoorbital Infections.

### INTRODUCTION

**M**ucormycosis (zygomycosis) is an angioinvasive mould infection caused by a group of ubiquitous fungi (Mucorales). It is a form of fulminant invasive fungal infection of the sinonasal



**Author Affiliation:** <sup>1</sup>Professor, Department of Pathology, <sup>2</sup>Assistant Lecturer, Department of Medicine, <sup>3,5</sup>Assistant Lecturer, Department of Pathology, Krishna Institute of Medical Sciences (Deemed University), Karad 415110, Maharashtra, India.

**Corresponding Author:** Sunil V Jagtap, Professor, Department of Pathology, Krishna Institute of Medical Sciences (Deemed University), Karad 415110, Maharashtra, India.

E-mail: [drsvjagtap@gmail.com](mailto:drsvjagtap@gmail.com)

Received on: 23.11.2022

Accepted on: 28.12.2022



This work is licensed under a Creative Commons Attribution-NonCommercial-ShareAlike 4.0.

tract that often extends to the orbit, brain, palate, and skin.<sup>1</sup> The common form of mucormycosis is almost exclusively an opportunistic infection that seen in the rhinomaxillary region and in patients with immunocompromised state such as diabetes.<sup>2</sup> In our case patient was young having uncontrolled type 2 diabetes mellitus developed ketoacidosis and rhinoorbital mucormycosis.

### CASE REPORT

A 16 year female patient came to medicine department with a complaint of fever since 15 days, cough and breathlessness and chest pain and palpitation since 10 days also having left orbital and facial swelling since 3 days. On palpation, the

swelling was soft in consistency, tender with rise of temperature. Left periorbital edema, proptosis and ophthalmoplegia was noted. On examination, the patient was lethargic and tachypnoeic. The patient was apparently asymptomatic before 1 month. No history of Covid 19 infection. Her RT PCR was negative. There was no any systemic illness. Patient is known case of type 2 diabetes mellitus, since last 2 years and is on antidiabetic treatment. On investigation routine PP blood sugar level was 460 mg/dl. Creatinine 1.5mg/dL, BUN 50.7 mg/dL, pH 7.4, Anion gap 40.2 mEq/L, Serum potassium, Serum sodium were raised. The urine analysis showed positive for glucose, ketone bodies and leucocytes. Complete blood count showed, Hb11.4gm%, Total leucocyte count-13600/cumm, neutrophilia, and raised ESR.

Based on the history and clinical findings, a provisional diagnosis of mucormycosis of the left maxillary sinus extending to left frontal, left ethmoid maxilla and orbital was made.

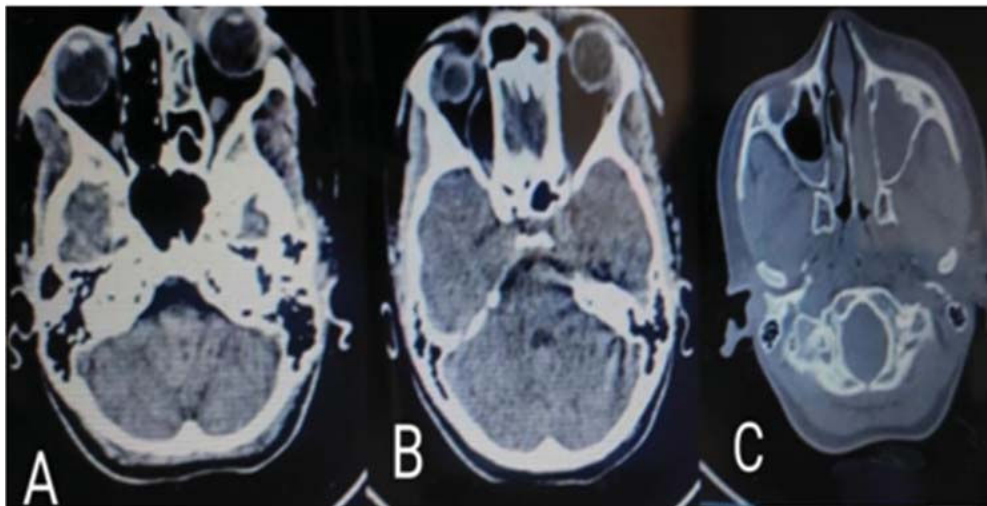
On CT Scan PNS (Plain) shoed soft tissue thickening causing complete opacification of left maxillary sinus extending to left frontal, left ethmoid and left hemisphenoid sinuses causing blockage of fronto-ethmoidal recess and osteomaatal complex.

There is evidence of mild proptosis with mild preseptal soft tissue thickening extending along the lateral aspect of extraconal space of left orbit. No obvious bone erosin noted. Imaging features CT represent fungal etiology.

Mild mucosal thickening noted in right maxillary sinus. Deviation of nasal septum noted with convexity towards right side. Concha bullosa noted on right side. Cribriform plate and critsa galli napper normal. Hard palate appears normal.

Right orbit and eye ball appear normal. Bilateral zygoma appear normal. Visualized brain parenchyma appears normal.

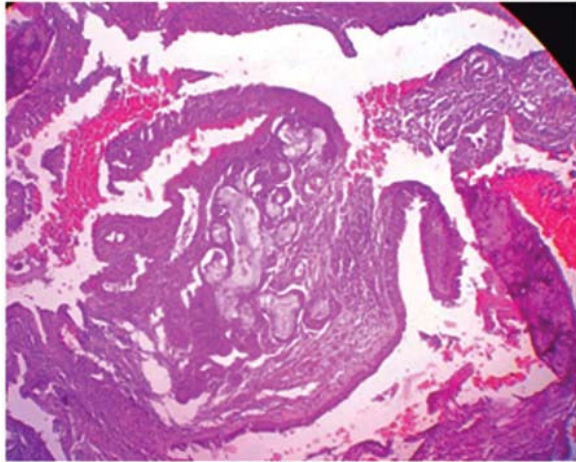
On MRI Brain and Orbit plain and contrast (Figure 1 A,B,C) showed gyri in left fronto-parieto-occipital lobes thickening and post contrast enhancement with adjoining white matter appearing T2 hyperintense and T1 hypointense and diffusion restriction. Adjacent sulcal spaces in left parietal lobe shows blooming (subarachnoid hemorrhage)-Subacute infarct merits consideration over early cerebritis. Infarct in left half of pons. Orbital cellulitis and optic neuritis on left side. Active infection/phlegmonous tissue in left masticator space and adjoining areas was noted.



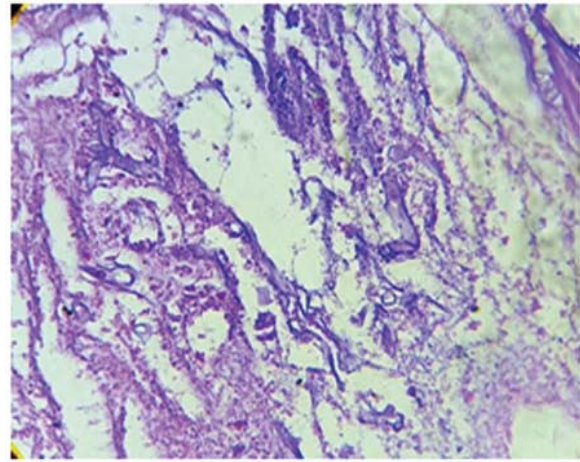
**Fig. 1:** A,B,C: CT Scan PNS(Plain) Soft tissue thickening causing complete opacification of left maxillary sinus extending to left frontal, left ethmoid and left hemisphenoid sinuses.

The surgical debridement of necrotic tissue was done. The histopathology of nasal, left maxillary sinuses and orbital tissue showed necrotic tissue infiltrated by numerous polymorpho nuclear cells, lymphocytes, plasma cells, and few multinucleated giant cells (Fig. 2). The necrotic tissue showed numerous broad aseptate fungal hyphae are broad

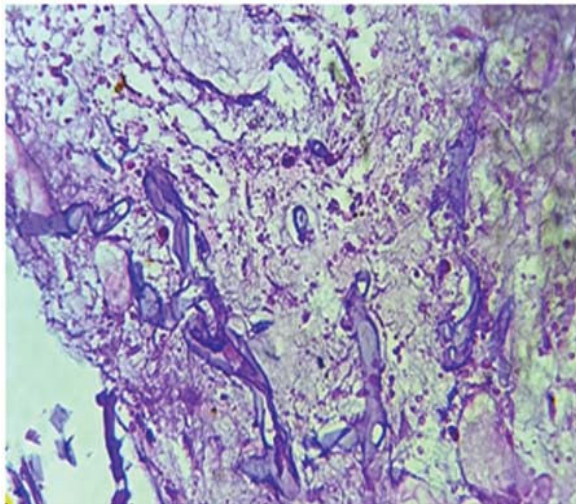
(7-30  $\mu$ m), thin walled, with non-dichotomous, irregular branching hyphae. (Fig. 3,4) There was invasion of blood vessel, vasculitis and thrombus formation (Fig. 5). Periodic acid Schiff stained section showing magenta pink colored aseptate fungal hyphae. On histopathologically diagnosed as invasive mucormycosis.



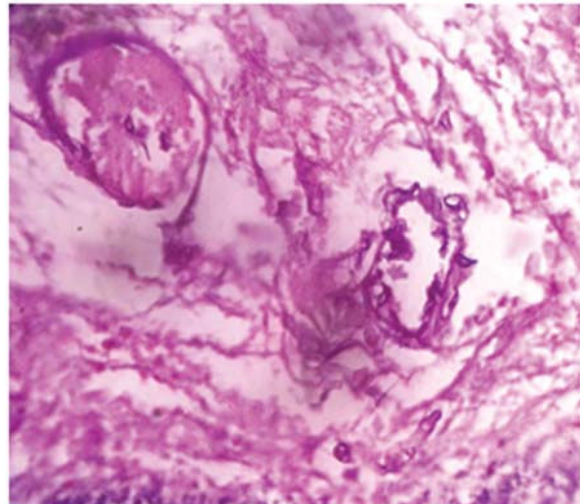
**Fig. 2:** Section showing inflammatory cells, necrotic soft tissue and bony tissue and fungal hyphae. (H and E-stain, 40x)



**Fig. 3:** Tissue section showing aseptate fungal hyphae branching at right angles. (H and E-stain, 40x)



**Fig. 4:** Tissue section showing aseptate fungal hyphae branching at right angles. (H and E-stain, 100x)



**Fig. 5:** Tissue section showing aseptate fungal hyphae with angioinvasion and thrombi. (H and E-stain, 100x)

Patient treated with surgical debridement combined with intravenous Amphotericin B administration and responded well. The treatment of diabetic ketoacidosis (DKA) was done as per DKA management protocols. The emphasis on intravenous fluids, insulin administration, potassium, bicarbonate, and electrolyte administration was done. On follow up patient responded well to the treatment.

## DISCUSSION

Mucormycosis (Zygomycosis) is an acute opportunistic infection caused by a saprophytic fungus that belongs to the class of phycomycetes. Mucormycosis is aggressive and potentially fatal in patients particularly among diabetic patients

suffering from ketoacidosis.

Depending on organ involvement, mucormycosis is of rhinocerebral, pulmonary, cutaneous, gastrointestinal or disseminated type.<sup>3</sup> Among these the most common form is rhinocerebral which is subtype into rhinonasal, rhinoorbital or rhinoorbitocerebral. In our case it is of rhinoorbital. Orbital involvement occurs when the infection invades the orbital wall from the paranasal sinuses.

Among the various predisposing factors for mucormycosis, the are uncontrolled diabetes is a very common etiological factor (60-80%). The patient having diabetes with ketoacidosis are more prone. Other factors are renal failure, longterm corticosteroid and immunosuppressive therapy, malignancies, organ transplant, burns, protein energy malnutrition, and acquired immune

deficiency syndrome (AIDS) are given.<sup>4-6</sup> In our case there was no any COVID 19 infection was detected on RT PCR. The cooccurrence of diabetes and glucocorticoid use in COVID 19 has more risk for fungal infections.

In our case patient was having severe hyperglycemia with ketoacidosis. In patient of diabetes mellitus altered immunological response of body to any infection occurs in various ways. Hyperglycemia stimulates fungal proliferation and also causes decrease in chemotaxis and phagocytic efficiency which permits organisms to thrive in acidrich environment. In the diabetic ketoacidosis patient, there is an increased risk of mucormycosis caused by *Rhizopus oryzae* as these organisms produce the enzyme ketoreductase, which allows them to utilize the affected individuals ketone bodies. Persistently high levels of blood sugar cause damage to blood vessels, nerves, and various cell types in the body.

In young patients with diabetes mellitus (DM) who have poor glycemic control and acute ketosis may have often rapidly fatal fungal infection that is an important cause of death.<sup>3</sup>

The rhinocerebral form is the most common form of infection commonly seen in patients with uncontrolled diabetes mellitus. Rhino-Orbital Mucormycosis (ROM) is a rare disease with an overall prevalence in 0.15% of the diabetics.

In rhinocerebral mucormycosis patient clinically present with fever, malaise, headache, facial pain, swelling, nasal bleeding, nasal black dry, dark scab formation, etc. The disease initiates in the nasal mucosa extends to the paranasal sinuses .In addition, mucormycosis can also involve the retroorbital region by direct extension. In our case left periorbital edema, proptosis and ophthalmoplegia was noted. Clinically they present with vision loss, ophthalmoplegia and proptosis. Ocular manifestations are often the first presenting symptoms in patients suffering from rhinocerebral mucormycosis which includes prominent eyeballs, swelling and redness around the eyes, impaired eye movement, decreased vision, and potentially blindness.<sup>7</sup> Ophthalmoplegia arises from infection of the muscles and orbital space or when the third, fourth and sixth cranial nerves are affected. Once fungal hyphae enter into the blood stream, systemic spread to cerebrum or lungs may occurs which can be fatal for the patient.

On radio imaging opacification of sinuses, patchy

effacement of bony walls of sinuses are noted. CT, MRI image scan can demonstrate erosion or destruction of bone and the extent of disease.

The laboratory diagnostic for mucormycosis are on histopathology, direct cytology smear, 10–20% potassium hydroxide (KOH) smear, and cultures. Fungal culture is highly specific, but the sensitivity of this approach is just 25%, limiting its clinical applicability.<sup>8</sup> The histopathological examinations with hematoxylin and eosin, periodic acid-Schiff (PAS), and Grocott-Gomori methenamine sliver (GMS) stains should be performed of infected tissues.

Histopathologically, the lesion demonstrates broad aseptate fungal hyphae are broad (3–25mm), thin walled, with non-dichotomous, irregular branching, occasionally at right angles.

Differential diagnosis includes aspergillosis where the hyphae of aspergillus species are septate, smaller in width and branch at more acute angles. Another differential are *Candida mycelia* in which they are thin, 2–4 µm in diameter and can be bead like. In rare patients COVID-19 associated with co-infection of mucormycosis and actinomycosis wer reported.<sup>9</sup>

The early diagnosis and treatment of mucormycosis is very important in terms of prognosis. The therapeutic approach includes aggressive surgical and medical interventions.<sup>10</sup> Amphotericin B has become the gold standard in the systemic treatment of mucormycosis. Parenteral use of antifungal agents such as amphotericin B, azoles, and caspofungin increases the survival rate in patients. The monitoring of serum creatinine is important in patients receiving amphotericin B with diabetic nephropathy. As renal function may deteriorate over time in these patients. In diabetic patients with mucormycosis, hyperbaric oxygen therapy is another alternative that increases the survival rate. Hyperbaric oxygen kills fungus by suppressing the growth of mucorales, promot neutrophil activity, stimulate the release of growth factors that help in wound healing, and increase oxygen delivery to necrotic tissues. The treatment of debridement of necrotic tissue is required in critical stage of mucormycosis. The methods for debridement e includes surgical, enzymatic, mechanical, autolytic, and biosurgical. The surgery includes lateral rhinotomy, sinusectomy, orbital exenteration. Those who received surgical treatment in addition to amphotericin B had a better survival.<sup>11</sup>

## CONCLUSION

Mucormycosis is an aggressive fulminant invasive fungal infection. We are presenting case of mucormycosis in a adolescent diabetic patients with ketoacidosis for its clinical presentation, radiological, pathophysiology findings and management of the disease.

## REFERENCES

1. Auluck A. Maxillary necrosis by mucormycosis. A case report and literature review. *Med Oral Patol Oral Cir Bucal*. 2007; 1; 12(5):E360-4.
2. Roden MM, Zaoutis TE, Buchanan WL, Knudsen TA, et al. Epidemiology and outcome of zygomycosis: a review of 929 reported cases. *Clin Infect Dis*. 2005;1;41(5):634-53.
3. Petrikos G, Skiada A, Lortholary O, Roilides E, Walsh TJ, Kontoyiannis DP. Epidemiology and clinical manifestations of mucormycosis. *Clinical Infectious Diseases*. 2012 ;1;54(suppl- 1): S23-34.
4. Sunil VJ, Swati SJ, Atul H, Snigdha AV, Divya B, Shubhang M. COVID-19 Associated Mucormycosis (CAM): A Clinico Histopathological Study of at A Tertiary Care Centre. *Indian Journal of Pathology: Research and Practice*. 2022; 11,1:19-26.
5. Jeong W, Keighley C, Wolfe R, et al. The epidemiology and clinical manifestations of mucormycosis: a systematic review and meta-analysis of case reports. *Clin Microbiol Infect*. 2019;25:26-34.
6. Jagtap SV, Jagtap SS, Nagar V, Varshney K . Invasive mucormycosis in post COVID-19 infection: Case report with review. *IP Arch Cytol Histopathol Res*. 2021;6(2):135-139.
7. Karadeniz Uğurlu Ş, Selim S, Kopar A, Songu M. Rhino-orbital Mucormycosis: Clinical Findings and Treatment Outcomes of Four Cases. *Turk J Ophthalmol*. 2015;45(4):169-174.
8. Bavikar P, Mehta V. Rhino-orbital-cerebral Mucormycosis: a fatal complication of uncontrolled diabetes mellitus. *Cureus*. 2017;9(11):e1841.
9. Jagtap SV, Hulwan A, Vartak S et.al. Co-infection of mucormycosis and actinomycosis in COVID-19 infection. *Int J Health Sci Res*. 2021; 11(8): 127-130.
10. Galletti B, Gazia F, Galletti C, Perani F, Ciodaro F, Freni F, et al. Rhinocerebral mucormycosis with dissemination to pontine area in a diabetic patient: Treatment and management. *Clin Case Rep*. 2019;7(7):1382-7.
11. Bhansali A, Bhadada S, Sharma A, et al. Presentation and outcome of rhino-orbital-cerebral mucormycosis in patients with diabetes. *Postgraduate Medical Journal*. 2004;80:670-674.

