

Fetal Scalp Blood Sampling: Review

Alka B Patil¹, Rahul V Patil², Akshay N Jagtap³, Sneha U Sanap⁴

Author's Affiliation:

¹Professor and Head, ^{2,3,4}Junior Resident, Department of Obstetrics and Gynecology, ACPM Medical College, Dhule, Maharashtra 424002, India.

Corresponding Author:

Alka B Patil, Professor and Head, Department of Obstetrics and Gynecology, ACPM Medical College, Dhule, Maharashtra 424002, India.

E-mail: alkabpatil@rediffmail.com

Received on: 17.11.2019

Accepted on: 04.01.2020

Abstract

It is the goal of every obstetrician to ensure that mother and fetus tolerate labor well. Assessing the fetal response to labor is challenge. Fetal surveillance during labor helps in recognizing the fetus that is not tolerating labor well and is hypoxic. Recognition of fetal compromise guides decision about appropriate intervention so that short and long-term neurological damage may be avoided. Fetal scalp blood sampling carried out if there is an abnormality in FHR. It is done to confirm the presence of fetal hypoxia and or acidemia. Two constituents that are commonly tested by this method are pH and lactate. Low pH indicates acidosis. Increased lactate is associated with hypoxia. EFM is associated with increased intervention rates which can be reduced with FBS.

Keywords: Fetus, Scalp Blood pH; Scalp Blood Lactate; Asphyxia; Acidosis.

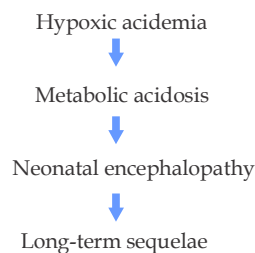
How to cite this article:

Alka B Patil, Rahul V Patil, Akshay N. Jagtap, et al. Fetal Scalp Blood Sampling: Review. Indian J Matern Fetal Neonatal Med. 2020;7(1):29-32.

Introduction

With the onset of normal labour fetus embarks on the most perilous journey it will undertake in its lifetime. Although intrapartum foetal surveillance has not been able to make this journey any easier, it has certainly helped in making it much safer than It has ever been.¹

Hypoxic injury affects the fetus in several ways. Multi organ dysfunction may result but the fetal nervous system is the most vulnerable to long-standing injury.



Aim of intrapartum fetal surveillance:

- Identification of decreasing of the fetal oxygenation
- Timely and effective intervention
- Prevention of brain injury
- To detect potential fetal harm due to decreased oxygenation during labor.

It is the goal of every obstetrician to ensure that the mother and fetus tolerate labor well. Assessing the fetal response to labor is challenge.²

FBS during first stage of labour was introduced by Saling in 1962 and was based on pH analysis, empirically based on the some 80 cases. Saling suggested pH cut-off values and consequently recommended interventional guidelines that are regarded as gold standard with respect to intrapartum fetal distress. FBS is an invasive procedure, require ruptured membranes and sufficiently dilated cervix.¹



Two constituents that are commonly tested by this method are:

- pH
- Lactate

Both are indicators of acid-base homeostasis.

Low pH indicate acidosis. Increased lactate are associated with hypoxia.(2)

Contraindications of FBS

- Clear evidence of severe fetal compromise
- Fetal bleeding disorders
- Maternal infections (HERPES, HIV, Hepatitis)
- <34 weeks of gestation
- Face presentation
- Suspected intrauterine sepsis.(3)

Analysis of pH

- Relatively large amount of blood (30-50 ul)
- Sampling failure rate: 11-20%
- Lactate analysis:5µl blood.³
- Using a lancet blood sampling is obtained from fetal Scalp. Blood sample is checked for pH.

Table 1: pH Sampling Results

pH results	Action
≥ 7.25	Repeat the FBS in 1 hour if the cardiotocography (CTG) abnormality persists, or sooner if required.
7.21-7.24	Repeat the FBS in 30 minutes time, or consider delivery if a significant fall has occurred since the previous sample
≤7.2	Delivery is indicated.

Results are influenced by site of scalp puncture. Blood sample at the site of caput(venous edema on fetal scalp) gives rise to more acidotic pH compared to samples from the normal area of the scalp. Presence of meconium in the amniotic fluid significantly reduces the predictive value of FSBS for fetal acidosis. This is because the meconium contains bile acids which may alter the pH due to contamination. Taking a fetal scalp blood sampling during uterine contraction results in more acidotic values than taking scalp blood sampling between uterine contractions. Results are influenced by contamination of the amniotic fluid.In response to hypoxia release of catecholamines would result in intense vasoconstriction. Resultant diversion

of oxygen from peripheral tissue(fingers, scalp, toes) to internal organs would lead to peripheral acidosis in all peripheral tissues. This is a normal compensatory mechanism to cope with hypoxia.(5)

Fetal Scalp Lactate Measurement:

Nordstom et al. (1995) suggested that pre-acidemia is mainly of respiratory origin and use of lactate in fetalsurveillance might decrease the incidence of unnecessary interventions. Maternal and foetal lactate concentrations increase with duration of active bearing down.(1)

Advantages of Fetal Scalp Lactate Measurement:

- Less sampling failure
- Smaller quantity of blood suffices (5 µl) compared to pH measurement (35 µl)
- Caput formation does not significantly alter the correlation between values obtained at FBS and values in central fetal circulation.¹

Table 2: Lactate Sampling Results

Lactate result	Action
< 4.2 mmol/L	Normal. Repeat FBS in 1 hour if the cardiotocography (CTG) abnormality persists, or sooner if required
4.2 - 4.8 mmol/L	Pre-acidaemia. Repeat the FBS in 30 minutes time, or consider delivery if a significant rise has occurred since the previous sample
4.8 mmol/L	Acidaemia. Delivery is indicated

Complications of FBS

- Drainage of CSF
- Haemorrhage
- Scalp abscess⁵

Discussion

The purpose of intrapartumfetal surveillance is to avoid fetal death due to birth asphyxia. FBS may not be needed in all cases. The need for FBS would be detected by clinical situation and CTG. The clinician should make an assessment of:

- Degree of pathological features observed
- The clinical fetal reserve
- Parity
- Cervical dilatation
- Rate of progress of labor

- Possibility of immediate instrumental vaginal delivery.⁷

Based on the assessment, FBS could be performed if necessary. The NICE guidelines recognise FFM as a screening tool and recommended use of FBS.

FBS is less likely to be successful when:

- Cervical dilatation is less than 3 cm
- Head is not fixed in the pelvis and is likely to move away with the pressure of application of amnioscope or at the time of making the incision.⁷

Reliable FBS result provide guideline for further management.

The main objective of intrapartum fetal monitoring is to identify the foetus at risk of an adverse outcome, based on how the foetus reacts to stress before it comes compromised. Although a majority of congenital neurological handicaps are not related to intrapartum events, intrapartum hypoxia continues to be responsible for the proportion of handicaps and for a significant number of perinatal death even in developed world.¹

Fetus faces stress during labor. Fetal surveillance during labour helps in recognizing the fetus that is not tolerating labour well and is hypoxic acidemic. Recognition of fetal compromise guides decision about appropriate intervention so that short and long-term neurological damage may be avoided. Fetal scalp blood sampling carried out if there is an abnormality in FHR. It is done to confirm the presence of fetal hypoxia and or acidemia.²

Limitations of Fetal Scalp pH Measurement

- Technical difficulties in collecting sufficient quantity of blood for analysis
- Procedure takes 18 minutes to perform therefore cannot be used in acute fetal distress
- The result is valid only for a short period of time
- Measurements may however be inaccurate in presence of moderate to severe degree of fetal scalp edema
- Required special equipment and is expensive.¹
- Test is cumbersome. Requires special equipment and is expensive
- It has poor sensitivity and positive predictive value identification of hypoxicischemic

encephalopathy

- Test is not used commonly in many institutions.²

During labour dystocia and in presence of meconium, amniotic fluid often contains high levels of lactate or bile acid that can be enormously interpreted as fetal acidemia.⁸

Duration of fetal hypoxia is closely related to the incidence of fetal brain damage. As it is not possible to distinguish clinically between hypoxia and other causes for the appearance of classical signs of fetal distress (abnormal rise or fall in FHR or the passage of meconium) it is vital to solve this problem urgently. This will enable the obstetrician to rescue the fetus at risk by the prompt delivery or to avoid unnecessary Cesarean Section. Fetal scalp blood acid base studies help to confirm the diagnosis of fetal hypoxia and differentiate the serious from less significant FHR changes.

Since fetal distress is characterized by a circulatory as well as metabolic response of the foetus to the hypoxia both the biophysical and biochemical approaches are complementary in assessing the fetus during the labour. Usually fetal acidosis does not develop without fetal abnormalities or meconium staining. However fetal death may suddenly occur without any warning sign.⁹

RCTs are needed to evaluate FBS using other screening tests. Better understanding of the pathophysiology of intrapartum fetal metabolic acidosis is needed with the development of novel tests that are safer and have higher efficacy, fulfilling all criteria of an optimal screening test.⁹

Conclusion

Scalp pH measurements have to be taken repeatedly at regular intervals in case of continuation of labour, depending upon the severity of FHR abnormalities. FBS for either pH or lactate reduces the need for operative deliveries.¹⁰

FBS may be used for suspicious or pathological CTG tracings. In case of ominous CTG pattern, immediate instrumentation is required and FBS is not recommended. In case of difficult sampling condition the use of lactate analysis is associated with lower failure rates and lesser time to obtain measurements, compared with pH. EFM is associated with increased intervention rates which can be reduced with FBS.¹¹

References

1. Rohan D'souza and Sabaratnam Anilkumaram, Intrapartum fetal monitoring, Sir Sabarantam Anilkumaram, Geeta Arjun Leonie K Penna. The management of labour, University Press third edition
2. Intrapartum fetal surveillance, Lakshmi Seshadri Gita Arjun Essentials of Obstetrics, Walters Kluwer first edition 2015
3. RANZCOG. Intrapartum fetal surveillance clinical guidelines third edition May 2014.
4. Whit worth MK, Bricker L. How to perform intrapartum fetal blood sampling. British Journal of Hospital Medicine 2006;67(9): M162-4.
5. E Chandraharan. Fetal scalp blood sampling during labour: is it a useful diagnostic test or a historical test that no longer has a place in modern clinical obstetrics? BJOC International Journal of obstetrics and gynaecology 2014;121(9): 1056-62.
6. Wiberg-Itzel E, Lipponer C, Norman M, et al. Determination of pH or lactate in fetal scalp blood in management of intrapartum fetal distress: Randomised controlled multicentre trial. BMJ 2008;336(7656):1284-7.
7. Rohana Naththotuwa Muhunthon K Sabarantam Anil Kumaran, Fetal surveillance in labour, Amarnath Bhide Sabarantham Anil Kumaran, Kaizad R. Damaniya Shirish Daftary, Arias practical guide to high risk pregnancy and delivery Elsevier 4th edition.
8. E Chandraharan. FBS during labor. Acta obstetrics and gynaecology.
9. Shirish N Doetary Sudip Chakravarti Muralidhar V Pai Prahlad Kushtag. Holland and Brews Manual of obstetrics, Elsevier 4th edition.
10. Alfirevic Z, Devane D, Gyte GML. Continuous cardiotocography (CTG) as a form of electronic fetal monitoring (EFM) for fetal assessment during labour. Cochrane Database Syst Rev 2013;5:CD006066.
11. Bruno Carbonne, Kelly Pons, Emeline Maisonneuve, Foetal scalp blood sampling during labour for pH and lactate measurements. Best Practice & Research Clinical Obstetrics and Gynaecology 2016;30:62.