

## A Rare Cause of Homocysteinemia Related Myocardial Infarction

Avikal Sharma<sup>1</sup>, Priya Govil<sup>2</sup>, Kishalay Datta<sup>3</sup>

### Author's Affiliation:

<sup>1</sup>MEM Resident, <sup>2</sup>Associate Consultant, <sup>3</sup>HOD, Department of Emergency Medicine, Max Hospital, Shalimar Bagh, New Delhi, Delhi 110088, India.

### Corresponding Author:

**Priya Govil**, Associate Consultant, Department of Emergency Medicine, Max Hospital, Shalimar Bagh, New Delhi, Delhi 110088, India.

E-mail: [drpriyasharma5@gmail.com](mailto:drpriyasharma5@gmail.com)

Received on 09.12.2019,

Accepted on 27.12.2019

### Abstract

A 18-years male came in ED with c/o chest pain since 3–4 hours before arrival in ED, ECG show ST elevation in anterior leads, lead 1 and avl suggestive of anterior wall myocardial infarction. patient homocystine level was 41.5  $\mu\text{mol}/\text{lt}$  (normal range 6–15  $\mu\text{mol}/\text{lt}$ )

**Keywords:** Myocardial Infarction; Hyperhomocysteinemia.

How to cite this article:

Avikal Sharma, Priya Govil, Kishalay Datta. A Rare Cause of Homocysteinemia Related Myocardial Infarction. Indian J Emerg Med. 2019;5(4):247–248

### Introduction

Cardiovascular diseases (CVD) as the name suggests, comprise of diseases of the heart and blood vessels. Cardiovascular disease is believed to account for one third of all deaths worldwide, and the prevalence is still on the rise CVD is among the diseases with multiple contributing factors, hence making it difficult to pinpoint a particular factor alone. The main factor that is of relevance to this study is Homocystine Coronary artery disease is the narrowing or blockage of the arteries and vessels that supply oxygen and nutrients to the heart. Homocysteine has been recognized as a risk factor as early for the presence of atherosclerotic vascular disease and hypercoagulability states A study also showed that elevated homocysteine

was associated with higher risk of coronary artery disease in patients with chronic renal dysfunction. The homozygous mutation of C, S can cause severe hyperhomocysteinemia where homocysteine concentration is up to 40-fold of the normal levels. This disease occurs in approximately 1 of 100,000 live births When untreated, a vascular event (stroke, myocardial infarction, other thromboembolic complication) occurs in about half of these patients before the age of 30. Another cause of rare, genetically mediated severe hyperhomocysteinemia is due to homozygous mutations of MTHFR.<sup>1-4</sup>

### Case Report

A 18-year male came in ED with c/o chest pain since 3–4 hr before arrival in ED, ECG show st elevation



This work is licensed under a Creative Commons Attribution-NonCommercial-ShareAlike 4.0.

in anterior leads, lead 1 and avl suggestive of anterior wall myocardial infarction. pt homocystine level was 41.5  $\mu\text{mol/l}$  (normal range 6-15  $\mu\text{mol/l}$ )

Physical examination revealed the stable, chest pain, conscious, oriented, vitally stable: Pulse: 70/min, BP: 120/90 MMH, RR:16/min, Temperature: afebrile, Sp:99% on room air,

Neurological, Cardiovascular, Respiratory examinations were insignificant.

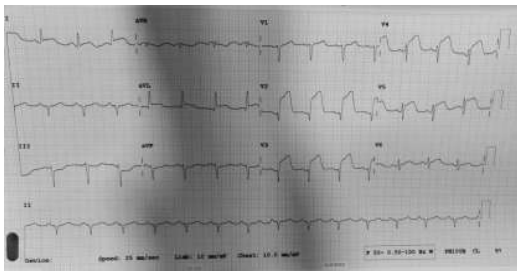


Fig. 1:

Cardiology consultations were requested and the patient was admitted and taken to cathlab and coronary angiography was done which s/o single vessel disease (LAD- mid LAD after small diagonal 100% occlusion) primary PCI to LAD done that went uneventfully. He was discharged in a stable condition after 3 days.

#### Course in the Hospital and Outcome

After initial management and ECG done which s/o anterior wall MI, The loading dose was given with tab ecosprin 325 mg, tabbrilinta 180 mg, tabatorvas 80 mg. patient was immediately taken for cathlab. coronary angiography was done which s/o single vessel disease (LAD- mid LAD after small diagonal 100% occlusion). Pthomocystine level send to lab which s/o homocystine level was 41.5  $\mu\text{mol/l}$  (normal range 6-15  $\mu\text{mol/l}$ )

#### Discussion

Risk factors associated with Myocardial infarction include Age factor, tobacco use, high blood

pressure, hyperlipidemia, obesity, diabetes, metabolic syndrome, family history of myocardial infarction. In addition to these broad categories, right ventricular (RV) infarction and cardiogenic shock and may lead to sudden death.

#### Conclusion

Why should an emergency physician be aware of myocardial infarction. This is because it is life threatening condition. Hyperhomocystenemia play important role in myocardial infarction. Homocystine level should be evaluated in patients with absence of traditional risk factors for recognition of early diagnosis and treatment.

An early diagnosis of myocardial infarction is important as a delay in the correct diagnosis is known to increase the risk of morbidity and mortality.

It has been reported that initial ECG and CAG can give more accurate information about the exact position of the vessels involved which can be treated appropriately before complications develop.

#### References

1. Judith E. Tintinalli, J. Stephan Stapczynski, O. John Ma, et al. Tintinalli's Emergency Medicine, 8<sup>th</sup> ed. united states: McGraw-Hill Education 2016.
2. Rosen's Emergency Medicine: Concepts and Clinical Practice, 9<sup>th</sup> edition, Ron walls, Robert hocksburger, Marianne gausche hill, 2017 edition.
3. Moussaissa book of emergency medicine, 2<sup>nd</sup> edition, Tina Cardoza, Nasir, Zain, Russel hall, 2019 edition.
4. Wyatt JP, Illingworth RN, Graham CA. Oxford hand book of emergency medicine, 4<sup>th</sup> edition.