

# Ganglion Impar Chemical Neurolysis in Advanced Carcinoma Prostate

Firoz Khan N<sup>1</sup>, Navita Purohit<sup>2</sup>

## How to cite this article:

Firoz Khan N, Navita Purohit/Ganglion Impar Chemical Neurolysis in Advanced Carcinoma Prostate/Indian J Anesth Analg. 2023;10(1)23-26.

## Abstract

Ganglion impar is a solitary ganglion located retroperitoneally at the end of para vertebral sympathetic chain and usually in front of sacrococcygeal joint. Solitary or metastatic tumour in the surrounding tissues causes poorly localized pain. This is a case of 76 year old male, who was diagnosed to have advanced metastatic adenocarcinoma prostate, presented with pain over the lower back radiating to ano rectal region since last 4 months. He had severe pain during defecation which could not be controlled with conventional high-dose opioid application but with transcoccygeal Ganglionimpar chemical neurolysis. We reasoned that blocking the ganglion impar could attenuate this sympathetically maintained pain, which would lead to a reduction in the consumption of opioids, lessen constipation, and lead to an improvement in the patient's quality of life.

**Keywords:** Carcinoma prostate; Ganglion impar; Phenol; Chemical Neurolysis; Fluoroscopic.

## INTRODUCTION

In colon, cervix, vagina, vulva, ovary, prostate cancers, pressure and invasion of the solitary/metastatic tumor cause poorly localized pain in perianal or perineal tissues particularly during defecation. High dose opioids applied for pain control cause constipation and increases pain

during defecation even more. It is usually problematic to break this vicious circle and control pain.<sup>1</sup> Impar ganglion is a solitary ganglion located retroperitoneally at the end of paravertebral sympathetic chain, usually in front of sacrococcygeal joint. Afferent sensory fibers of perineal, distal rectum, anus, distal urethra, vulva, distal 1/3 of vagina end here. Successful but transient pain control by blockage of this ganglion is possible.<sup>2,3</sup> The aim of this case report is to present a patient with advance prostate cancer, whose severe pain during defecation could not be controlled with conventional high dose opioid application but with transcoccygeal ganglion impar chemical neurolysis.

## CASE HISTORY

76 year old male referred by surgical oncologist, presented with pain over the lower back radiating

**Author's Affiliation:** <sup>1,2</sup>Fellow, Department of Pain Medicine, Palliative and Rehabilitation, Kokilaben Dhirubhai Ambani Hospital, Mumbai 4100053, Maharashtra, India.

**Corresponding Author:** Firoz Khan N, Fellow, Department of Pain Medicine, Palliative and Rehabilitation, Kokilaben Dhirubhai Ambani Hospital, Mumbai 4100053, Maharashtra, India.

E-mail: [firozkhann43@gmail.com](mailto:firozkhann43@gmail.com)

Received on: 26.12.2022

Accepted on: 03.01.2023



This work is licensed under a Creative Commons Attribution-NonCommercial-ShareAlike 4.0.

to ano rectal region since last 4 months, associated with generalised weakness. He was diagnosed to have metastatic adenocarcinoma prostate in January 2021 and was started on abiraterone (anti-testosterone) and LNRH agonists. Initially PSA came down and then increased and disease progressed in July 2021 and started on Docetaxel, completed 3 cycles and stopped due to toxicity. His pain started as low back pain 4 months back, gradual in onset, sharp, intense, constant pulling type of pain with burning sensation over Ano rectal region. Pain was continuous with bursts in-between, lasting for 20-30 minutes each attack, with an average of more than 3 attacks per day especially after passing motion. NRS score at each episodes: 9/10, NRS score at rest 6-7/10, sleep disturbed due to pain during the night. Consulted many doctors and was on NSAIDs, opioids, pregabalin and muscle relaxants. The patient reported taking three to four tablets of morphine 10 mg daily with only minimal-to-moderate relief (equivalent to a NRS score of 7-9). Moreover, secondary to the opioid use, the side effect of constipation further increased his pain symptoms, which further led to painful defecation, increased discomfort with ambulation, depression, and consequently a diminished quality of life. His recent PET CT scan was suggestive of advance prostate cancer with focal skeletal lesions in pelvis, cervical, dorsal and lumbar vertebrae. There was no motor or sensory deficits.

A decision was made to do diagnostic block of the ganglion impar using a transcoccygeal technique. Informed consent was obtained from the patient. Intravenous access was obtained, and the patient was transferred to the procedure room in a wheelchair, where he was then placed prone on the procedure table. Standard monitors were applied, and oxygen was administered via nasal cannula. The low back and sacrococcygeal area was prepped and draped using sterile technique and disinfection with 2% chlorhexidine. Under fluoroscopic guidance, the coccygeal 1-2 vertebrae were identified. Two milliliters of 1% lidocaine preparation was used for skin and subcutaneous infiltration. Under fluoroscopic guidance, a 22-gauge spinal needle was advanced toward the first and second coccygeal interspace. The needle was inserted into this interspace just until the tip was anterior to the sacrococcygeal junction. The 1-2 vertebrae were again identified, and correct needle placement was confirmed by anterior/ posterior and lateral fluoroscopic views and injection of contrasting agent (iohexol). Good layering of 2 mL of iohexol was documented in the precoccygeal area, with no evidence of additional vascular or

epidural spread (Fig. 1-3).

A solution of 1% lignocaine 3ml was then injected

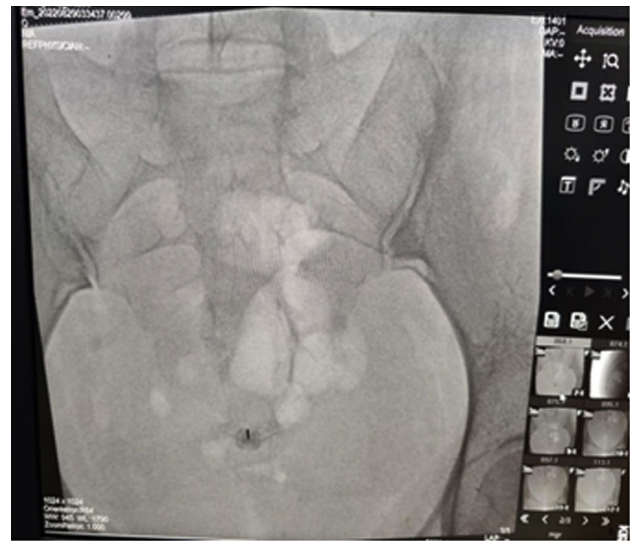

Fig. 1: Needle position in AP view

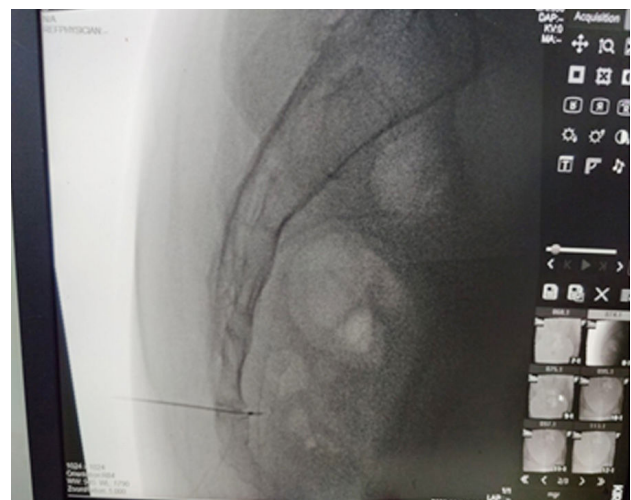


Fig. 2: Needle position in Lateral view

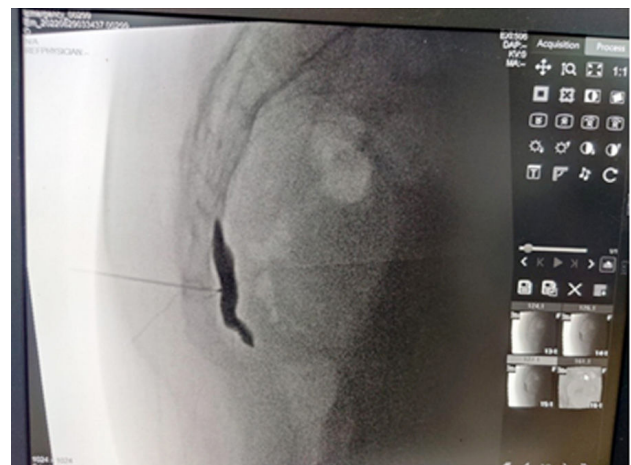


Fig. 3: Contrast spread in lateral view

into the precoccygeal space. Patient had good pain relief post procedure and NRS score reduced to 2/10. After a week, Ganglion impar neurolytic block was done using 4ml of 6% of phenol after confirming adequate dye spread under fluoroscopic guidance.

After 15 min, the patient reported excellent pain relief (NRS:1/10) and he was able to sit and ambulate comfortably without any pain. Medicines were slowly withdrawn over 2-4 weeks period. Patient revisited after 12 weeks, his symptoms reduced and was able to ambulate without much difficulties.

## DISCUSSION

The ganglion impar, also known as the ganglion of Walther or the sacrococcygeal ganglion, is the most caudal ganglion of the sympathetic trunk.<sup>3</sup> Fluoroscopically guided ganglion impar blockage may be a safe and highly efficacious treatment modality used in the treatment of chronic pelvic pain.<sup>4-7</sup> The utility of ganglion impar blockade has been well documented.<sup>7</sup> In fact, in current published literature, there are very few complications reported from this block.<sup>9</sup> However, the potential or theoretical risks of this procedure include unintentional damage to pelvic structures, mild pain at the injection site, and infection. In addition, discitis and needle breakage appear to be other unusual complications reported by practitioners. Fortunately, the ganglion impar block is a fairly straightforward procedure in the hands of a skilled practitioner, and its complications are rare.<sup>10</sup> Of note, some of the potential, but rare, side effects of corticosteroids injection include elevated blood sugars, weight gain, arthritis, stomach ulcers, and a transient decrease in the immune system.<sup>11</sup>

The most recent literature highlights that the ganglion impar block has also been successfully used to treat non-malignancy associated perineal pain from various etiologies, including sacral postherpetic neuralgia, spinal cord malformations, and failed back surgery syndrome.<sup>6</sup> In instances where the use of local anesthetics does not provide long lasting relief, a neurolytic block of the ganglion may be attempted.<sup>8</sup> In previous techniques, 8-10% phenol or 50% alcohol has been used for neuroablation.<sup>12</sup> The use of this block could have significant implications in reducing the pain and increasing the quality of life in patients with chronic pelvic and perineal pain.<sup>7</sup>

## CONCLUSION

We present a case of a gentleman with chronic pelvic pain due to advance carcinoma prostate. Pain got relieved with diagnostic ganglion impar block using 1% lignocaine followed by therapeutic chemical neurolysis with 6% phenol under fluoroscopy guidance. A ganglion impar block should be considered for sympathetically maintained pelvic or anorectal pain. Prospective, controlled studies have documented that the ganglion impar block can provide complete or partial pain relief in most patients with perineal pain secondary to cancer.<sup>5,9</sup>

## REFERENCES

1. Agarwal-Kozlowski K, Lorke DE, Habermann CR, Am Esch J, Beck H. CT-guided blocks and neuroablation of the ganglion impar (Walther) in perineal pain. *Anatomy, technique, safety and efficacy.* Clin J Pain 2009; 25: 570-6.
2. Christo PJ, Mazloomdoost D. Interventional pain treatments for cancer pain. *Ann N Y Acad Sci* 2008; 1138: 299-328.
3. Do NL, Nagle D, Poylin VY. Radiation proctitis: Current strategies in management. *Gastroenterol Res Pract* 2011;2011:917941 epub 9 pages.
4. Eker HE, Cok OY, Kocum A, Acil M, Turkoz A. Transsacrococcygeal approach to ganglion impar for pelvic cancer pain: A report of 3 cases. *Reg Anesth Pain Med* 2008;33(4):381-2.
5. Bas, ag˘ an Mog˘ ol E, T˘urker G, Kelebek Girgin N, U˘çkunkaya N, Sahin S. Blockade of ganglion impar through sacrococcygeal junction for cancer-related pelvic pain. *Agri* 2004;16(4):48-53.
6. Kuthuru M, Kabbara AI, Oldenburg P, Rosenberg SK. Coccygeal pain relief after transsacrococcygeal block of the ganglion impar under fluoroscopy: A case report. *Arch Phys Med Rehabil* 2003;84:E24.
7. Toshniwal GR, Dureja GP, Prashanth SM. Transsacrococcygeal approach to ganglion impar block for management of chronic perineal pain: A prospective observational study. *Pain Physician* 2007;10(5): 661-6.
8. Waldman SD. Atlas of interventional pain management. In: Hetherington P, Kim L, eds. *Ganglion of Walther (Impar) Block: Trans-Coccygeal Technique*, 3rd edition. Philadelphia, PA: Saunders Elsevier; 2009:483-90. 665mGanglion Impar Block Treats Proctitis Pain
9. Plancarte R, Velazquez R, Patt RB. Neurolytic blocks of the sympathetic axis. In: Patt RB, ed. *Cancer Pain*. Philadelphia, PA: Lippincott-Raven; 1993:419-42.
10. 10 Munir MA, Zhang J, Ahmad M. A modified needle in needle technique for the ganglion impar

- block. *Can J Anaesth* 2004;51:915-7.
11. Pereira PL, Günaydin I, Duda SH, et al. Corticosteroid injections of the sacroiliac joint during magnetic resonance: Preliminary results. *J Radiol* 2000;81(3): 223-6.
  12. Benzon HT, Hurley RW, Deer T. Chapter 58: "Chronic pain management." In: Barash PG, Cullen BF, Stoelting RK, Cahalan MK, Stock MC, eds. *Clinical Anesthesia*, 6th edition. Philadelphia, PA: Lippincott Williams & Wilkins; 2009:1506-19.

