

Original Research Article

Categorisation and Risk Stratification of Salivary Gland FNA Using the Milan System for Reporting Salivary Gland Cytopathology

Hemavathy R¹, Sriram V², Erli Amel Ivan³¹Postgraduate, ²Assistant Professor, ³Professor and Head, Department of Pathology, Sri Manakula Vinayagar Medical College and Hospital, Kalitheerthalkuppam, Madagadipet, Puducherry 605107, India.

Corresponding Author:

Sriram V, Assistant Professor, Department of Pathology, Sri Manakula Vinayagar Medical College and Hospital, Kalitheerthalkuppam, Madagadipet, Puducherry 605107, India.

E-mail: sriram11988@gmail.com

Received on 23.03.2020

Accepted on 20.04.2020

Abstract

Context: Fine needle aspiration cytology is an effective tool for diagnosing and differentiating the nonneoplastic and neoplastic salivary gland lesions. However, there are varied reporting formats which hinders the effective management. The proposed Milan system for reporting salivary gland cytology provides a platform for uniform reporting and effective communication among pathologists and clinicians. **Aim:** The aim and objectives of this study is to evaluate and categorize the previously diagnosed salivary gland lesions under Milan reporting system, to determine the risk of malignancy for each diagnostic categories and to ascertain the diagnostic accuracy of FNA in differentiating benign from malignant lesions. **Material and Methods:** This retrospective study was conducted in a tertiary care center for 2 years from 2017 to 2019. The cytological diagnosis of salivary gland lesions were recategorised as per Milan reporting system. The risk of malignancy and diagnostic accuracy were evaluated by comparing with histopathological diagnoses. **Results:** Of 106 cases, highest number of cases were observed in nonneoplastic category (51.9%). Histopathological follow-up was available for 51.8% cases. The risk of malignancy was highest in malignant category (100%) and no risk of malignancy were identified in nondiagnostic and nonneoplastic categories. The diagnostic accuracy for differentiating benign and malignant lesions was 94.55%. **Conclusion:** This study emphasizes the need for utility of the proposed Milan classification system in routine cytology reporting of salivary gland lesions. This six-tier classification is useful particularly when difficulty arises due to overlapping morphological features.

Keywords: Salivary gland; Milan system; Risk of malignancy.

How to cite this article:

Hemavathy R, Sriram V, Erli Amel Ivan. Categorisation and Risk Stratification of Salivary Gland FNA Using the Milan System for Reporting Salivary Gland Cytopathology. Indian J Pathol Res Pract. 2020;9(1 Part II):228-233.

Introduction

Fine needle aspiration (FNA) cytology is a well recognised preoperative investigation in the management of salivary gland lesions.^{1,2} It is an

useful diagnostic tool in identifying the wide spectrum of salivary gland lesions ranging from nonneoplastic to neoplastic benign and malignant lesions, thereby limits surgical procedures to neoplastic lesions.³ It is preferred over biopsy

as it is minimally invasive, cost effective and has negligible complications.^{3,4} There are few diagnostic challenges and pitfalls owing to low cellularity, rarity of lesions, heterogenous and overlapping cytomorphological features between subtypes of tumor.^{5,6} In addition, differences in the varied reporting terminologies and formats had adverse impact on management of these cases.⁷

Milan System for Reporting Salivary Gland Cytology (MSRSGC) was first proposed in 2015 by the American Society of Cytopathology (ASC) and International Academy of Cytopathology (IAC).⁸ It was presented in 2017 at the ASC symposium and got published subsequently in 2018 with the intent to standardize and provide uniform reporting format.⁹ This system also facilitated effective communication with the clinicians by providing the risk of malignancy for each category and specific management strategies.⁷ This newly introduced system needs further validation on its applicability for wide acceptance.¹⁰

The current study was carried out to evaluate and categorise the previously diagnosed salivary gland lesions under Milan reporting system, to determine the risk of malignancy for each diagnostic categories and to ascertain the diagnostic accuracy of fine needle aspiration in differentiating benign and malignant lesions.

Materials and Methods

This was a retrospective analytical study done in the department of pathology at a tertiary care center for a period of 2 years from 2017 to 2019. A total of 106 consecutive cases were retrieved and evaluated. Detailed clinical history and examination findings were noted. The gross appearance of the aspirate was noted and smears were prepared. Cystic fluids aspirated were centrifuged and sediment smears were prepared. Repeat aspiration or ultrasound guided aspiration was done for difficult cases. Air dried smears were stained with May-Grunwald-Giemsa (MGG) stain and alcohol fixed smears were stained using haematoxylin and eosin (H & E) stain and Papanicolaou stain. Histopathological

confirmation was available for 54 cases. All the biopsy specimens were previously fixed in 10% formalin, processed, stained with H&E and subjected for histopathological evaluation.

The FNA cytological diagnoses were categorised as per Milan system as follows: I - nondiagnostic (ND), II - nonneoplastic (NN), III - atypia of undetermined significance (AUS), IV - neoplastic category, subdivided into benign and undetermined malignant potential (UMP), V- suspicious for malignancy (SFM), VI - malignancy.

Histopathological diagnosis was considered as the gold standard and the risk of malignancy (ROM) was calculated for each category. The ROM is briefly defined as the ratio of malignant follow-up cases to the total number of FNA follow-up cases for that category. The sensitivity, specificity, positive predictive value, negative predictive value and diagnostic accuracy were calculated on the basis of histopathological correlation.

Results

A total of 106 cases were retrieved. Males (59/106) were slightly more affected than females (47/106), with ratio being 1.3:1. The mean age of patient was 42 years. Overall highest incidence was found between 41 to 50 years. Parotid was the most commonly involved gland ($N = 82, 77.4\%$) followed by submandibular gland ($N = 16, 15.1\%$) and minor salivary glands ($N = 8, 7.5\%$).

The salivary gland cytological diagnoses were categorised under MSRSGC recommendations. The results were as follows: nondiagnostic in 4 (3.8%) cases, nonneoplastic in 55 (51.9%) cases, AUS in 6 (5.7%) cases, benign in 25 (23.6%) and UMP in 3 (2.8%) cases. SFM was observed in 2 (1.9%) cases and malignant in 11 (10.3%) cases. Highest number of cases were in nonneoplastic lesion, of which chronic sialadenitis was the most frequently observed lesion. The most common lesion in benign and malignant categories were pleomorphic adenoma and mucoepidermoid carcinoma respectively (Table 1).

Table 1: Spectrum of salivary gland lesions categorised as per Milan system

Categories	No. of cases	Percent
I Nondiagnostic	04/106	3.8%
II Nonneoplastic	55/106	51.9%
Sialadenosis	15	
Acute sialadenitis	3	
Chronic sialadenitis	26 (24.5%)	

Categories	No. of cases	Percent
Acute suppurative lesion	3	
Chronic granulomatous lesion	2	
Lymphoepithelial lesion	4	
Epidermoid cyst	1	
Reactive lymphoid hyperplasia	1	
III Atypia of undetermined significance	6/106	5.7%
IV Neoplastic	28/106	
a. Benign	25/28	23.6%
Pleomorphic adenoma	14 (13.2%)	
Warthin tumor	5	
Basal cell adenoma	1	
Lipoma	5	
b. Undetermined malignant potential	3/28	2.8%
V Suspicious for malignancy	2/106	1.9%
VI Malignant	11/106	10.3%
Mucoepidermoid carcinoma	8 (7.5%)	
Carcinoma ex pleomorphic adenoma	1	
Squamous cell carcinoma	1	
Lymphoproliferative disease	1	

Histopathology (HP) follow-up correlation was obtained for 54 (51%) cases. Out of which, concordance was observed in 41 (76%) cases and 13 (24%) cases were discordant. Among the nondiagnostic cases, one case had surgical follow-up and was diagnosed to be pleomorphic adenoma (no ROM). In the nonneoplastic category (11/55), one case turned out to be benign pleomorphic adenoma and one as malignant low grade mucoepidermoid carcinoma (ROM - 9.1%). In AUS (4/6), three cases were benign and one came out as mucoepidermoid carcinoma (Fig. 1a and b; 2a and b) (ROM- 25%). In the benign category (23/25), all were concordant except one which turned out to be a mucoepidermoid carcinoma (ROM-4%). Among

the UMP (3/3) cases, two cases turned out to be benign and one malignant (Fig. 3a and b) (ROM-33.33%). In SFM, both the cases turned out to true malignancy with a ROM of 100%. Among the malignancy (10/11) cases, all were truly malignant (ROM - 100%) (Table 2). However, subtyping error was observed in three benign lesions and two malignant cases.

The sensitivity, specificity, positive predictive value (PPV), negative predictive value (NPV) and diagnostic accuracy in this study using Milan system for diagnosing lesions were calculated as 75%, 100%, 100%, 90.48% and 92.59% respectively.

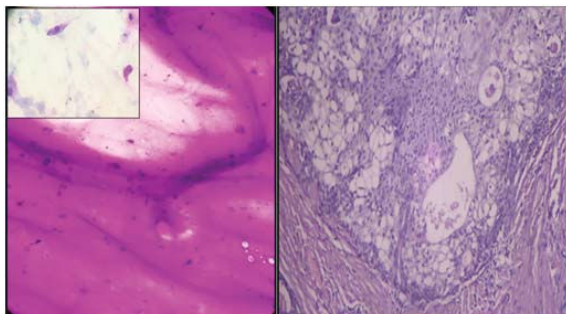


Fig. 1 (a and b): Case of AUS with abundant mucinous material (MGG, 400x) (Inset shows very few scattered squamous cells) shows features of mucoepidermoid carcinoma in histology (H&E, 400x).

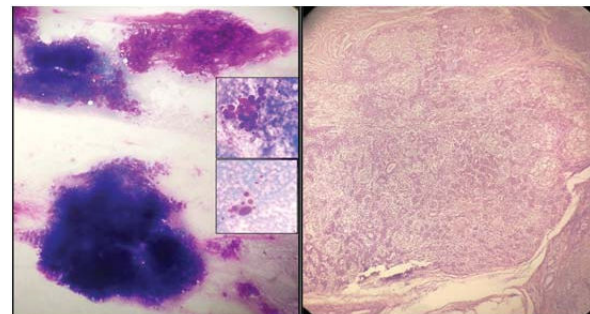


Fig. 2 (a and b): Case of pleomorphic adenoma with scattered atypical cells seen (insets) (MGG, 100x), classified under AUS shows features of pleomorphic adenoma in histology (H&E, 100x).

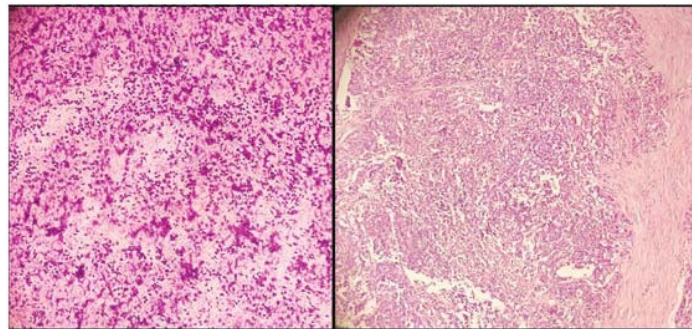


Fig. 3 (a and b): Case of UMP with high cellularity and predominant myoepithelial cells having uniform bland nuclear morphology (MGG, 100x), diagnosed as epithelial-myoepithelial carcinoma in histopathology (H&E, 100x).

Table 2: Cytohistological correlation with associated risk of malignancy for each category

Category	Histopathology correlation (N)	Histology				
		Concordance	Benign (No. of cases)	%	Malignant (No. of cases)	Percent
Non-diagnostic	1/4	-	Pleomorphic adenoma (1)	100	-	-
Non-neoplastic	11/55	9 (81.8%)	Pleomorphic adenoma (1)	9.1	MEC (1)	9.1
AUS	4/6	-	Lymphoepithelial sialadenitis (1) Warthin tumor(1) Pleomorphic adenoma (1)	75	MEC (1)	25
Neoplastic (26/28)						
Benign	23/25	22 (96%)	-	-	MEC (1)	4
UMP	3/3	-	Basal cell adenoma(1) Warthin tumor(1)	66.67	EMC (1)	33.33
SFM	2/2	-	-	-	MEC (2)	100
Malignancy	10/11	10 (100%)	-	-	-	100
Total	54/ 106	41 (76%)	7	13	6	11

N = Number of cases, MEC- Mucoepidermoid carcinoma, EMC- Epithelial myoepithelial carcinoma.

Discussion

FNAC is a highly reliable method of diagnosing salivary gland lesions and has gained widespread acceptance as the first-line invasive management of salivary gland lesions.¹¹⁻¹³ However, there prevails uncertainty about the varied reporting formats. Therefore, ASC and IAC put forth the MSRSGC for reporting into six categories along with brief management plan to facilitate uniformity and better understanding of the clinicians to provide individualized management.^{7,10}

In this study, males had a slight preponderance with a male: female ratio of 1.3:1, which was

comparable to few other studies.^{4,8,14,15} In our study, parotid gland was the most commonly involved followed by submandibular and minor salivary glands. Similar findings were observed in studies by Jaiswal P et al., Wu et al. and Hollyfield JM et al.^{3,6,16} Nonneoplastic was the frequently encountered lesion followed by benign and malignant lesions, similar to study by Kala et al.⁴ Chronic sialadenitis (24.5%) was the most common nonneoplastic, pleomorphic adenoma (13.2%) was the commonest benign and mucoepidermoid carcinoma (7.5%) was the commonest malignant lesion identified in this study. A quite similar observation was made by Karuna V et al.⁷

Histopathological correlation was available only for 51% of cases, the possible reason could be due to higher number of nonneoplastic lesions observed in this study most of which were treated conservatively. Among the four false negative cases, one case of chronic sialadenitis under nonneoplastic category on cytology turned out to be low grade mucoepidermoid carcinoma. Chronic sialadenitis and non-specific sialadenitis are identified as pitfalls, as there are chances of missing aspiration of the actual target malignant lesion.^{12,17,18} One case had abundant thick mucin with very occasional scattered squamous cells, categorized under AUS turned out to be low grade mucoepidermoid carcinoma (MEC). Low grade MEC has been identified as one of the common cause for false negative diagnosis.¹⁸ Other case in AUS had features of pleomorphic adenoma with many scattered atypical cells came out as pleomorphic adenoma in histopathology confirmation. In UMP category, the case was highly cellular and had predominant

myoepithelial cells with bland morphology which came out as epithelial myoepithelial carcinoma. Some of the causes that have attributed to the false negative cases in cytohistopathological correlation were—sampling errors, scanty material despite repeated aspirations probably due to nature of the lesion, cystic changes, scattered atypical cells and metaplastic changes raising the suspicion of malignancy in a benign lesion, bland nuclear morphology of most low grade tumors, abundant thick mucin with scant cellularity, hindering the diagnosis of a malignant lesion.¹⁷⁻¹⁹ Sampling from multiple sites is necessary to avoid misdiagnosis owing to intratumoral heterogeneity.²⁰ No false positive case was reported in this study. The false positive rate ranges from 0 to 10%, identified from the literature.^{3,21} The risk of malignancy identified in this study is well within the range identified by MSRSGC and variations of ROM among different studies were observed in the indeterminate categories (AUS, UMP, SFM)^{4,7,14,16,21} (Table 3).

Table 3: Comparison of risk of malignancy with Milan system and other studies

Studies	ND	NN	AUS	Benign	UMP	SFM	Malignant
MSRSGC	25 (0-67)	10 (0-20)	10-35	<5 (0-13)	35 (0-100)	60 (0-100)	90 (57-100)
ROM range ⁷							
Hafez NH et al. ¹⁴	33.33	11.8	37.5	2.1	44.4	60	100
Hollyfield et al. ¹⁶	38	17	33	4	33	67	100
Amita K et al. ²¹	-	6.25	100	-	25	100	100
Kala C et al. ⁴	25	5	20	4.4	33.3	85.7	97.5
Present study	-	9.1	25	4	33.33	100	100

The sensitivity, specificity, PPV, NPV and diagnostic accuracy of this study were in congruence with other studies^{5,8} (Table 4). The sensitivity of FNA in differentiating benign and malignant

salivary gland ranges from 54 to 88% and a high specificity ranging from 88 to 100% is mentioned in other studies.^{5,7,20}

Table 4: Statistical comparison of the present study with other studies

Statistical data	Present study	Katta et al. ⁵	Kumari et al. ⁸
Sensitivity	75%	73.34%	78.57%
Specificity	100%	95.56%	98.84%
Positive Predictive Value	100%	84.62%	97.06%
Negative Predictive Value	90.48%	91.49%	90.43%
Diagnostic accuracy	92.59%	90%	92.19%

The limitations of the present study were its retrospective design, smaller sample size and limited number of cases with histopathological follow-up. However, the MSRSGC is still not adopted in most institutions and ours. Therefore we attempted to validate retrospectively the application of MSRSGC system for analysing the false negative cases and cases with overlapping cytomorphological features.

Conclusion

The increased diagnostic accuracy in the present study supports that the Milan system for reporting salivary gland cytology is of utmost help in guiding the pathologists and clinicians in categorising the lesions and to assess the risk of malignancy and triage the patients to provide proper and specific management.

References

- Cibas ES, Ducatman BS. Cytology: diagnostic principles and clinical correlates. 3rd ed. Philadelphia, PA: Saunders/Elsevier. 2009.p.285.
- Griffith CC, Schmitt AC, Pantanowitz L, et al. A pattern-based risk-stratification scheme for salivary gland cytology: A multi-institutional, interobserver variability study to determine applicability: Salivary FNA interobserver variability. *Cancer Cytopathol* 2017;125(10):776-85.
- Jaiswal P, Sharma M, Ahmad F, et al. Risk-based stratification of salivary gland lesions on cytology: An institutional experience. *Iran J Pathol* 2018;13(02):220-8.
- Kala C, Kala S, Khan L. Milan system for reporting salivary gland cytopathology: An experience with the implication for risk of malignancy. *J Cytol* 2019;36(3):160-4.
- Katta R, Chaganti DP. Application of the Milan system of reporting salivary cytopathology: A retrospective cytohistological correlation study. *J Dr NTR Univ Health Sci* 2019;8(1):11-7.
- Wu HH, Alruwaili F, Zeng B-R, Cramer HM, Lai C-R, Hang J-F. Application of the Milan system for reporting salivary gland cytopathology: A retrospective 12-year bi-institutional study. *Am J Clin Pathol*. 2019;151(6):613-21.
- Karuna V, Gupta P, Rathi M, et al. Effectuation to cognize malignancy risk and accuracy of fine needle aspiration cytology in salivary gland using "Milan System for Reporting Salivary Gland Cytopathology": A 2 years retrospective study in academic institution. *Indian J Pathol Microbiol* 2019;62(1):11-6.
- Kumari M, Sharma A, Singh M, et al. Milan system for reporting of salivary gland cytopathology: To recognize accuracy of fine needle aspiration and risk of malignancy: A 4 years institutional study. *International Journal of Research and Review* 2020;7(2):201-7.
- Rossi ED, Faquin WC. The Milan System for Reporting Salivary Gland Cytopathology (MSRSGC): An international effort toward improved patient care-when the roots might be inspired by Leonardo da Vinci. *Cancer Cytopathol* 2018;126(9):756-66.
- Song SJ, Shafique K, Wong LQ, et al. The utility of the Milan System as a risk stratification tool for salivary gland fine needle aspiration cytology specimens. *Cytopathology* 2019;30(1):91-8.
- Mishra S, Ray S, Sengupta M, et al. A cytohistological correlation in salivary gland swelling with special reference to the proposed Milan system. *Indian J Pathol Microbiol* 2019;62(3):379-83.
- Viswanathan K, Sung S, Scognamiglio T, et al. The role of the Milan System for Reporting Salivary Gland Cytopathology: A 5-year institutional experience. *Cancer Cytopathol* 2018;126(8):541-51.
- Tommola E, Tommola S, Porre S, et al. Salivary gland FNA diagnostics in a real-life setting: One-year-experiences of the implementation of the Milan system in a tertiary care center. *Cancers* 2019;11(10):1589.
- Hafez NH, Abusinna ES. Risk assessment of salivary gland cytological categories of the milan system: a retrospective cytomorphological and immunocytochemical institutional study. *Turk J Pathol* 2019;1-12
- Jain R, Gupta R, Kudesia M, et al. Fine needle aspiration cytology in diagnosis of salivary gland lesions: A study with histologic comparison. *CytoJournal* 2013;10:5.
- Hollyfield JM, O'Connor SM, Maygarden SJ, et al. Northern Italy in the American South: Assessing interobserver reliability within the Milan System for reporting salivary gland cytopathology. *Cancer Cytopathol* 2018;126(6):390-6.
- Pukhrabam GD, Laishram RS, Marina A, et al. Study of the cytomorphology of salivary gland lesions using the Milan system of reporting in a tertiary care hospital. *J Evid Based Med Healthc* 2019;6(46):2926-30.
- Rohilla M, Singh P, Rajwanshi A, et al. Three-year cytohistological correlation of salivary gland FNA cytology at a tertiary center with the application of the Milan system for risk stratification. *Cancer Cytopathol* 2017;125(10):767-75.
- Ali NS, Akhtar S, Junaid M, et al. Diagnostic accuracy of fine needle aspiration cytology in parotid lesions. *ISRN Surg* 2011;2011:1-5.
- Nuzhat S, Yasin SB, Nazia B, et al. Cytology of salivary gland lesions with histopathological correlation: a three year study in a tertiary care hospital. *Int J Curr Res* 2019;11(3):2368-73.
- Amita K, Rakshitha HB, Singh A, et al. Evaluation of accuracy of Milan system for reporting salivary gland cytology: Review of morphology and diagnostic challenges in each category. *J Cytol* 2020;37:18-25.

