

The Forgotten Thyroxine Medication

Josephine Leshiini¹, Kishalay Datta²

How to cite this article:

Josephine Leshiini, Kishalay Datta/The Forgotten Thyroxine Medication/Indian J Emerg Med 2023;9(4):221-223.

Abstract

Hypothermia is a rare finding in the Indian subcontinent. Hypothermia may be a presentation of Myxedema coma, which needs prompt diagnosis and emergency management. In this case report, we discuss an elderly female with symptoms of Myxedema coma, the difficulty in diagnosis and management in the emergency department of our hospital.

Keywords: Myxedema Coma; Hypothyroidism; Thyroxine; Lower Limb Edema.

INTRODUCTION

Hypothyroidism is a common condition of thyroid hormone deficiency, which is readily diagnosed and managed, but is potentially fatal in severe cases if untreated. There are large variations in the clinical presentation, the definition of hypothyroidism is predominantly biochemical. Thyroid hormone replacement with levothyroxine is the standard treatment for patients with hypothyroidism.¹

Author's Affiliation: ¹Post Graduate Trainee, ²Director and HOD, Emergency Medicine, Max Super Speciality Hospital, Shalimar Bagh 110088, New Delhi, India.

Corresponding Author: Kishalay Datta, Director and HOD, Emergency Medicine, Max Super Speciality Hospital, Shalimar Bagh 110088, New Delhi, India.

E-mail: josephineleshiini@gmail.com

Received on: 07-03-2023

Accepted on: 10-04-2023

CASE

A 55 year old female was wheeled into the Emergency department with complaints of generalized weakness with fatigability with poor appetite for the last 7 days. Her attendants stated that she has been feeling lethargic for the last 3 days and her body feels very cold on touch. They brought her to the hospital as she was very drowsy and complained of breathing difficulty at home. On examination, we saw an obese, hypothermic woman on the emergency bed looking very lethargic and restless, her feet were swollen up till the knees (which according to her relatives developed in the last 5-7 days duration). She was lying on the bed with signs of neck rigidity. Her past medical history was suggestive of hypothyroidism, old cerebrovascular accident, recurrent urinary tract infections, recently started on dementia control medications. Her son stated that she has been not taking any medications for the last 10 days (including thyroxine 200 micrograms).

The patient was infused with warm normal saline with strict input-output charting. The



This work is licensed under a Creative Commons Attribution-NonCommercial-ShareAlike 4.0.

provisional diagnosis ranged between sepsis, dementia, meningitis/encephalitis, urinary tract infection leading to sepsis, myxedema coma. The patient was started on broad spectrum antibiotics, hydrocortisone injection was started at a lower dose, injection levothyroxine 200 micrograms was given. Patient was admitted to the critical care unit. Blood reports evaluation revealed - Total leucocyte count: 21500/uL (normal 3500-11000/uL), hemoglobin 8.6 g/dL (normal 12-16 g/dL), C-reactive protein 15.59 mg/L (normal < 5 mg/L), sodium 129 mEq/L (normal 134-148 mEq/L), and potassium 3.3 mEq/L (normal 3.6-5.0 mEq/L), thyroid stimulating hormone one 105.54 uIU/mL (normal 0.35-5.50 uIU/mL) and low free T4 0.12 ng/dL (normal 0.93-1.56 ng/dL).

Patient treatment continued with correction of thyroid level, treatment of the sepsis and warming the body, anti dementia therapy. After 5 days of continued medications, the patient's condition improved and she was discharged home healthy with counseling and educating patients relatives. The further follow-ups were continued as advised, patient medications were continued and she recovered well.

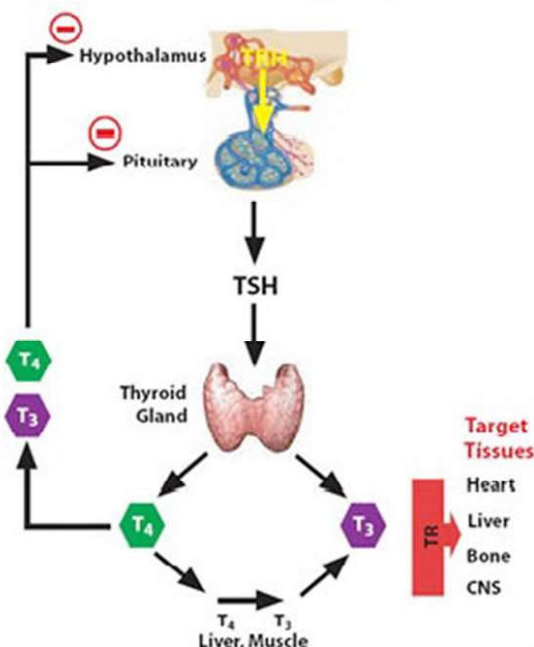
DISCUSSION

This was a case of Myxedema coma and after corrective measures, the patient was discharged. Hypothyroidism is classified as primary (due to thyroid hormone deficiency), secondary (due to Thyroid Stimulating Hormone deficiency), tertiary (due to thyrotropin releasing hormone deficiency), and peripheral (extrathyroidal). Central hypothyroidism (including both secondary and tertiary) and peripheral hypothyroidism are rare and account for less than 1% of cases.⁵

The thyroid gland, anterior pituitary gland, and hypothalamus comprise a self-regulatory circuit called the hypothalamic pituitary thyroid axis. The main hormones produced by the thyroid gland are thyroxine or tetraiodothyronine (T4) and triiodothyronine (T3).

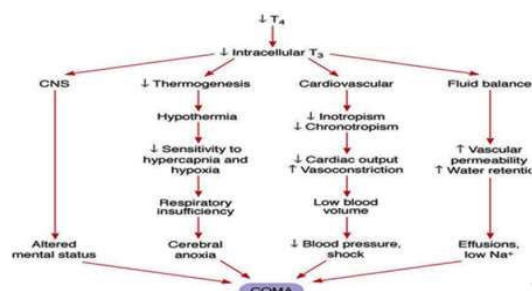
Myxedema coma was first described in the late 1900s as an outcome of long standing untreated and severe hypothyroidism and has become a rare condition nowadays.⁶ Myxedema coma leads to hypothermia, altered mental status, bradycardia, progressive lethargy, which can eventually result in multiple organ dysfunction syndrome and death. Therefore, early initiation of thyroid hormone therapy and other supportive measures is necessary.⁷

Hypothalamic-Pituitary-Thyroid Axis



Myxedema coma can be precipitated by an acute event such as sepsis, myocardial infarction, cerebrovascular accident, exposure to cold, gastrointestinal bleeding, trauma or certain medications like lithium, amiodarone and opioids⁸, or sudden cessation of thyroxine medications.

According to a recent study, combined therapy for myxedema coma consists of administration



with T4 (levothyroxine) and T3 (triiodothyronine, liothyronine) rather than T4 alone. Intravenous T4 200 to 400 mcg once a day, followed by 50 to 100 mcg daily until the patient can take T4 orally, and initial dose of 5 to 20 mcg intravenous T3, followed by 2.5 to 10 mcg every 8 hours at the same time are recommended. T3 is discontinued if clinical improvement is noted and the patient is stable. Also, administration of high doses of glucocorticoids is suggested (e.g. intravenous hydrocortisone 100 mg every eight to twelve hours for two days,

then lower doses) as long as coexisting adrenal insufficiency is excluded.⁹ The reported mortality rate is around 25% to 60%, and higher risks in old age patients with cardiac complications, persistent hypothermia, sepsis, poor conscious level and delayed treatment are possible risk factors for poor prognosis.¹⁰ Undoubtedly, myxedema coma is a true endocrine emergency and needs early recognition and proper treatment.

CONCLUSION

Myxedema coma is a rare complication of hypothyroidism and can be precipitated by various medical events like sepsis, or sudden cessation of thyroxine medication. Myxedema coma is fatal if not corrected promptly. The diagnosis of myxedema coma is difficult and needs necessary clinical skills and knowledge and immediate medical management must be started and hypothyroidism should be corrected.

REFERENCES

1. Åsvold BO, Vatten LJ, Bjørø T. Changes in the prevalence of hypothyroidism: the HUNT Study in Norway. *Eur J Endocrinol* 2013; 169:613-20.
2. Jordan Richard M. Myxedema coma: Pathophysiology, Therapy, and Factors Affecting Prognosis *Medical Clinics of North America*. 1995;79(1) doi: 10.1016/s0025-7125(16)30091-8.
3. Wartofsky Leonard. Myxedema Coma *Endocrinology and Metabolism Clinics of North America*. 2006 Dec;35(4) doi: 10.1016/j.ecl.2006.09.003.
4. Nicoloff John T. Thyroid Storm and Myxedema Coma *Medical Clinics of North America*. 1985 Sep;69(5) doi: 10.1016/s0025-7125(16)31002-1.
5. Persani L. Clinical review: Central hypothyroidism: pathogenic, diagnostic, and therapeutic challenges. *J Clin Endocrinol Metab* 2012; 97: 3068-78.
6. Beynon J, Akhtar S, Kearney T. Predictors of outcome in myxoedema coma. *Crit Care* 2008; 12: 111.
7. Wiersinga WM. Myxedema and coma (severe hypothyroidism) In: De Groot LJ, Chrousos G, Dungan K, *et al.*, eds. *Endotext*. South Dartmouth, MA: MD Text.com, 2000.
8. Mathew Vivek, Misgar Raiz Ahmad, Ghosh Sujoy, Mukhopadhyay Pradip, Roychowdhury Pradip, Pandit Kaushik, Mukhopadhyay Satinath, Chowdhury Subhankar. Myxedema Coma: A New Look into an Old Crisis *Journal of Thyroid Research*. 2011;2011 doi: 10.4061/2011/493462.
9. Ross DS, Cooper DS, Mulder JE. Myxedema coma. 2016 UpToDate. Apr 26, 2019.
10. Hylander Britta, Rosenqvist Urban. Treatment of myxoedema coma factors associated with fatal outcome *Acta Endocrinologica*. 1985 Jan;108(1) doi: 10.1530/acta.0.1080065.