

## A Comparative Study of Levobupivacaine and Levobupivacaine with Dexmedetomidine in USG Guided Axillary Block for Elbow, Forearm and Hand Surgeries

S Syed Thahir Hussain<sup>1</sup>, P Mageswari<sup>2</sup>

<sup>1</sup>Assistant Professor <sup>2</sup>Professor, Institute of Anesthesiology and Critical Care, Govt. Rajaji Hospital, Madurai Medical College, Madurai, Tamil Nadu 625020, India.

### Abstract

**Background and Aims:** The present clinical study was conducted to evaluate the onset of analgesia, degree of sensory and motor blockades, duration of analgesia and complications between Levobupivacaine and Levobupivacaine with Dexmedetomidine in USG guided axillary brachial plexus block. **Methods:** The study was conducted on 60 ASA 1 and 11 patients of either sex posted for various elective or emergency surgeries of the upper limb involving elbow, forearm and hand surgeries. The subjects were divided into two groups, Group A receiving axillary brachial plexus block with 0.5% Levobupivacaine alone and Group B receiving Levobupivacaine with Dexmedetomidine 1 µg/kg. **Results:** The onset of sensory and motor blockades were quicker in Group B compared to Group A. Both these findings were statistically significant. Both the duration of sensory and motor blockades were longer in Group B compared to Group A which were statistically significant. Time taken for starting of regression was more in Group B compared to Group A but this finding was not statistically different. All other parameters related to duration of anesthesia including time taken for full motor and sensory recovery were longer in Group B compared to Group A. There were statistically significant differences in the duration of complete analgesia, duration of effective analgesia and time of first pain medication were longer in Group B compared to Group A. **Conclusion:** The onset, quality, intensity of sensory and motor blockades and the duration of analgesia is both clinically and statistically significantly prolonged in Levobupivacaine with Dexmedetomidine group.

**Keywords:** Levobupivacaine; Dexmedetomidine; USG; Axillary brachial plexus block.

### How to cite this article:

S Syed Thahir Hussain, P Mageswari. A Comparative Study of Levobupivacaine and Levobupivacaine with Dexmedetomidine in USG Guided Axillary Block for Elbow, Forearm and Hand Surgeries. Indian J Anesth Analg. 2019;6(6 Part - II):2182-2187.

### Introduction

The techniques of peripheral nerve blockade were developed early in the history of anesthesia. The US surgeons Halsted and Hall described the injection of cocaine in to peripheral sites which include the

ulnar, musculo cutaneous, supra trochlear and infra orbital nerves for minor surgical procedures in the 1880s.<sup>1</sup> James Leonard Corning recommended the use of an esmarch bandage in 1885 to arrest the local circulation; prolong the cocaine induced block, decrease uptake of that local anesthetic

**Corresponding Author:** Dr. S Syed Thahir Hussain, Assistant Professor, Institute of Anesthesiology and Critical Care, Govt. Rajaji Hospital, Madurai Medical College, Madurai, Tamil Nadu 625020, India..

E-mail: [dr\\_thahir@yahoo.co.in](mailto:dr_thahir@yahoo.co.in)

Received on 26.08.2019, Accepted on 23.10.2019



This work is licensed under a Creative Commons Attribution-NonCommercial-ShareAlike 4.0.

from tissues. This concept was further developed by FW Braun who substituted epinephrine, a chemical tourniquet in 1903. He also introduced the term conduction anesthesia in his textbook on Techniques of local anesthesia.

Peripheral nerve blockade remains a well-accepted component of comprehensive anesthetic care. Its role has expanded from the operating site into the arena of post-operative and chronic pain management. Skillful application of peripheral neural blockade broadens the anesthesiologists' range of options in providing optimal anesthetic care. The axillary approach to the brachial plexus is the most popular because of its ease, reliability and safety. Blockade occurs at the level of the terminal nerves and blockade of musculocutaneous nerve is always ensured with the use of ultrasound.

## Materials and Methods

This was a randomized prospective double blinded control study conducted in a tertiary care teaching hospital. Following institutional ethical committee approval, sixty patients of the age group 18 to 60 years of both sexes with ASA Grade I and Grade II requiring both elective and emergency surgery of the elbow, forearm & hand between January 2014 and February 2015 were selected and divided into two groups of 30 patients each. Patients with history of bleeding disorders, local infection at the site of block, documented neuromuscular disorders, respiratory compromise, known allergy to local anesthetic drugs and ASA Grade III and IV were excluded from the study. Allocation to different regimens are:

Group A: Patients receiving 0.5% Levobupivacaine (20 ml = 100 mg) + normal saline.

Group B: Patients receiving 0.5% Levobupivacaine (20 ml = 100 mg) + Dexmedetomidine.

The same volume of saline (placebo) corresponding to that of Dexmedetomidine was added to Levobupivacaine for the Levobupivacaine + placebo group (Group A). The drugs used were Levobupivacaine hydrochloride at a dose of 2 mg/kg in a concentration of 0.5% and Dexmedetomidine at a dose of 1 µg/kg. The concentration was fixed and dose and volume varied according to the body weight of the patient. The sample size was calculated by taking 30 patients as study and 30 patients were taken as control (total 60 patients).

The procedure was explained to the patient and informed consent was obtained. The patients were brought to the operation theatre and advised to lie in

supine position with due comfort on the operating table. Preop heart rates (HR), Non Invasive Blood Pressure (NIBP), Saturation Pressure of Oxygen ( $S_pO_2$ ) were recorded. Intravenous access was secured in the nonoperative limb and a crystalloid was started. All the blocks in both the groups were administered by different anesthesiologists who were blinded from the drug composition of the local anesthetic mixture used for the axillary block. 60 patients were randomly allotted into 2 groups, Group A and Group B. All the patients received injection Midazolam 0.05 mg/kg and injection Fentanyl 0.5 µg/kg intravenously 15 minutes before the procedure. Axillary brachial plexus block was given with the patient lying supine with the arm abducted from the body at 90° and flexed in the elbow joint at 90°<sup>2</sup>

The axillary sheath was identified and approached under Sonosite M-Turbo high frequency linear probe and using a 50 mm insulated needle with an extension catheter for injecting the LA solution.<sup>3</sup> After repeated negative aspirations, 5 ml of local anesthetic solution which contains either Levobupivacaine alone or Levobupivacaine with Dexmedetomidine was injected at each nerve like radial, ulnar, median and musculocutaneous.<sup>4</sup> Totally 20 ml given with either 0.5 ml normal saline or 0.5 ml of dexmedetomidine which is 50 µg. The intra and postoperative assessment was done by an anesthesiologist who had no idea of the drug given. The onset of analgesia was recorded as the interval between the time of injection and the development of loss of sensation to pin prick. The dermatome areas corresponding to the median nerve, radial nerve, ulnar nerve and musculocutaneous nerves were checked at every minute till there was complete loss of sensation. The onset and completion of analgesia was tested by loss of sensation to pin prick. The effect of analgesia after injection was graded as Grade 1 (good), Grade 2 (inadequate) and Grade 3 (very poor). The conclusion of Grade 2 was arrived when any one of the segments supplied by four major nerves (radial, ulnar, median and musculocutaneous nerves) did not have loss of sensation even after 30 minutes of the block. They were supplemented with mask ventilation with nitrous oxide, IV ketamine 0.5 mg/kg/fentanyl (1 µg/kg) and midazolam (0.02 mg/kg). When there was no loss of sensation in more than one nerve segment then it was considered a failed block. In such case, general anesthesia was provided. Sedation component was recorded by the Ramsay Sedation Score. The duration of sensory block was called as the time interval between the end of drug injection

and the complete resolution of pin prick sensation on all nerve segments. All patients were monitored for complications (if any) during the intraoperative period and up to forty eight hours post-operatively.

The degree of motor blockade was assessed by modified Bromage scale for upper extremities (3-point scale) as Grade 1 (complete block) Grade 2 (near complete) and Grade 3 (no block). Duration of analgesia was recorded with the help of Visual Analog Scale (VAS) which ranges from 0 to 10. This scale was noted per every 60 minutes post-operatively till it comes to 5.

Detailed descriptive analysis of socio demographic and clinical parameters was done in the first step. The quantitative variables were presented as mean  $\pm$  standard deviation and the categorical variables were presented as frequency and percentage. All the basic parameters were compared between the two treatment groups. The time taken for onset of anesthesia, duration of anesthesia, analgesic requirement etc. was considered as primary outcome parameters. The hemodynamic and respiratory parameters of the patients during and after anesthesia were considered as secondary outcome variables. Both the outcomes were compared between the two treatment groups by calculating mean differences. The statistical significance and 95% CI of these differences was assessed by unpaired *t*-test. Microsoft excel and IBM SPSS (Statistical Package for Social Sciences) version 21 were used for statistical analysis Unpaired *t*-test was applied for demographic data, hemodynamic parameters, onset and duration of sensory and motor blockade and duration of analgesia. For assessing the quality Fisher exact test was applied. *p* - value was considered significant if  $< 0.05$  and highly significant if  $< 0.001$ .

## Results

A comparative study of Levobupivacaine alone and Levobupivacaine with Dexmedetomidine in axillary brachial plexus block was carried out on sixty patients divided into two groups of thirty patients each in the age group of 18 to 60 years. The following observations were made. A total of sixty participants were included in the final analysis. Out of the 60, 34 (56.7%) were randomized to intervention Group A, to receive 0.5% Levobupivacaine + Normal saline (0.5 ml). The remaining 26 (43.3%) received intervention Group B i.e. 0.5% Levobupivacaine + Dexmedetomidine (0.5 ml = 50  $\mu$ g) (Table 1).

**Table 1:** Descriptive analysis intervention groups (n = 60)

Treatment group	Frequency	Percent
Group A (0.25% Levobupivacaine + Normal saline (0.5 ml))	34	56.7
Group B (0.25% Levobupivacaine + Dexmedetomidine (0.5 ml))	26	43.3
Total	60	100

The socio demographic and anthropometric parameters were comparable between two groups. Only minor differences existed in the mean values of age and proportion of females (Table 2).

**Table 2:** Descriptive analysis of socio demographic parameters in study groups (n = 60)

Parameter	Group A	Group B
Age [mean (SD)]	37.47 (SD)	34.19 (SD)
Sex		
Male [Frequency (%)]	26 (%)	18 (%)
Female [Frequency (%)]	8 (%)	8 (%)
Anthropometry		
Weight [mean (SD)]	67.59 (SD)	1.67 (SD)
Height [mean (SD)]	67.85 (SD)	1.68 (SD)

**Table 3:** Comparison of onset and duration of anesthesia in both study groups (n = 60)

Parameter	Group	Mean	Mean difference	<i>p</i> value	95% CI	
					Lower	Upper
Onset of Sensory Blockade (minutes)	Group A	0.07	0.04	$< 0.001$	0.032	0.048
	Group B	0.03				
Onset of Motor Blockade	Group A	0.10	0.03	$< 0.001$	0.023	0.037
	Group B	0.07				
Duration of Sensory Block	Group A	8.91	-4.70	$< 0.001$	-5.31	-4.09
	Group B	13.61				
Duration of Motor Block	Group A	5.82	-1.82	$< 0.001$	-2.37	-1.28
	Group B	7.65				

The onset of sensory blockade (mean difference 0.04 minutes, *p* - value  $< 0.001$ ) and motor blockade (mean difference 0.03 minutes, *p* - value  $< 0.001$ ) were quicker in Group B compared to Group A. Both these findings were statistically significant. Both the duration of sensory blockade (mean difference 282 minutes, *p* - value  $< 0.001$ ), and motor blockade (mean difference 108 minutes, *p* - value  $< 0.001$ ) were longer in Group B compared to Group A and both these findings were statistically significant (Table 3).

Time taken for starting of regression (mean difference -1.37 minutes, *p* - value  $< 0.108$ ) was more in Group B compared to Group A, but this finding was not statistically different. All other parameters related to duration of anesthesia including time

**Table 4:** Comparison of other anesthesia related parameters in both study groups = 60

Parameter	Group	Mean	Mean difference	p value	95% CI	
					Lower	Upper
Time Taken for starting of Regression	Group A	0.53	-1.37	.108	-3.37	0.22
	Group B	2.31				
Time of full sensory recovery (mnts)	Group A	10.01	-4.78391	<0.001	-5.42451	-4.14322
	Group B	14.79				
Time of full motor recovery (mnts)	Group A	6.85	-1.946	<0.001	-2.574	-1.318
	Group B	9.70				

taken for full motor and sensory recovery were longer in Group B compared to Group A. These differences were statistically significant. There were statistically significant differences in the duration of complete analgesia, duration of effective analgesia and time of first pain medication between the study groups. All these parameters were longer in Group B compared to Group A (Table 4).

Onset of analgesia was immediate with Dexmedetomidine with Levobupivacaine (3-5 minutes) whereas the onset of analgesia took 8-10 minutes in patients with Levobupivacaine alone. The quality of analgesia was Grade I in 76.6% patients with Levobupivacaine with Dexmedetomidine whereas it was Grade I in 50% patient's receiving Levobupivacaine alone.<sup>5</sup> Degree of motor block was Grade I in 56.6% patients with Levobupivacaine with Dexmedetomidine as compared to only 26.6% patients with Levobupivacaine alone. Duration of analgesia was found to be in the range of 8-10 hours with Levobupivacaine alone, whereas duration with 14-16 hours was found with Levobupivacaine with Dexmedetomidine.<sup>6,7</sup> Complications with both the drugs were found to be mild.

**Discussion**

Regional Anesthesia is becoming more popular especially with the advent of safer drugs and techniques. Ultrasound has become more useful in the last few decades. Since, both the drugs namely, levobupivacaine and dexmedetomidine are relatively newer in peripheral nerve block procedures, an attempt has been made to compare the two. Until now, the common adjuvant used with local anesthetics was the opioids.<sup>8</sup> More recently,  $\alpha_2$  agonists have been used with good success. They improve the quality and duration of block in peripheral nerve blocks. The  $\alpha_2$  agonists act through vasoconstriction, centrally acting pain relief, anti-inflammatory effects, hyperpolarization and decrease in compound action potential (CAP) and inhibition of voltage gate of sodium pump.<sup>9</sup>

Axillary block was conducted by Edson D Carel in 1971 in pediatric age group by B. Fitz Gerald in 1976, by RK Mehta *et al.*, in 1979, Blasier and White in 1996 and Colizza and Said in 1993, and supraclavicular brachial block in combination with general anesthesia was used for micro vascular surgery in children by Inberg P *et al.*, 1995. In our study only adult patients were selected because of good patient cooperation with regard to the procedure.

All the patients have received injection Midazolam 0.05 mg/kg and injection Fentanyl 0.5  $\mu$ g/kg intravenously 15 minutes before the procedure. This premedication was comparable with Sarita *et al.* where there was no premedication whereas Amany *et al.* have used midazolam of 1-2 mg and fentanyl 50-100  $\mu$ g (not based on per kg dose) in all of their patients undergoing single shot infraclavicular block using bupivacaine with dexmedetomidine (2012).

Andrea *et al.* compared the use of ultrasound and nerve stimulator for axillary block. They found that ultrasound has supremacy in 98.5% of successful blocks. The findings of Vincent *et al.* and Christophe *et al.* also highlighted the role of ultrasound in the success of axillary block. In our study, we observed that almost all the 60 patients had Grade 1 block (Good analgesia, sedatives were given only to relieve apprehension). This was made possible by the accuracy of the ultrasound in permitting direct visualization of the nerves.

The recommended maximum dose for Levobupivacaine is 5 mg/kg body weight in peripheral nerve blocks. This dose recommendation serves only as a base upon which a person using the drug in the technique should apply a sensible judgment and make appropriate adjustment. Kenan Kaygusuz *et al.* (2012) and many others used 0.5% Levobupivacaine for axillary block (Paresthesia technique) with a dose of 200 mg (4 mg/kg) without any toxic symptoms. In our study, Levobupivacaine was used as an anesthetic agent for all the cases in a concentration of 0.5%. We used Levobupivacaine in a dose of 2 mg/kg body weight, with a total dose of

only 100 mg and 1 µg/kg of Dexmedetomidine with a maximum of 50 µg because of precise location of nerves made possible by ultrasound.

In a study of Sarita *et al.* (2012) where clonidine and Dexmedetomidine were compared in supraclavicular block, mean onset time of motor block in clonidine was 4.65 minutes whereas in Dexmedetomidine group was 3.87 minutes. The mean onset time of sensory block in clonidine group was 2.3 minutes whereas in Dexmedetomidine group was 1.7 minutes. In a study by Kenan *et al.*, when Dexmedetomidine was added with Levobupivacaine in axillary block, there was no shortening of onset of motor block whereas the onset of sensory block was shortened. Keshav Govind Rao *et al.* (2014) and Rachana Gandhi *et al.* studied the effects of Dexmedetomidine with bupivacaine in supraclavicular block. They found that there was significant reduction of onset in the duration of motor and sensory blockade.

In our study, the onset of sensory blockade (mean difference 0.04 minutes,  $p$  - value < 0.001) and motor blockade (mean difference 0.03 minutes,  $p$  - value < 0.001) were quicker in Levobupivacaine with Dexmedetomidine group compared to plain Levobupivacaine group. Both these findings were statistically significant. The mean onset time of sensory block in plain Levobupivacaine was 7 minutes whereas in Levobupivacaine with Dexmedetomidine was 3 minutes. The mean onset time of motor block with plain Levobupivacaine was 10 minutes whereas in Levobupivacaine with Dexmedetomidine group was 7 minutes. Thus, the durations of onset of sensory and motor block observed in our study are comparable with the above mentioned studies done earlier.

Amany S *et al.* compared bupivacaine alone and bupivacaine with Dexmedetomidine in ultrasound-guided single injection infraclavicular brachial plexus block. They reported that Dexmedetomidine group showed a statistically important reduced time of onset of sensory block (13.2 vs. 19.4 min,  $p = 0.003$ ), increased duration of the sensory block (179.4 vs 122.7 min,  $p = 0.002$ ), reduced time of onset of motor block (15.3 vs 22.2 min,  $p = 0.003$ ), prolonged duration of motor block (155.5 vs 105.7 min,  $p = 0.002$ ), prolonged duration of post-operative analgesia (403 vs 233 min,  $p = 0.002$ ) and reduced opioid requirements 48 hours after surgery.<sup>10,11</sup> Sarita *et al.*, Kenan *et al.* and Aliye Esmoğlu *et al.* also reported similar effects in terms of prolongation of the duration of sensory and motor blocks. In our study time taken for starting of regression (mean difference -1.37 minutes,  $p$  - value < 0.108) was

more in Levobupivacaine with Dexmedetomidine compared to group levobupivacaine alone and this finding was statistically significant. There were statistically significant differences in the duration of complete analgesia, duration of effective analgesia and time of first pain medication between the study groups. All these three parameters were significantly prolonged in the group Levobupivacaine with Dexmedetomidine.

Memis *et al.* in their study have showed that when Dexmedetomidine was added with lignocaine for Biers block, it enhances the quality of analgesia. In the study of Sarita *et al.*, the quality of analgesia was 80% in patients with Dexmedetomidine whereas it was only 40% in patients with clonidine in supraclavicular block. In our study, we graded the quality of analgesia into three grades and recorded the observations. Grade I analgesia was observed in 84.4% of patients in the levobupivacaine group whereas in the Levobupivacaine with Dexmedetomidine group, 93.6% of the patients were found to achieve Grade I analgesia.<sup>12</sup> The remaining patients in both the groups achieved Grade II analgesia. Kenan *et al.* observed that in both the groups with and without added Dexmedetomidine, 78% of patients achieved, Grade I degree of motor block.

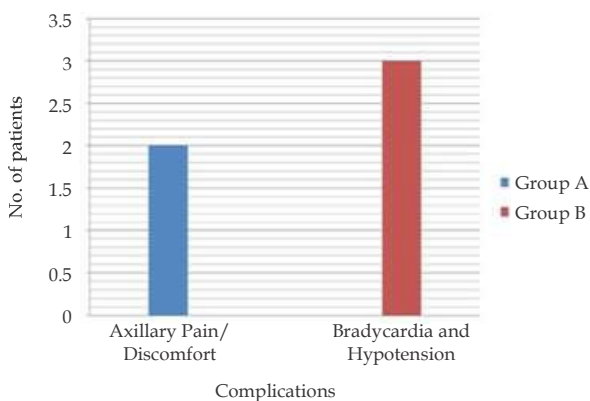
In the present study, the degree of motor blockade observed in plain Levobupivacaine was found to be Grade I (Complete block, no active movements of entire elbow, forearm and hand) in 74.6% of patients and 86.6% in levobupivacaine with Dexmedetomidine patients. Grade II motor blockade was found to be 25.4% and 13.4% in Levobupivacaine group and Levobupivacaine with Dexmedetomidine group respectively.<sup>13,14</sup> These findings are comparable to the findings of the above mentioned study.

Esmoğlu *et al.* observed bradycardia in their patient group in which 100 µg of Dexmedetomidine was used with Levobupivacaine. In our study, our observations show that the hemodynamic parameters like heart rate and blood pressure were more in the optimal range in Levobupivacaine with Dexmedetomidine group than plain Levobupivacaine group. The respiratory parameters were almost similar in both the study groups. Bradycardia and hypotension (transient) were observed in 3 patients in the Levobupivacaine with Dexmedetomidine group. The incidence of bradycardia was lesser in our study (only 3 cases) probably because of the lower dose of Dexmedetomidine we used. In our study, we used 1 µg/kg of Dexmedetomidine with a maximum of 50 µg.

Vikram Uday Lahori and Anjana Raina *et al.* (2011) have reported complications like accidental vascular puncture<sup>15</sup> in two patients of axillary block group. In our study axillary pain or discomfort was the only complication in both the groups. No other complications or significant adverse effects were observed in both the study groups, shown as (Table 5 and Fig. 1).

**Table 5:** Showing complication

Complications	Group A	Group B
Axillary pain or discomfort	2	-
Bradycardia and hypotension	-	3



**Fig. 1:** Showing complication

**Conclusion**

Based on our observations, we conclude that in ultrasound guided axillary block for elbow, forearm and hand surgeries, when compared to plain Levobupivacaine, the mixture of levobupivacaine with Dexmedetomidine produces statistically significant faster onset of sensory and motor blockade, statistically significant increase in duration of sensory and motor block, better grade of sensory and motor block, though this is not statistically significant and without much increase in the incidence of complications.

*Financial support and sponsorship:* Nil.

*Conflicts of interest:* There are no conflicts of interest.

*Permissions:* Nil

*Presentation at a meeting:* Nil

**References**

1. Miller RD, Eriksson LI, Fleisher LA, *et al.* Millers Anesthesia. 2010;7:1639-1675.

2. Ababou A, Marzouk N, Mosadiq A, *et al.* The effects of arm position on onset and duration of Axillary Brachial Plexus Block. *Anesth Analg.* 2007;104:980-81.

3. Thomas EJ, Healy L, Paul R, *et al.* A practice of Anesthesia. Oxford University Press 2003;7:154-59.

4. Gray, Henry. Anatomy of the Human Body. *Anesth Analg.* 2000;191:577-85.

5. Burlacu CL, Buggy DJ. Update on local anesthetics: Focus on levobupivacaine. *The Clin Risk Manag.* 2013;4:381-92.

6. Talke P, Tong C, Lee HW, *et al.* Effect of dexmedetomidine on lumbar cerebrospinal fluid pressure in humans. *Anesth Pain Intensive Care.* 2007;85:358-64.

7. Liisanantti O, Luukkonen J, Rosenberg PH. High-dose bupivacaine, levobupivacaine and ropivacaine in axillary brachial plexus block. *Acta Anesthesiology Scand.* 2004; 48:601-6.

8. Maton Anthea, Hopkins J, McLaughlin CW, *et al.* Human Biology and Health. *Anesth Pain Intensive Care.* 1993;6:132-44.

9. Peters A, Palay SL, Webster HD. The fine structure of the Nervous System. *J Clin Diagn Res.* 1999;3:1046-48.

10. Guo TZ, Jiang JY, Buttermann AE, *et al.* Dexmedetomidine injection into the locus ceruleus produces antinociception. *Hong Kong Med J.* 2008;84:873-81.

11. Nacif Coelho C, Correa-Sales C, Chang LL, *et al.* Perturbation of ion channel conductance alters the hypnotic response to the alpha 2-adrenergic agonist dexmedetomidine in the locus ceruleus of the rat. *Anesth Analg.* 1994;81:1527-534.

12. Hayashi Y, Guo TZ, Maze M. Hypnotic and analgesic effects of the alpha 2-adrenergic agonist dexmedetomidine in morphine-tolerant rats. *Anesth Analg.* 1996;83:606-10.

13. Asano T, Dohi S, Ohta S. Antinociception by epidural and systemic alpha (2)-adrenoceptor agonists and their binding affinity in rat spinal cord and brain. *Middle East J Anesthesiology.* 2000;90:400-407.

14. Eisenach JC, Shafer SL, Bucklin BA. Pharmacokinetics and pharmacodynamics of intraspinal dexmedetomidine in sheep. *Anesth Analg.* 1994;80:1349-359.

15. Pirotta D, Spriqqe J. Convulsions following axillary brachial plexus blockade with levobupivacaine. *Br J Anesth.* 2010;57:1187-89.