

Morphological Variations in the Insertion of Coracobrachialis with Neurovascular Entrapment in the Arm

Suganitha Balasundaram¹, Priya Ranganath²

How to cite this article:

Suganitha Balasundaram, Priya Ranganath. Morphological Variations in the Insertion of Coracobrachialis with Neurovascular Entrapment in the Arm. *Indian J Anat.* 2020;9(3):215–217.

Author's Affiliation: ¹Tutor, ²Professor and Head, Department of Anatomy, Bangalore Medical College and Research Institute, Bangalore, 560002, Karnataka, India.

Corresponding Author: Suganitha Balasundaram, Tutor, Department of Anatomy, Bangalore Medical College and Research Institute, Bangalore 560002, Karnataka, India.

E-mail: nithakeyan@gmail.com

Abstract

The coracobrachialis muscle is a muscle of arm that shows several variations in its attachments. It is inserted into the middle 5 cm of the medial border of the humerus. The median nerve crosses the brachial artery from lateral to medial near the insertion of coracobrachialis and enters the cubital fossa. The nerve and the artery may vary in their course. This study was conducted in 36 embalmed adult upper limbs of both sexes of age group between 50–80 years from the Department of Anatomy, KMC, Chennai were studied. In this study, a musculoaponeurotic tunnel formed by coracobrachialis muscle was observed in 2.8% of the specimen in which entrapment of brachial artery and median nerve was present. The abnormality reported in the present study may lead to neurovascular compression syndrome in the upper limb. Knowledge of anatomical variations in the muscular structure and its related neurovascular entrapment is important surgically for orthopaedic surgeons, plastic surgeons and also physiotherapists clinically.

Keywords: Coracobrachialis tunnel; Variations; Median nerve; Entrapment syndrome.

Introduction

The coracobrachialis muscle shows several interesting morphological and anatomical characteristics. It is the counterpart in the arm of the adductor longus/brevis/magnus of the thigh. It

arises from the apex of the coracoid process, along with the short head of biceps. It is inserted into the middle 5 cm of the medial border of the humerus. The muscle is pierced by musculocutaneous nerve and supplied by it. It is a weak flexor of the arm.^{1,2}

The brachial artery is a continuation of the axillary artery and it is superficial throughout its course in the arm along with the median nerve. The median nerve is formed by its medial and lateral root coming from medial and lateral cords of brachial plexus respectively. It descends laterally till middle of the arm. Then it crosses the brachial artery from lateral to medial near the insertion of coracobrachialis and enters the cubital fossa.

Knowledge of anatomical variations in the muscular structure and its related neurovascular entrapment is important surgically for orthopaedic surgeons, plastic surgeons and also physiotherapists clinically, hence the present study was done to observe the insertion of coracobrachialis and course of the median nerve and brachial artery.

Materials and Method

The study was conducted on 36 upper limbs from embalmed cadavers from the Department of Anatomy, KMC, Chennai. A longitudinal incision was made in the anterior surface of brachial fascia from the level of pectoralis major to the elbow. The limbs were routinely dissected for observing



This work is licensed under a Creative Commons Attribution-NonCommercial-ShareAlike 4.0.

the insertion of coracobrachialis. The course of the median nerve and brachial artery were observed. The photograph of the variations is taken for proper documentation and ready reference.

Results

In 35 specimens (97.2%), the insertion of coracobrachialis was to the middle 5 cm of the medial border of the humerus; and the course of brachial artery and the median nerve was normal, that is, the median nerve crossed the brachial artery from lateral to medial near the insertion of coracobrachialis and entered the cubital fossa.

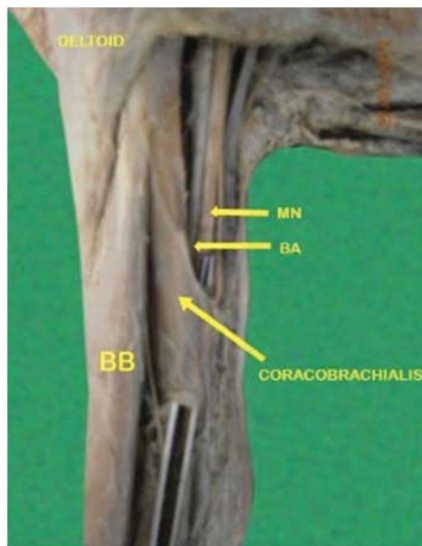


Fig. 1: Showing the Musculo aponeurotic fibres of the Coracobrachialis muscle formed a tunnel overlapping the Brachial artery and the Median nerve.

In one specimen (2.8%), a tunnel was formed by coracobrachialis muscle in the middle 1/3 of right upper limb and it was merging with the medial intermuscular septum. The length of the tunnel was measured about 3cm. It was unilateral, whereas in the left arm of the same cadaver, it was normal. An entrapment of the brachial artery and the median nerve was observed in this case in the tunnel formed by the coracobrachialis.

Discussion

Many authors (Standring S (2005), McMinn RMH (1990), Morris (1953), Ray B et al (2004)^{1,2,3,4} have quoted that the coracobrachialis muscle fibre /slips have been seen superficial to the neurovascular bundle in the arm. A recent study quoted that the coracobrachialis muscle is formed a 3 cm length

tunnel for the passage of neurovascular bundle in the arm which is very unusual.

There are three well defined entrapment syndromes involving the median nerve and its branches namely carpal tunnel syndrome, pronator teres syndrome and anterior interosseous syndrome. A few case reports (Dharap AS (1994), El- Nagger M et al (2001) were found in the literature revealed that the possible median nerve entrapment due to third head of biceps brachii.^{5,6} Even though anatomy literature hardly mentions the median nerve compression due to bicipital aponeurosis, a few researches (El- Nagger M et al 2004) say that it could be a case of high median nerve compression along with the brachial artery.⁷

The clinical implication of the slip of the Coracobrachialis is that it has the potential to cause the median nerve entrapment and the brachial artery compression. Vollala VR et al 2008 have described about the compression of the median nerve and the brachial artery with anomalous muscle/slip from the muscles such as coracobrachialis, brachialis, pronator teres, accessory head of flexor pollicis longus.⁸

In the present study, the tunnel was formed by the coracobrachialis muscle which arose from the superficial fibre with its aponeurosis 3 cm in length, extending downward and overlapping the median nerve and brachial artery to get inserted into the medial intermuscular septum.

The coracobrachialis muscle reported in this case may be explained on the basis of the embryogenesis of the muscles of the arm. Lewis WH (1910), stated that during development of the limb bud, mesenchyme of the lateral plate mesoderm develops into the intrinsic muscles of the upper limb. At certain stage of development, a single muscle-mass primordium differentiates into separate layers of muscle. Thereafter, some muscle primordia will disappear through cell death called apoptosis. The variation in the present study may be due to failure of muscle primordia to disappear during embryological development.⁹

The insertion of coracobrachialis in the form of Musculo-aponeurotic tunnel into the intermuscular septum has not been noted previously. Since the median nerve and the brachial artery passed deep to this lengthy musculoaponeurotic tunnel, percentage of compression is very high. The possibility of coracobrachialis muscle anomaly should therefore be considered as an effective clinical point of neurocompressive syndrome. Clinically these kinds of tunnels will produce symptoms in the forearm and hand also.

Conclusion

The abnormality reported in the present study may lead to neurovascular compression syndrome in the upper limb. Knowledge of anatomical variations in the muscular structure and its related neurovascular entrapment is important surgically for orthopaedic surgeons, plastic surgeons and also physiotherapists clinically. Therefore, the knowledge about this kind of rare variations are important for surgeons to avoid mislead diagnosis and treatment.

Acknowledgement

My sincere thanks to Dr. Saradha Kadhiresan, my partner D. Karthikeyan, friend R. Rajakumari, Dr. latha for their valuable help and support.

Legend:

- MN-Median nerve
- BA- Brachial artery
- BB- Biceps brachii

References

1. Standring S, Gray's Anatomy, The anatomical basis of clinical practices, 39th ed, Elsevier Churchill Livingstone,2005,855- 859.
2. McMinn RMH in Last's Anatomy Regional and applied, 8th edn, Edinburgh: Churchill Livingstone,; 1990, 79.
3. Morris, In Human Anatomy, 1953,11th edition.
4. Ray B, Rai AL, Rai TS, Clinical Anatomy, 2004, 17(8): 672-6.
5. Dharap AS, , An anomalous muscle in the distal half of the arm, Surg radiol anat,1994, 16, 97-99.
6. El- Nagger M, Al -Saggaf S, Variant of the coracobrachialis muscle and its relationships with the musculocutaneous nerve, Folia Morphol (Warsz),2001, 60; 217-224.
7. El- Nagger M, Al -Saggaf S, Variant of the coracobrachialis muscle with a tunnel for median nerve and brachial artery., Clin Anatomy, 2004, 139-143.
8. Vollala VR, Nagabhooshana S, Bhat SM, Potu BK, Gorantla VR, Multiple accessory structures in the upper limb of a single cadaver, Singapore Med J,2008,49, 254-258.
9. Lewis WH, In: Manual of embryology.vol 2, ed. Keibel F, Mall FP, Philadelphia: JB Lippincott,1910, 455-522.

