

Chronic Cholecystitis: Descriptive Histopathological Study

Rashmi HK¹, Shivamurthy YL², Suresh KK³

¹Pathologist, Shri Mallikarjuna Diagnostic Laboratory, ²Paediatrician, Vatsalya Hospital, Chikkamagaluru, Karnataka 577101, India. ³Professor, Department of Pathology, JJM Medical College, Davangere, Karnataka 577004, India.

Corresponding Author:

Rashmi HK, Pathologist, Shri Mallikarjuna Diagnostic Laboratory, Vatsalya Hospital, Chikkamagaluru, Karnataka 577101, India.

E-mail: hkrashmi30@gmail.com

Abstract

Introduction: Cholecystokinin, released from the mucosa of the proximal duodenum after fatty meals, is the most important hormone that promotes gallbladder contraction. Motilin aids in interdigestive gallbladder contraction, which occurs in tandem with giant migratory complexes of the intestines every two hours or so. Other peptides including pancreatic polypeptide and somatostatin may affect gallbladder motility. **Methodology:** After studying the gross features, representative areas were sampled for histopathological examination. The patient's name, age, sex, parity, diet and clinical features were noted. Some of the cases had been diagnosed clinically and all cases had been subjected to ultrasound examination preoperatively. **Results:** Microscopically, 65 (50%) cases had normal mucosal lining, 38 (29.2%) had atrophied lining, 18 (13.8%) had ulcerated mucosa, eight (6.2%) had hyperplastic lining and one (0.8%) had pyloric gland metaplasia. Wall was infiltrated with lymphocytes, plasma cells, eosinophils, macrophages and showed fibrosis and congested blood vessel. Mild degree of inflammation was seen in 75 (57.70%) cases, 48 (36.90%) had moderate and 7 (5.40%) had severe inflammation. **Conclusion:** Rokitansky Aschoff Sinuses was seen in all cases. One case with inspissated mucous revealed flattened lining epithelium with mild degree of inflammation.

Key words: Chronic Calculus Cholecystitis; Xanthogranulomatous Inflammation; Rokitansky Aschoff Sinuses.

How to cite this article:

Rashmi HK, Shivamurthy YL, Suresh KK/Chronic Cholecystitis: Descriptive Histopathological Study/Indian J Pathol Res Pract. 2021;10(1):21-24.

Introduction

The primary functions of the gallbladder are to store, concentrate, and release bile. Bile is constantly manufactured by the liver and must make its way to the gallbladder. This activity requires that choledochus, pancreaticus, and ampullae sphincter

muscles be maintained in a closed position so that the bile backs up the common bile duct and the cystic duct to enter the gallbladder. Bile release is triggered by cholecystokinin and vagal stimulation.¹

Na⁺ is actively transported from the basolateral region of the simple columnar epithelium of the



gallbladder into the extracellular space and is passively followed by chloride (Cl⁻) and water. To compensate for the loss of intracellular ions, apical ion channels permit Na⁺ and Cl⁻ to enter the simple columnar cells, reducing the salt (NaCl) concentration of bile. The requirement for osmotic equilibrium drives water from the bile into the simple columnar cell, thus concentrating bile.²

Approximately 800 to 1000 ml of bile flow daily into the gallbladder from the liver. Its filling results from complex neural and hormonal stimulations that result in its relaxation and the contraction and closing of the sphincter of Oddi. When the sphincter is closed, the intraluminal pressure of the bile ducts will increase as bile is continuously produced by the liver; bile will then flow into the gallbladder. When relaxed the gallbladder can store only 40 to 70 ml of bile and retains a constant intraluminal pressure. The gallbladder also has a secretory role, liberating mucosubstances from the surface epithelial cells and neck mucous glands.³ Contraction of the gallbladder is also mediated by complex neural and humoral mechanisms and occurs both after and between meals.

Cholecystokinin, released from the mucosa of the proximal duodenum after fatty meals, is the most important hormone that promotes gallbladder contraction. Motilin aids in interdigestive gallbladder contraction, which occurs in tandem with giant migratory complexes of the intestines every two hours or so. Other peptides including pancreatic polypeptide and somatostatin may affect gallbladder motility.⁴ The vagal system may also play a role both directly and indirectly in gallbladder contraction. The complicated balance of humoral and neural mechanisms involved in the working of the gallbladder is sometimes disrupted and many disease states have been implicated in the development of gallbladder dysmotility. Dysmotility may, in turn, result in gallbladder pathology.⁵

Methodology

The patient's name, age, sex, parity, diet and clinical features were noted. Some of the cases had been diagnosed clinically and all cases had been subjected to ultrasound examination preoperatively. Resected gallbladder specimens were sent either cut opened or intact in 10% formalin. Intact specimens were opened by longitudinal incision. All specimens were examined grossly for the presence of stones, growths, polyps, ulceration, and other gross abnormalities. The size of the gallbladder, shape,

external surface, wall thickness, and the nature of mucosa were noted. Chemical analysis of the gallstones was not done.

After studying the gross features, representative areas were sampled for histopathological examination. At least three tissue samples were taken from each specimen, so as to include tissue from fundus, body and neck of the gallbladder. Extra bits were taken from other representative areas like polyps, growth and other abnormal sites whenever necessary. The tissue was processed routinely to obtain paraffin sections of 5 micron thickness. They were stained with haematoxylin and eosin for microscopy. Special stains like PAS and Alcian blue (Ph 2.5) were done wherever necessary.

Sample Size: 220

Inclusion Criteria: All non-neoplastic and neoplastic epithelial lesions of the gallbladder

Exclusion Criteria: Mesenchymal and Lymphoid neoplasms

Statistical Analysis: Chi Square test and Fisher's exact test was done to know the association between different histopathological parameters and a p value of <0.05 was taken as statistically significant.

Results

In the present study, there were 130 cases of chronic calculus cholecystitis, of which 98 (75.38%) were females and 32 (24.62%) were males.

Of the 130 cases of chronic calculus cholecystitis, 36 patients were in the age group of 31-40 years followed by 31 patients in the age group of 41-50 years, 26 patients in the age group of 51-60 years, 18 patients in the age group of 21-30 years and 14 patients in the age group of 61-70 years.

All 130 patients presented with pain abdomen as the presenting symptom and 47 had vomiting and 5 had fever.

Grossly, thickened wall was seen in 97 (74.62%) cases and the remaining 33 (25.38%) had normal wall thickness. Multiple gallstones were seen in 104 (80%) cases and the rest 26 (20%) had single gallstone.

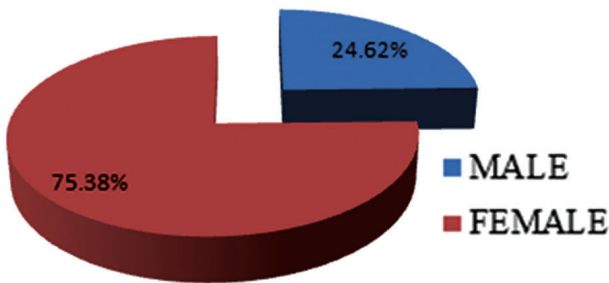
Black pigment stones were seen in 55 (42.31%) cases, mixed in 48 (36.92%), combined stones in 23 (17.69%), brown pigment stones in three (2.31%) and cholesterol stone in one (0.77%) case.

One case showed thickened gallbladder wall with inspissated mucous plug associated with gallstones.

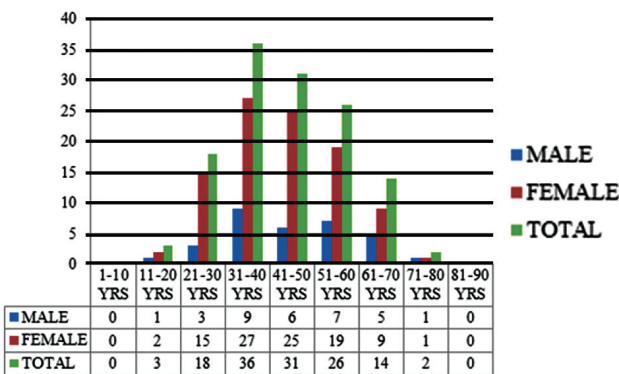
Microscopically, 65 (50%) cases had normal mucosal lining, 38 (29.2%) had atrophied lining, 18 (13.8%) had ulcerated mucosa, eight (6.2%) had hyperplastic lining and one (0.8%) had pyloric gland metaplasia. Wall was infiltrated with lymphocytes, plasma cells, eosinophils, macrophages and showed fibrosis and congested blood vessel. Mild degree of inflammation was seen in 75 (57.70%) cases, 48 (36.90%) had moderate and 7 (5.40%) had severe inflammation.

RokitanskyAschoff Sinuses was seen in all cases. One case with inspissated mucous revealed flattened lining epithelium with mild degree of inflammation.

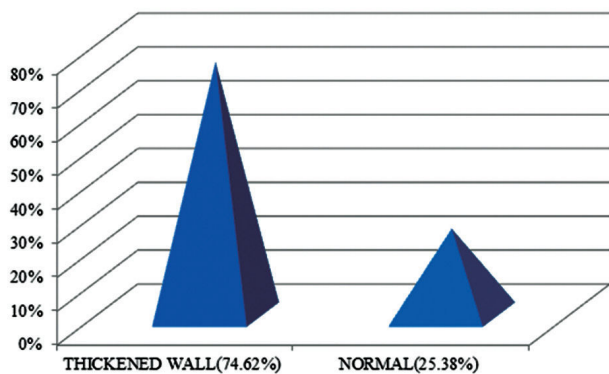
Graph 1: Sex distribution in chronic calculus cholecystitis.



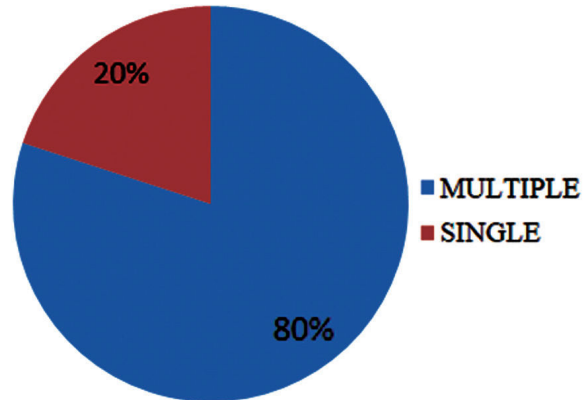
Graph 2: Age distribution of males and females in chronic calculus cholecystitis.



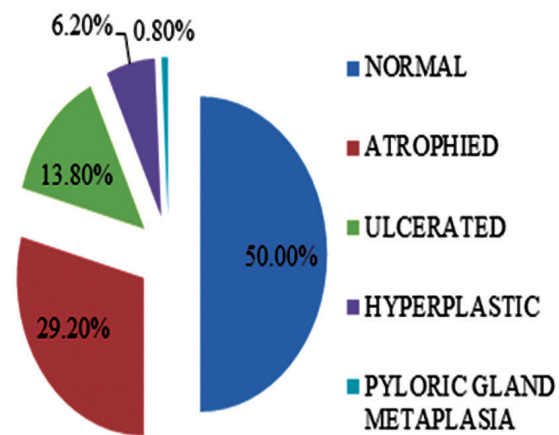
Graph 3: Wall thickness in chronic calculus cholecystitis.



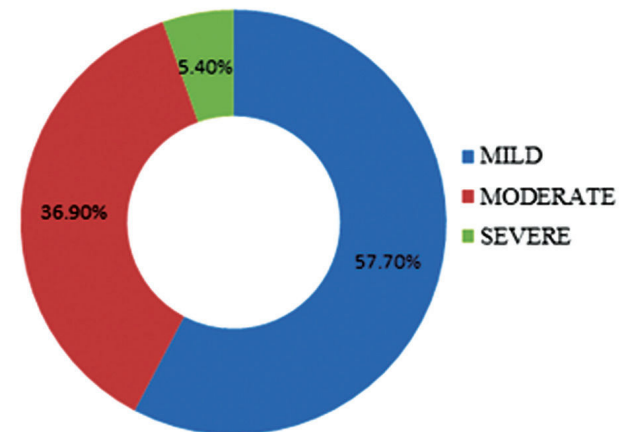
Graph 4: Number of gallstones in chronic calculus cholecystitis.



Graph 5: Microscopic mucosal changes in chronic calculus cholecystitis.



Graph 6: Degree of inflammation in chronic calculus cholecystitis.



Discussion

Out of 157 cases associated with gallstones, 130(82.80%) were diagnosed as chronic calculus cholecystitis and this was the most common diagnosis. This observation was consistent with the observation made by Gangoli AS, but slightly lower

than those made by Tyagi SP et al and Mohan N.

Table 1: Comparison of chronic calculus cholecystitis in different studies.

Author and Year	Percentage
Tyagi SP et al (1992) ⁶	91.9
Gangoli AS (1999) ⁷	80.9
Mohan N (2007) ⁸	94.4
Present study (2015)	82.8

Conclusion

- In the present study, there were 130 cases of chronic calculus cholecystitis, of which 98 (75.38%) were females and 32 (24.62%) were males
- Grossly, thickened wall was seen in 97 (74.62%) cases and the remaining 33 (25.38%) had normal wall thickness

References

1. Lin SH, Chang FY, Yang YS, Jin JS, Chen TW. Rare gallbladder adenomyomatosis presenting as atypical cholecystitis: case report. *BMC Gastroenterol* 2011;11:106.
2. Mann CD, Johnson NA, Metcalfe MS, Neal CP, Harrison RF, Berry DP et al. Cholecystobronchial fistula secondary to adenomyomatosis of the gallbladder. *Ann R CollSurgEngl* 2007;89:W1-3.
3. Kim BS, Oh JY, Nam KJ, Cho JH, Kwon HJ, Yoon SK et al. Focal thickening at the fundus of the gallbladder: computed tomography differentiation of fundal type adenomyomatosis and localized chronic cholecystitis. *Gut Liver* 2014;8:219-23.
4. Stokes MC, Burnette R, Ballard B, Ross C, Beech DJ. Adenomatous Hyperplasia of the Gallbladder. *J Natl Med Assoc* 2007;99:959-61.
5. Ozgonul A, Bitiren M, Guldur ME, Sogut O, Yilmaz LE. Fundal variant adenomyomatosis of the gallbladder: report of three cases and review of the literature. *J Clin Med Res* 2010;2:150-3.
6. Tyagi SP, Tyagi N, Maheshwari V, Ashraf SM, Sahoo P. Morphological changes in diseased Gallbladder: a study of 415 cholecystectomies at Aligarh. *J Indian Med Assoc* 1992;90:178-81.
7. Gangoli AS. Surgical Pathology of Gallbladder [Dissertation]. Shankaragatta: Kuvempu University; 1999.
8. Mohan N. A Histomorphological Study of Gallbladder [Dissertation]. Bengaluru: Rajiv Gandhi University of Health Sciences; 2007.

