

## A Study on the Morphometric Measurements of Pterion and Its Importance in Surgical Approach

Makani Thanuja Kumari<sup>1</sup>, Lattupalli Hema<sup>2</sup>

### How to cite this article:

Makani Thanuja Kumari, Lattupalli Hema. A Study on the Morphometric Measurements of Pterion and Its Importance in Surgical Approach. Indian J Anat. 2020;9(3):205-213.

**Author's Affiliation:** <sup>1</sup>Assistant Professor, <sup>2</sup>Professor and Head, Department of Anatomy, Narayana Medical College, Chinthareddypalem, Nellore, Andhra Pradeshm 524003, India.

**Corresponding Author:** Lattupalli Hema, Professor and Head, Department of Anatomy, Narayana Medical College, Chinthareddypalem, Nellore, Andhra Pradeshm 524003, India.

**E-mail:** hemakarra06@gmail.com

### Abstract

Aneurysms, tumours, meningiomas and extradural haemorrhage are the most common alarming neurological problems in the present era. These may have pathological cause and sudden stroke or fractures either by fall from a height accidentally, road traffic accidents proper or suicidal attempts leading to any of these above mentioned conditions primarily or secondarily.

#### *Aim and Objectives*

*Aim of The Study:* This study is therefore aimed at determining the position of Pterion at various palpable points with relation, types of Pterion with relation to middle meningeal artery and brain.

*Objectives of The Study:* To achieve the above aim, the work is planned by the following objectives -

1. To analyze type of Pterion based on Murphy classification.

Murphy's classification includes 4 types Pterion namely,

A) *Spheno-parietal type:* Greater wing of sphenoid articulates with the parietal bone to form the letter 'H'.

B) *Frontotemporal type:* Squamous part of the temporal bone articulates with the frontal bone.

C) *Stellate type:* Here all bones (frontal, temporal, greater wing of sphenoid and parietal) articulates at a point in the form of letter 'K'.

D) *Epipteretic type:* A sutural bone is lodged between the four bones forming the Pterion.

2. To analyze comparison of Pterion on both sides of a same skull. To measure length of Pterionic suture. To measure the distance from centre of Pterion to centre of zygomatic arch. To measure the distance from centre of Pterion to posterolateral margin of frontozygomatic suture. To measure distance from centre of Pterion's inner aspect to lateral end of crest of ridge on the lesser wing of sphenoid bone. To measure distance from centre of Pterion's inner aspect to lateral margin of optic canal. To measure distance from centre of Pterion to lower end of mastoid process.

*Material And Methods:* 100 adult human dry skulls of known sex, collected from the department of anatomy, Narayana medical college, Nellore and S.V medical college, Tirupathi. This was an observational study.

*Observation and Results:* In the present study various types of pterions were observed as shown in pie diagram. 100 adult dry skulls were examined. Sphenoparietal (92%), Frontotemporal (3%), Stellate (2%) and Epipteretic (3%). The results of remaining parameters are tabulated and photographed.

*Conclusion:* Knowledge of the location and relations of Pterion is important in relation to surgical intervention, particularly with respect to course of the branches of middle meningeal artery and Broca's motor speech area on the left side. The distances between the Pterion, lesser wing of sphenoid ridge and optic canal are of practical importance in surgical approaches to these regions via Pterion.

**Keywords:** Pterion; Middle meningeal artery; Lesser wing of sphenoid; Optic canal.



## Introduction

The anatomical location of aneurysms, stroke, cerebral hemorrhage tumors and meningioma conditions are important for surgical interventions. In neurosurgery, it is important to have the most suitable bony aperture in order to be minimally invasive (Ersoy et al., 2003).<sup>4</sup> To achieve optimum craniotomy where neuro navigation devices are not available, the surgeon then relies on external landmarks called as Craniometric points (Oguz et al., 2004).<sup>11</sup> These craniometric points are related to the structures in the cranial cavity one such craniometric point which forms a structural confluence of skull bones in the temporal fossa is called as "PTERION" (Williams et al., 1988).<sup>17</sup> The position of Pterion however cannot be discerned easily because it is usually covered by scalp (Williams et al.,).<sup>17</sup>

The Temporal fossa is a significant area of the skull where elements of the facial skeleton, the skull base and the calvaria converge (Urzi et al., 2003; Williams Et al.,1998).<sup>16,17</sup> The zygomatic arch, the temporal line, the fronto zygomatic process and the supramastoid process delineate the temporal fossa, and temporal muscle is attached to its floor. Temporal fossae are characterized by the four distinct bony elements: the frontal and parietal bones, the greater wing of sphenoid bone, and the squamous part of temporal bone. All of these bones are in close proximity in a region described by a small circular area termed Pterion located in norma lateralis approximately 4.0 cms above zygomatic arch and 3.5 cms behind the frontozygomatic suture (Williams et al.,).<sup>17</sup> This point is known as Sylvian point. It occurs as an irregular H-shaped meeting point of sutures, forming a horizontal limit between the anteroinferior parietal angle and the apical border of greater wing of sphenoid (Moore, 1992).<sup>9</sup>

The Pterion is also commonly used as an important guide for age by cranial suture closure methodology. During foetal period and at birth the region of pterion form a large membranous area called ("Soft Spot") anterolateral fontanelle or sphenoidal fontanelle.<sup>14,17</sup> It provides space to the skull bone to overlap while passing through pelvis at birth.<sup>17</sup> The fontanelles permit skull to accommodate the rapid growth of brain during infancy.<sup>14</sup> Complete ossification of anterolateral fontanelle normally occurs immediately after birth.

A study reveals that there are four types of Pterions: Sphenoparietal, Frontotemporal, Stellate, Epipteric. (Murphy).<sup>10</sup> The Pterion is an important anatomical

and anthropological land mark as it overlies both anterior ramus of middle meningeal artery and the lateral fissure of cerebral hemisphere. Thus, the knowledge of sutural joints between frontal, parietal, temporal, and greater wing of sphenoid at Pterion is clinically, radiologically, and surgically important during surgical interventions involving bur hole surgeries. The anatomical location of pterion is important in surgical approaches to the anterior and middle cranial fosse, following extra dural haemorrhage as well as tumours involving inferior aspects of frontal lobe, such as olfactory meningiomas, used in operation on the Boca's motor speech area, anterior pole of insula and in repairing aneurysms of middle cerebral artery and those of upper basilar complex (Bage E, 2002).<sup>3</sup>

The pterional approach is commonly employed in surgery of anterior circulation and upper basilar complex artery aneurysms as well as tumours of orbital, retro orbital, retro orbital, sellar, chiasmatic, sub frontal and prepontine areas and lesions around the sella especially for lesions behind the clivus. Also tumours arising from the medial sphenoid ridge, the superior orbital fissure, the anteromedial temporal surface, or the cavernous sinus region are approached through a Pterional exposure. The surgical technique is based on the experience, training and observation of the neurosurgeon. One technique is not necessarily better than the other regardless of the surgical technique, the end results depend on a rigorous, methodical, systematic and step by step approach to target, securing it with minimal injury to surrounding structures.

Also the anatomical varieties of the Pterion, is of interest mainly to the anthropologists and forensic pathologists, deserve further investigation in other geographical areas and different populations. Such findings could also be useful for assessing the location of the Pterion in incomplete archaeological remains or forensic materials (Ari Ilknur et al., 2009).<sup>1</sup> Thus the anatomical variations of Pterion had so much cared by the anthropologist, neurosurgeons and forensic pathologists. It was found necessary to study the occurrence of Pterion in the human skull, and also its relation to middle meningeal artery to fulfil the criteria.

### *Aim and Objectives*

*Aim of The Study:* This study is therefore aimed at determining the position of Pterion at various palpable points with relation, types of Pterion with relation to middle meningeal artery and brain.

*Objectives of the study:*

To achieve the above aim, the work is planned by the following objectives –

1. To analyze type of Pterion based on Murphy classification.  
Murphy's classification includes 4 types Pterion namely,  
A) *Spheno-parietal type*: Greater wing of sphenoid articulates with the parietal bone to form the letter 'H'.  
B) *Frontotemporal type*: Squamous part of the temporal bone articulates with the frontal bone.  
C) *Stellate type*: Here all bones (frontal, temporal, greater wing of sphenoid and parietal) articulates at a point in the form of letter 'k'.  
D) *Epipteric type*: A sutural bone is lodged between the four bones forming the Pterion.
2. To analyze comparison of Pterion on both sides of a same skull.
3. To measure length of Pterionic suture.
4. To measure the distance from centre of Pterion to centre of zygomatic arch.
5. To measure the distance from centre of Pterion to posterolateral margin of frontozygomatic suture.
6. To measure distance from centre of Pterion's inneraspect to lateral end of crest of ridge on the lesser wing of sphenoid bone.
7. To measure distance from centre of Pterion's inneraspect to lateral margin of optic canal.
8. To measure distance from centre of Pterion to lower end of mastoid process.

**Material and Methods**

*Source of Data*: 100 adult human dry skulls of known sex, collected from the department of anatomy, Narayana medical college, Nellore and S.V medical college, Tirupathi.

*Study Design*: This was an observational study. 100 Adult dry skulls were included based on following criteria.

*Inclusion Criteria:*

1. Adult human skull of known sex.
2. Both calvaria intact and cut skulls.

3. Third molar tooth erupted.
4. Sutures Well-defined.

*Exclusion Criteria:*

1. Damaged skulls.
2. New born, infant's children skulls.
3. Very old skulls with obliterated sutures.

*Materials Used:*

1. 100 Adult human dry skulls.
2. Sliding callipers.

*Method Of Collection Of Data*: Study had been conducted on 100 human adult dry skulls of known sex. Dry skulls are taken up for the study as there is paucity of cadavers. Those that had third molar teeth erupted will be considered as adults and hence studied.

Pterion is classified based on Murphy's classification.

Measurements taken on both sides of the skull from centre of Pterion to the midpoint of zygomaticarch, distance from centre of Pterion to poster lateral margin of frontozygomatic suture, distance from centre of Pterion to lower end of mastoid process, from centre of pterion's inner aspect to lateral end of the crest of ridge on the lesser wing of sphenoid, distance from centre of pterion's inner aspect to lateral margin of optic canal and length of pterionic suture in sphenoparietal and frontotemporal type of pterion, using sliding callipers. Each of the Measurements will be taken twice then averaged so as to minimize bias errors.

Relevant findings regarding various types of Pterion and position of pterion will be noted. Values will be recorded separately on right and left sides and compared. Values will also be compared with previous studies for their statistical significance. It is an observational study; the data collected in this study will be analysed statistically using descriptive statistics like percentages, mean, and standard deviation. To compare between right and left sides paired 't' test will be used.

**The standard anatomical landmarks used in this study were:**

*Pterion (Pt)*: Confluence of frontal, parietal, temporal and greater wing of sphenoid bones.

*Pterionic Suture (PT)*: Present only in frontotemporal type and sphenoparietal. In frontotemporal type of Pterion, Pterionic suture is present between frontal bone and squamous part of temporal bone. In sphenoparietal type of Pterion, Pterionic suture is present between greater wing of sphenoid bone and parietal bone.

**Frontozygomatic suture (FZ):** Suture Present between zygomatic process of frontal bone and frontal process of zygomatic bone.

**Zygomatic arch (ZA):** It is formed by the temporal process of zygomatic bone and zygomatic process of temporal bone. It is felt through the skin, where the cheek and temporal region meet each other.

**Mastoid process (MP):** A nipple shaped process on the temporal bone that extends downward and forward behind external acoustic meatus.

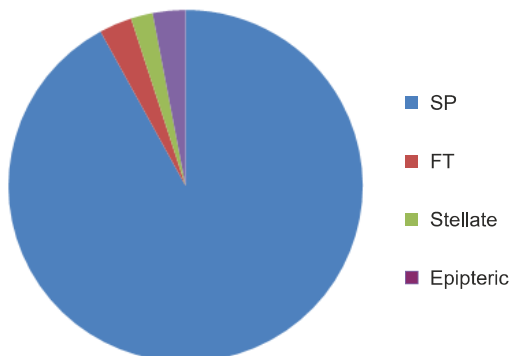
**Optic canal (OC):** Optic canal is bounded by roots of lesser wing of sphenoid bone. Optic canal leads to orbit which transmit optic nerve and ophthalmic artery.

**Crest of lesser wing of sphenoid (LWS):** Lateral end of lesser wing of sphenoid.

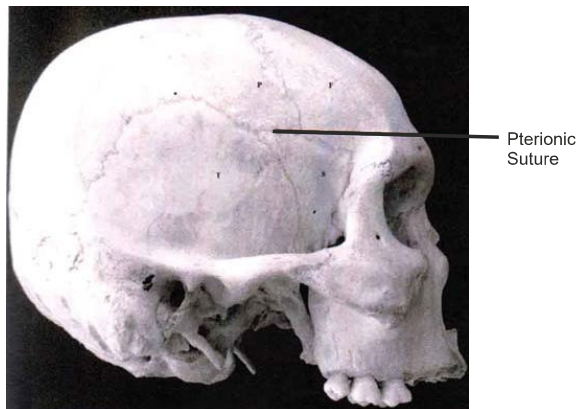
**Discussion**

In the present study various types of pterions were observed as shown in pie diagram. 100 adult dry skulls were examined. Sphenoparietal type of Pterion Picture 1 is seen in (92%), Frontotemporal type of Pterion is seen in (3%) Picture 2, Stellate Picture 3 (2%) and Epipteric Picture 4 (3%), which are shown in graph 1 and table 1 and also their percentages on right and left side, and the same in graph 2. Table 2 shows different types of terion and percentage towards right and left side in females. In the present study sphenoparietal, frontotemporal, stellate, epipteric types of pterion were observed. Sphenoparietal type of Pterion is most common seen in Asiatic Indians (95.1%),<sup>14</sup> Northern Indians (87.72%),<sup>12</sup> South Indians (93.55%)<sup>8</sup> and Nigerians (87.79% and 82.1%)<sup>7,12</sup> and in this study (92%); While it was significantly lower in Korean (76.5%)<sup>6</sup> and Kenyan (66%)<sup>7</sup> Populations as compared to this study Table 3 and Graph 3.

Pie diagram showing percentages of different types of pterion



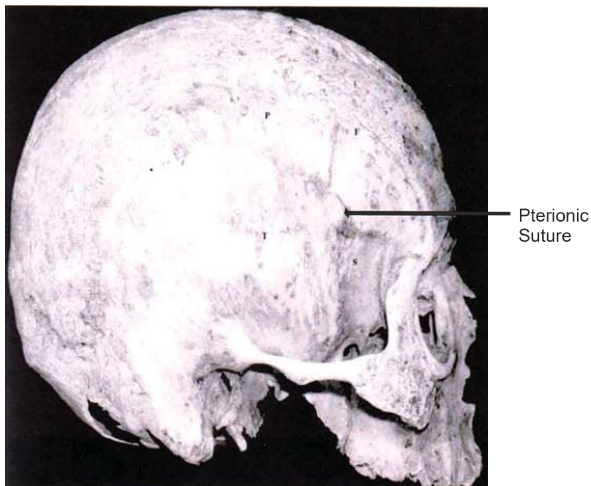
SP – Sphenoparietal, FT-Frontotemporal  
 SP – 92%, FT-3%, Stellate-2%, Epipteric-3%



Sphenoparietal type of Pterion : Pterionic Suture between parietal and sphenoid bone.

F-Frontal, P-Parietal, T-Temporal, S-Sphenoid

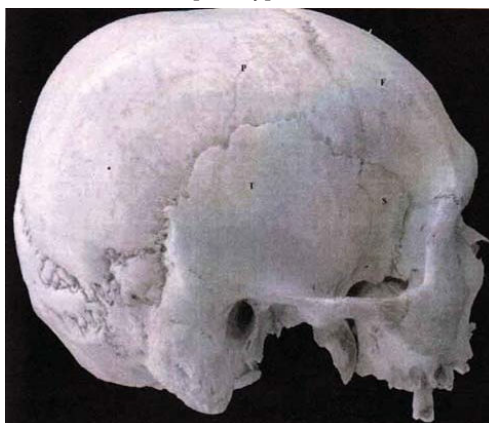
**Picture 1:** Sphenoparietal type of Pterion



Frontotemporal type: Pterionic Suture between frontal and temporal bone.

F-Frontal, P-Parietal, T-Temporal, S-Sphenoid

**Picture 2:** Frontotemporal type of Pterion.

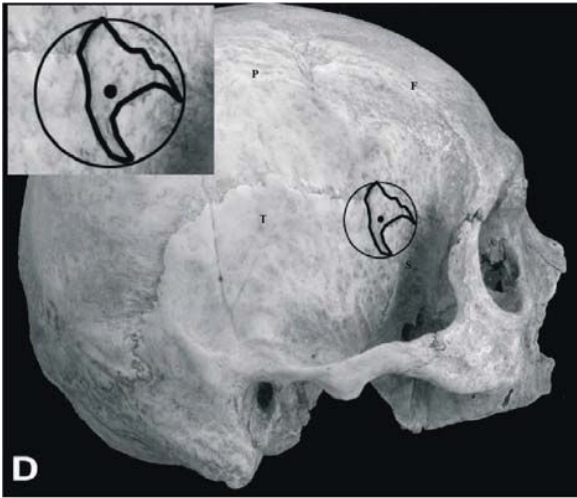


Stellate type of pterion

F-Frontal, P-Parietal, T-Temporal, S-Sphenoid

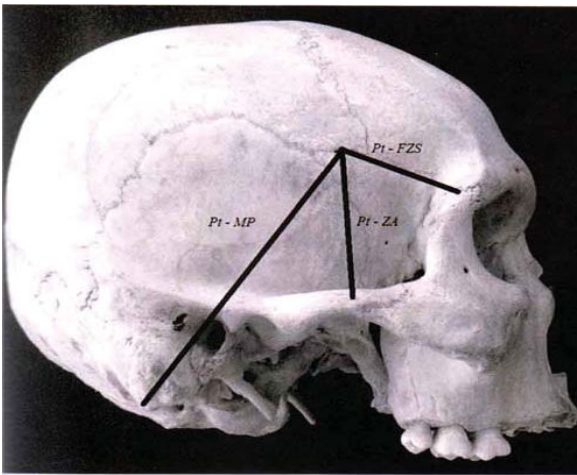
**Picture 3:** Stellate type of Pterion.





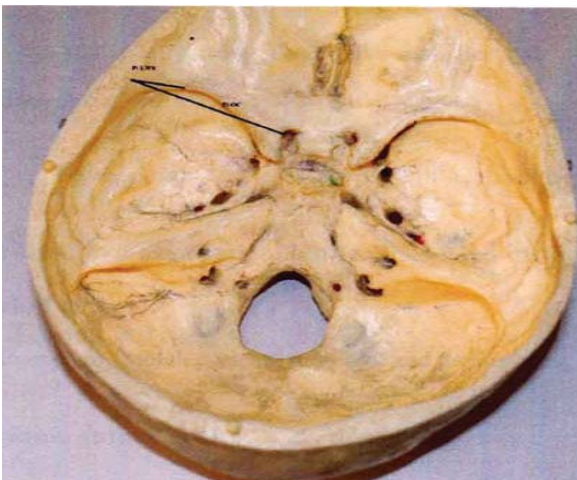
Epipterice Type of Pterion

Picture 4 : Epipterice Type of Pterion



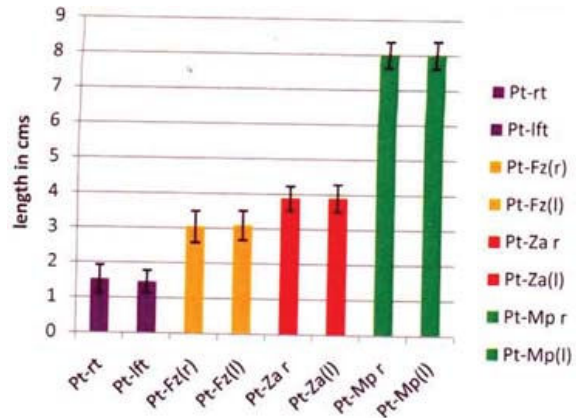
Pt-Pterion, FZS-Frontozygomatic suture, ZA-Zygomatic arch, MP-Mastoid process

Picture 5: Showing measurement taken from variable landmarks.



Pt-Pterion, LWS-crest of lesser wing of sphenoid, LOC-Lateral margin of optic canal

Picture 6: Showing measurement taken from inner aspects of Pterion to variable land marks.



Graph 1: Showing mean and Standard deviation of various landmarks around Pterion in 100 adult skulls.

Table 1: Percentages of different types of Pterion in 100 adult skulls.

| Type of Pterion | Right side | Left side | Both sides |
|-----------------|------------|-----------|------------|
| Sphenoparietal  | 94%        | 90%       | 92%        |
| Frontotemporal  | 03%        | 03%       | 03%        |
| Stellate        | 00%        | 04%       | 02%        |
| Epipterice      | 04%        | 02%       | 03%        |

Graph 2: Showing percentages of different types of Pterion in 70 male skulls and 30 female skulls of both right and left sides.

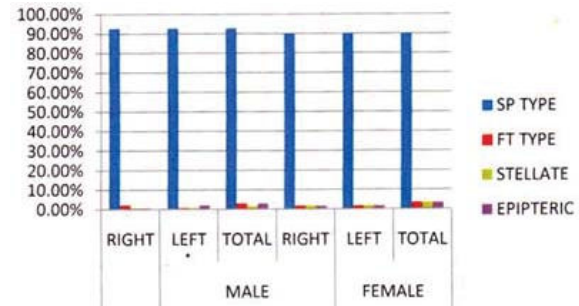
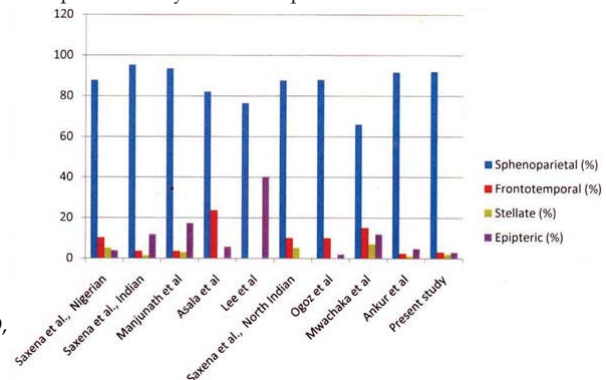


Table 2: Showing percentages of different types of Pterion in 70 male and 30 female skulls.

| Sex    | Side  | SP Type | FT Type | Stellate | Epipterice |
|--------|-------|---------|---------|----------|------------|
| Male   | Right | 92.8%   | 2.1%    | 0.7%     | 0.7%       |
|        | Left  | 92.8%   | 0.7%    | 0.7%     | 2.1%       |
|        | Total | 92.8%   | 2.8%    | 1.4%     | 2.8%       |
| Female | Right | 90%     | 1.6%    | 1.6%     | 1.6%       |
|        | Left  | 90%     | 1.6%    | 1.6%     | 1.6%       |
|        | Total | 90%     | 3.3%    | 3.3%     | 3.3%       |

Graph 3: Comparison of percentages of different types of Pterion from present study with other previous studies.



**Table 3:** Comparison of percentages of Pterion types in different populations.

| Study/Population n (Skull), sex  | Type of Pterion    |                    |              |               |
|--|--------------------|--------------------|--------------|---------------|
|  | Sphenoparietal (%) | Frontotemporal (%) | Stellate (%) | Epipteric (%) |
| Saxena et al <sup>45</sup> , 1988, Nigerian, n = 40, unknown sex         | 87.79              | 10.11              | 5.06         | 3.79          |
| Saxena et al., 1988, Indian, n = 72, unknown sex                         | 95.3               | 3.46               | 1.38         | 11.79         |
| Manjunath et al <sup>30</sup> , 1993, South Indian, n = 172, unknown sex | 93.55              | 3.52               | 2.93         | 17.3          |
| Asala et al <sup>7</sup> , 1996, Nigerian, n = 212, unknown sex          | 82.1               | 23.6               | -            | 5.7           |
| Lee et al <sup>16</sup> , 2001, Korean, n = 149, unknown sex             | 76.5               | -                  | -            | 40.3          |
| Saxena et al <sup>46</sup> , 2003, North Indian, n = 203, both sex       | 87.72              | 10.01              | 5.17         | 0             |
| Ogoz et al <sup>39</sup> , 2004, Turkish, n = 26, Male                   | 88                 | 10                 | 0            | 2             |
| Mwachaka et al <sup>29</sup> , Kenyan, n = 50, both sex                  | 66                 | 15                 | 7            | 12            |
| Anker et al., 2009, West Indian, n = 42, both sex                        | 91.7               | 2.4                | 1.2          | 4.8           |
| Present study  | 92                 | 03                 | 02           | 03            |

**Table 4:** Distance between Pterion and zygomatic arch in male skulls.

|             | Side  | N  | Mean (cm) | STD. Deviation (cm) | p Value |
|-------------|-------|----|-----------|---------------------|---------|
| <b>Male</b> | Right | 70 | 3.90      | 0.39                | 0.70    |
|             | Left  | 70 | 3.88      | 0.35                | 0.70    |

**Table 5:** Distance between Pterion and zygomatic arch in female skulls.

|               | N     | Side | Mean (cm) | STD. Deviation (cm) | p Value |
|---------------|-------|------|-----------|---------------------|---------|
| <b>Female</b> | Right | 30   | 3.86      | 0.34                | 0.73    |
|               | Left  | 30   | 3.86      | 0.34                | 0.73    |

**Table 6:** Distance between Pterion and frontozygomatic suture in male skulls.

|             | N  | Side  | Mean (cm) | STD. Deviation (cm) | p Value |
|-------------|----|-------|-----------|---------------------|---------|
| <b>Male</b> | 70 | Right | 3.09      | 0.42                | 0.43    |
|             | 70 | Left  | 3.04      | 0.45                | 0.43    |

**Table 7:** Distance between Pterion and frontozygomatic suture in female skulls.

|        | N  | Side  | Mean (cm) | STD. Deviation (cm) | p Value |
|--------|----|-------|-----------|---------------------|---------|
| Female | 30 | Right | 3.05      | 0.44                | 0.52    |
|        | 30 | Left  | 3.03      | 0.46                | 0.52    |

**Table 8:** Distance between Pterion and mastoid process in male skulls.

|      | N  | Side  | Mean (cm) | STD. Deviation (cm) | p Value |
|------|----|-------|-----------|---------------------|---------|
| Male | 70 | Right | 8.00      | 0.37                | 1.000   |
|      | 70 | Left  | 8.00      | 0.39                | 1.000   |

**Table 9:** Distance between Pterion and mastoid process in female skulls.

|               | N  | Side  | Mean (cm) | STD. Deviation (cm) | p Value |
|---------------|----|-------|-----------|---------------------|---------|
| <b>Female</b> | 30 | Right | 7.8       | 0.4                 | 0.75    |
|               | 30 | Left  | 7.7       | 0.5                 | 0.75    |

**Table 10:** Distance between internal aspect of Pterion and lesser wing sphenoid ridge in male skulls.

|              | N  | Side  | Mean (cm) | STD. Deviation (cm) | p Value |
|--------------|----|-------|-----------|---------------------|---------|
| <b>Males</b> | 30 | Right | 2.49      | 0.50                | 0.68    |
|              | 30 | Left  | 2.45      | 0.49                | 0.68    |

**Table 11:** Distance between internal aspect of Pterion and lesser wing sphenoid ridge in female skulls.

|                | N  | Side  | Mean (cm) | STD. Deviation (cm) | p Value |
|----------------|----|-------|-----------|---------------------|---------|
| <b>Females</b> | 20 | Right | 2.45      | 0.52                | 0.69    |
|                | 20 | Left  | 2.42      | 0.54                | 0.69    |

**Table 12:** Distance between internal aspect of Pterion and lateral margin of optic canal in male skulls.

|              | N  | Side  | Mean (cm) | STD. Deviation (cm) | p Value |
|--------------|----|-------|-----------|---------------------|---------|
| <b>Males</b> | 30 | Right | 4.34      | 0.33                | 0.32    |
|              | 30 | Left  | 4.40      | 0.28                | 0.32    |

**Table 13:** Distance between internal aspect of Pterion and lateral margin of optic canal in female skulls.

|                | N  | Side  | Mean (cm) | STD. Deviation (cm) | p Value |
|----------------|----|-------|-----------|---------------------|---------|
| <b>Females</b> | 20 | Right | 4.30      | 0.32                | 0.35    |
|                | 20 | Left  | 4.33      | 0.29                | 0.35    |

**Table 14:** Length of the Pterionic suture in male skulls.

|      | N  | Side  | Mean (cm) | STD. Deviation (cm) | p Value |
|------|----|-------|-----------|---------------------|---------|
| Male | 70 | Right | 1.52      | 0.40                | 0.46    |
|      | 70 | Left  | 1.46      | 0.32                | 0.46    |

**Table 15:** Length of the Pterionic suture in female skulls.

|        | N  | Side  | Mean (cm) | STD. Deviation (cm) | p Value |
|--------|----|-------|-----------|---------------------|---------|
| Female | 30 | Right | 1.48      | 0.43                | 0.49    |
|        | 30 | Left  | 1.43      | 0.45                | 0.49    |

The incidence of frontotemporal type of Pterion has also been observed to vary in different groups, being reported of (10.11–23.6%) in Nigerians,<sup>7,12</sup> (15%) of Kenyans<sup>7</sup> (41.1%) of Papuan skulls<sup>15</sup>; which are significantly higher than present study. In the present; which are significantly higher than present study. In the present study the frequency of frontotemporal type of Pterion was (3%) being closest to that reported in other populations of India (Table 3).<sup>13,8</sup> An Epipteric type of Pterion was observed in a small number of skull (3%) in the present study, being significantly less than that reported in Nigerians (23.6%) (Asala S A et al., 1996),<sup>2</sup> Australian Aborigines (18.5%) (Murphy T 1998) and (10.01%) of Northern Indians (Saxena RC et al., 2003)<sup>13</sup> but similar to that in (3.52%) of South Indians (Manjunath KY et al., 1993).<sup>8</sup> Stellate type of Pterion was observed in (02%) of the observations alone in the present study where as it was observed to be (5.06%) in Nigerians (Saxena et al., 1988)<sup>13</sup> and also in Indians (1.38%) it was also found to be (2.93%) in South Indians (Manjunath et al., 1993).<sup>8</sup> Much of study was not highlighted in this type of Pterion by various authors and we found paucity of the literature in this type of Pterion for our present study.

The present study was conducted to note sutural Table 14 and 15, morphology of the Pterion among 100 skulls taken separately apart from the above mentioned skulls of Known gender (30 females and 70 males) and examined on both sides. Sphenoparietal type was observed 92%, in males (92.8%) and in females (90%); frontotemporal 3% in total, (2.85%) in males and (3.33%) in females; stellate type 2% in total, (1.42%) in males and (3.33%) in females; epipteric type 3% in total (2.85%) in males and (3.33%) in females. Sphenoparietal type was more in males (92%) compared to females (90%); frontotemporal type 2.85% in males and 3.33% in females and epipteric 2.85% in males and 3.33% in females.

The sphenoparietal was (92%) in males and (90%) in females in the present study. This was found to

be (72.3%) in males and (66.2%) in females in South Indians (Ikedo et al., 1999)<sup>5</sup> it was (87%) in male and (82%) in females in Indians (Saxena - 2003).<sup>13</sup>

Stellate type of Pterion was found to be (1.42%) in males and (3.33%) in females in our present study. It was (9.2%) in males and (10.2%) in females by (Ikedo et al., 1999)<sup>5</sup> in South Indians.

In present study, as shown in Table 4 and 5 in both sexes, the Pterion was located  $3.90 \pm 0.38$  cm superior to the midpoint of zygomatic arch on right side and  $3.88 \pm 0.35$  cm superior to midpoint of zygomatic arch on the left side of male skull (Picture 5). On the right side the Pterion is situated slightly higher compared to left side of the male skull. But, it is not statistically significant. In female skull, the Pterion was located  $3.86 \pm 0.34$  cm superior to zygomatic arch on right and left sides. Our study coincides with the study done by Ogouzo et al., (2004)<sup>11</sup> where the distances on the right and left sides of the Turkish male skulls were compared from the centre of the Pterion to the midpoint zygomatic arch was  $4.05 \pm 0.39$  cm and  $3.85 \pm 0.25$  cm respectively. The distance between Pterion to midpoint of zygomatic arch on right side of male and female skulls were compared. The distance of male skulls on right side  $3.90 \pm 0.39$  cm is higher than the female skulls  $3.86 \pm 0.34$  cm. The distance between Pterion to midpoint of zygomatic arch on left side of male and female skulls were compared. The distance of male skulls on left side  $3.88 \pm 0.35$  cm is higher than the female skulls  $3.86 \pm 0.34$  cm. The distance between Pterion and midpoint of zygomatic arch in the present study varied significantly ( $p = 0.43$ ) among males and females. Males had higher Pterion than females. Our study coincides with Mwachaka p et al., (2008)<sup>7</sup> where the distance between the Pterion to the midpoint of zygomatic arch varied significantly among males and females.

The present study shown that the distance between Pterion to frontozygomatic as shown in table-6 and 7, suture among male skulls showed statistical significant side differences among male skulls ( $p = 0.43$ ). The right side  $3.09 \pm 0.42$  cm is posterior than the left side  $3.04 \pm 0.45$  cm. The distance between Pterion to frontozygomatic suture among female skulls right and left side compared. The right side Pterion  $3.05 \pm 0.44$  cm is posterior than the left side  $3.03 \pm 0.46$  cm. It showed no statistically significant between side differences among female skulls ( $p = 0.52$ ). The Pterion was  $30.35 \pm 3.61$  mm posterior to frontozygomatic suture on right side. While the left Pterion was  $30.34 \pm 4.30$  mm behind in Kenyans (Mwachaka P et al., 2008).<sup>7</sup> Conversely, the Pterion among the male turks lie  $33 \pm 4.0$  mm and



34.4 ± 3.9 mm behind the frontozygomatic suture on the right and left respectively. The basis for differences among these populations could be genetic or evolutionary (Ikedo T et al., 1999).<sup>5</sup> The Pterion lies 30 to 35 mm away from the frontozygomatic suture (Urzi F et al., 2003).<sup>16</sup> The Pterion in Koreans 26.8 ± 4.5 mm away from the frontozygomatic suture. The distance between Pterion to frontozygomatic suture on right side of male and female skulls were compared. The distance of male skulls on right side 3.09 ± 0.42 cm is more posterior than the female skulls 3.05 ± 0.44 cm. It is showed statistically significant side differences among male and female skulls on the right side ( $p = 0.43$ ). The distance of male skulls on left side 3.04 ± 0.45 cm is posterior than the female skulls 3.03 ± 0.46 cm. It showed statistically significant sides ( $p = 0.43$ ). The present study shown that the distance between Pterion and mastoid process shows statistically side difference among male skulls ( $p = 1.000$ ), as shown in Table 8 and 9, with right side 8.0 ± 0.37 cm and left side 8.0 ± 0.39 cm and in females 7.8 ± 0.4 cm right side and 7.7 ± 0.5 cm on left side. The distance between the internal aspect of the Pterion to the lesser wing sphenoid ridge Table 10 and 11, in 50 calvaria sectioned skulls is 2.49 ± 0.50 cm in right side and 2.45 ± 0.49 cm in left side in male skulls (30). In female skulls (20) 2.45 ± 0.52 cm right side and 2.42 ± 0.54 cm left side with statistical significance  $p = 0.68$  (Nanda A et al., 2001). The distance between internal aspect of the Pterion and lateral margin of optic canal in present study, Table 12 and 13, Picture 6 is 4.34 ± 0.33 cm of right side and 4.40 ± 0.28 cm of left side in male skulls and 4.30 ± 0.32 cm of right side and 4.33 ± 0.29 cm of left side with  $p = 0.32$ . The present study shown that the length of Pterionic suture shows the statistical side difference among male skulls ( $p = 0.46$ ) in sphenoparietal type 1.52 ± 0.40 cm on right side and 1.46 ± 0.32 cm and in frontotemporal type 1.48 ± 0.43 cm on right side and 1.43 ± 0.45 cm. Pterionic suture is not present in epipteric type and stellate type of Pterion. Gender differences in location of this craniometric point were significant; the male Pterion is more posteriorly located on the right and left side compared to the female skulls. This could be because of the larger size of skull in males (Moore KL et al., 1992, William LP et al., 1988).<sup>9,17</sup> Population based differences suggest that various genetic variations in humans underlie the different sutural patterns of the Pterion (Wang Q et al., 2006).<sup>18</sup> Murphy reported that variations of Pterion are likely a result of combination of environmental and genetic factors (Ari Ilknur et al., 2009).<sup>1</sup> Asala

concluded that these variations are “epigenetic” (Asala SA et al., 1996).<sup>2</sup> In the present study the Pterion is located more superiorly (its distance from the midpoint of zygoma) and more posteriorly (its distance from the frontozygomatic suture) in males compared to that of females on both sides. Since there was minimal side differences among the right side measurements of male skull to that of left side measurements of male skull and also in comparison to female right side measurement to female left side used to locate the Pterion, this landmark can reliably be located using the frontozygomatic suture and midpoint of zygoma according to the sexual differences.

### Conclusion

Knowledge of the location and relations of Pterion is important in relation to surgical intervention, particularly with respect to course of the branches of middle meningeal artery and Broca’s motor speech area on the left side. The distances between the Pterion, lesser wing of sphenoid ridge and optic canal are of practical importance in surgical approaches to these regions via Pterion. Gender differences in the location of this craniometric point were significant. This could be because of large size of skulls in males (Williams). In the present study Pterion is located more superiorly (the distance from the midpoint of zygomatic arch) and more posteriorly (its distance from frontozygomatic suture) in males compared to that of the female on both sides. There was a minimal side differences among the right side to left side measurements and also comparison to female skulls right and left sides used to locate Pterion. This landmark can reliably be located using frontozygomatic suture and midpoint of zygomatic arch according to sexual differences. This information may be useful in planning prior to surgery and recognition of this anatomy may render Pterional craniotomy safer. The present study has shown separate incidence of Pterion in known male and female skulls. Sphenoparietal variety was predominant type of Pterion. There is a considerable variation between types of Pterion and Point of division of middle meningeal artery. This difference of incidence was found to be statistically insignificant and may be due to population differences or racial differences. Relationship between the middle meningeal artery and the Pterion is of great importance in the field of surgery, anthropology and forensic medicine. Hence, the present study has been compared and correlated with earlier studies done by Pterion workers. Types



and the position of Pterion in normal skulls vary among individuals and different racial groups. Sex has influence on the occurrence of the Pterion type, while sex, side and age affect the location of Pterion. Therefore, accurate and up-to-date data are required when performing intracranial surgery guided by recognizable bony landmarks preoperative radiographic assessment (CT, MRI) of Pterion should be confirmed to be anatomic guide line for surgeons in determining a safe location for performing surgical microsurgical procedures.

## References

1. Ari Ilknur, Kafallker Mustafa, BakirciSinan. A Comparative Study of Variation of Pterion of Human Skulls from 13<sup>th</sup> and 20<sup>th</sup> Century Anatolia. *Int J. Morphol.* 2009;27(4):1291-1298.
2. Asala, S. A and Mbarjiyogu, F, E, Epigenetic Variation in the Nigerian Skull: Sutural Pattern at the Pterion. *East. Afr. Med. J.*, 73(7):484-6, 1996.
3. Bage, E; de Sola, G; Gonzalez, R; Caniego, L and Cazon, C. Fusiform aneurysm of middle cerebral artery. *Rev. Neurol.*, 34:665-8,2002.
4. Ersoy, M; Evliyaoglu, C; Bozkurt, MC; Konuksan, B; Tekdemir, I and Keskil, I. Epipteric Bones in the Pterion May be a Surgical pitfall. *Minim. Invasive. Neurosurg.* 46;363-5,2003.
5. Ikedo, T; Nakamura, M and Ioth, M Sex differences in zygomatic angle in Japanese patients analyzed MRI with reference to Moire Fringe Patterns. *Aesth. Plast. Surg.*, 23:349-53,1999.
6. Lee, UY; Park, DK; Kwon, SO; Paik, DJ and Han, SH. Morphological analysis of Pterion in Korean. *Korean J. Phys. Anthropol.*, 14(4) :281-9,2001.
7. Mwachaka P, Hassanali J, Odula P. Anatomic Position of the Pterion among Kenyans for lateral skull approaches. *Int. J. Morphol.* 2008;26(4):931-933.
8. Manjunath, KY and Thomas, IM. Pterion variants and epipteric ossicles in south Indian skulls. *J. Anat. Soc. India*, 42(2):85-94,1993.
9. Moore KL *Clinically oriented anatomy*. 30<sup>th</sup> edn. Williams and Wilkins, pp. 641-642, Baltimore, 1992.
10. Murphy, T. The Pterion in the Australian aborigine. *Am. J. Phys. Anthropol.* 14:22544,1956.
11. Oguz, O; Sanli, SG and Bozkir, MG and Soames, RW. The Pterion in Turkish male skulls. *Surg. Radiol. Anat.*, 26:220-4,2004.
12. Samson, DS; Hodosh, RM and Clark, WK. Microsurgical evaluation of the pterional approach to aneurysms of the distal basilar circulation. *Neurosurgery*, 3(2):135-41,1978.
13. Saxena, RC; Bilodi, AKS; mane SS and Kumar, A study of Pterion in skulls of Avadh area- in and around Lucknow. *Khatmandu univ. med. J.*, 1(1):32-3,2003.
14. Standing S, Ellis H, Healy JC, Johnson D. *Gray's anatomy*, 39<sup>th</sup> edn. Elsevier Churchill Livingstone, London, 2005; 442-71.
15. Tomasello, F; de Divitis, O; Angileri, FF; Salpietro, Fm and Avella, D. Large Sphenocavernous meningiomas is there still a role for the intramural approach via the pterional-trans Sylvian Route? *Acta neurochir.* 145(40):273-82,2003.
16. Urzi, F; Iannello, A; Torrissi, A; Foti, p; Mortellaro, NF and Cavallaro, M Morphological variability of Pterion in the human skull. *Ital. J. Anat. Embryol.*, 108:83-117,2003.
17. Williams, LP; Bannister, LH; Berry, M. M.; Collins, P.; Dyson, m.; Dussek J.E.; and Ferguson, MWJ. *Gray's Anatomy*. 38<sup>th</sup> edn. Churchill Livingstone, PP.568, 595, 1912, 1519, London, 1988.
18. Wang, Q; Opperman, LA; Haval, LM; Carlson, DS and Dechow PC Inheritance of sutural pattern at the Pterion in Rhesus monkey skulls. *Anat. Recv. Discov. Mol. Cell. Evol. Biol.*, 288:1042-9,2006.