

## An Atypical Case of Myxedema Coma with Incidental Chilaiditi Syndrome

Sonika Dhillon<sup>1</sup>, Raghwesh Ojha<sup>2</sup>

### How to cite this article:

Sonika Dhillon, Raghwesh Ojha/ An Atypical Case of Myxedema Coma with Incidental Chilaiditi Syndrome/Indian J Emerg Med 2023;9(4):205-208.

### Abstract

- Hypothyroidism is a prevalent condition in the general population.<sup>1</sup> 42 million people in India have thyroid disorders and hypothyroidism is the most common, affecting one in ten adults.
- Myxedema coma is a rare and life threatening emergency with a high mortality rate.<sup>2</sup> It results from severe hypothyroidism and affects almost every organ.
- Patients will present with myxedema coma, characterized by hypothermia, hypotension, bradycardia, and altered mental status in the setting of severe hypothyroidism.<sup>3</sup> Myxedema coma has also been known to manifest in a number of unusual and dangerous forms.
- A high index of suspicions is needed among clinicians in order to rapidly recognize the condition and make an early diagnosis. Treatment should be commenced on clinical grounds while waiting for laboratory results.
- Here, we present the case of a male who presented to the emergency department with altered mental status, Anasarca and inability to walk.

**Keywords:** Myxedema; Hypothyroidism; Hypothermia; Hypercapnea; Levothyroxine.

### INTRODUCTION

Myxedema coma is a very rare endocrine emergency. Its recognition can be easily missed now-a-days due to the paucity of cases.<sup>4</sup> It is

uncommon for patients to present in coma, but they manifest milder forms of altered consciousness. The diagnosis should be considered in any patient with a decreased level of consciousness who also has hypothermia, hyponatremia and/or hypercapnea.

A high index of suspicions is needed among clinicians in order to rapidly recognize the condition and make an early diagnosis. Treatment should be commenced on clinical grounds while waiting for laboratory results. Treatment should be early and aggressive as its mortality rate remains high at 30-40%.

Here, we present a case of myxedema coma in a 69 years old male patient who presented to the

**Author's Affiliation:** <sup>1</sup>Consultant, Department of Emergency Medicine, Ramakrishna Care Hospital, Raipur 492001, Chhattisgarh, India, <sup>2</sup>Associate Consultant, Department of Cardiology, Pulse Hospital, Bhilai 490020, Chhattisgarh, India.

**Corresponding Author:** Raghwesh Ojha, Associate Consultant, Department of Cardiology, Pulse Hospital, Bhilai 490020, Chhattisgarh, India.

**E-mail:** [harmonys125@gmail.com](mailto:harmonys125@gmail.com)

**Received on:** 01-04-2023

**Accepted on:** 31-05-2023



This work is licensed under a Creative Commons Attribution-NonCommercial-ShareAlike 4.0.

emergency department with altered mental status, hypothermia, anasarca and hypercapnea.

## CASE REPORT

A 69 years old Male was brought to the Emergency Department at 2050 hours on 04/16/2019, via ambulance with a past history of CRF and hypothyroidism. The history was misled and was informed by the patient's son who interpreted that the patient had been sleeping a lot for the past few days with loss of appetite, generalized weakness, inability to walk and anasarca.

Earlier, he was taken to some local hospital where he was managed conservatively. Then, he was referred to the Ram Krishna Care Hospital for further evaluation and management.

Vitals on arrival were notable for BP: 130/90mmHg, HR: 58bpm, RR22/m, his oxygen saturation was 60% on room air, CBG: 136mg/dl and GCS E2V2M4. On initial physical examination, the patient was pale, with a body temperature of 97°F. He demonstrated very slow mentation, responding only on painful stimuli (GCS 8) and was somnolent, but to be aroused on painful stimulus. His mucus membranes were dry, his heart sounds were distant, had bilateral basal crepts over lungs.

His abdomen was distended. His lower extremity pulses were weak and pretibial pitting edema was present.

In order to secure air way, patient was intubated in the Emergency Department.

### Investigations

Laboratory investigations on admission showed hypothyroidism, mild anemia, mildly elevated serum creatine kinase concentration, and impaired renalfunction (Table 1). Liver function test showed

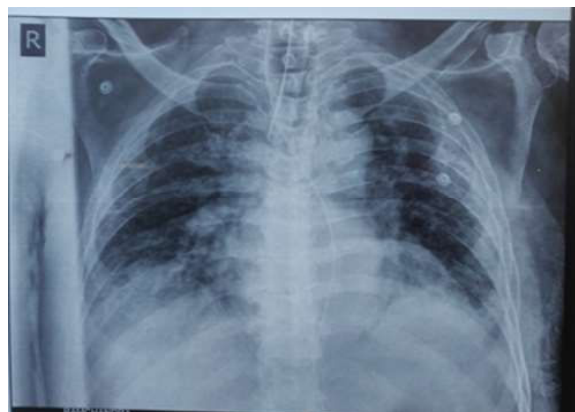**Table 1:** Laboratory Data on Admission

Variables	Normal Reference Range	Results
Hemoglobin (g/dL)	12-16	9.06
Red blood cells (/ $\mu$ L)	3.8-4.8 $\times$ 10 <sup>7</sup>	3.52
Platelet count (/ $\mu$ L)	15-45 $\times$ 10 <sup>4</sup>	21.1
White cell count (/ $\mu$ L)	4.5-13.5 $\times$ 10 <sup>3</sup>	6.07
Neutrophils (%)	36-66	74.5
BUN (mg/dL)	8-20	8.2
CRE (mg/dL)	0.6-1.1	1.33
Sodium (mEq/L)	135-145	133
Potassium (mEq/L)	3.5-4.5	3.60
Chlorine (mEq/L)	101-108	92.2

hypoalbuminemia, electrolytes were within normal range; that is, he was not hyponatremic. Blood gas analysis showed acute respiratory acidosis and type II respiratory failure, and thyroid antibodies were detected (Table 2). An X-ray (Fig. 1) and a

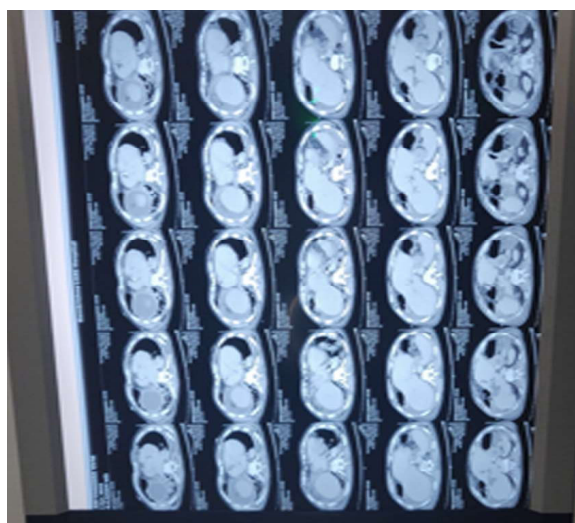
**Table 2:** Laboratory Data on Admission

Variables	Normal Reference Range	Results
pH	7.35 to 7.45	7.20
PaCO <sub>2</sub> (mmHg)	32 to 48	73.4
PaO <sub>2</sub> (mmHg)	74 to 104	47.7
HCO <sub>3</sub> (mEq/L)	22 to 26	23.1
Base excess (mEq/L)	-2 to+2	-0.8
TSH ( $\mu$ IU/mL)	0.35 to 4.94	145.11
FreeT3(ng/dL)	60 to 100	19
FreeT4(ng/mL)	4.5 to 12	<0.3



**Fig. 1:** X-ray

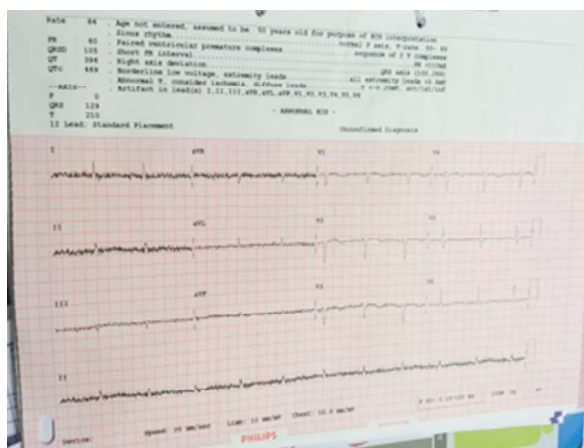CECT scan (Fig. 2) showed small areas of honey combing suggesting early changes of interstitial pulmonary fibrosis, trachea-bronchomalacia. An



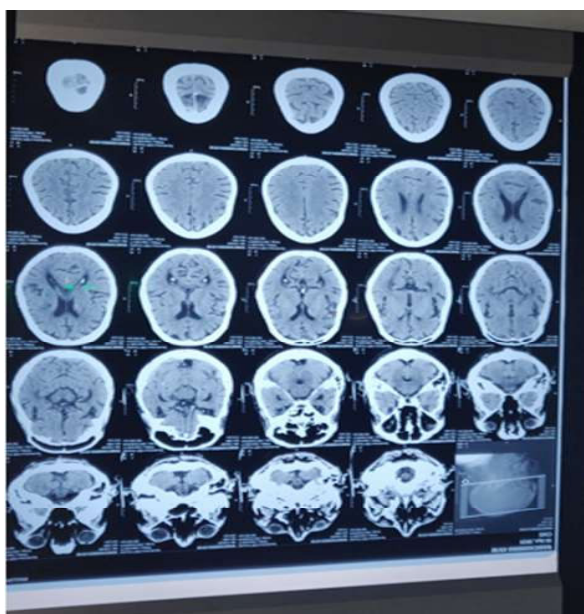
**Fig. 2:** CECT chest

electrocardiogram revealed all waves were low voltage (Fig. 3).

Enlarged lymph nodes in pretracheal, paraaortic arch and pre carinal area, visualization of upper abdomen showed bilateral tiny renal calyceal calculi, GB sludge, syndrome and mild ascites.<sup>5</sup>



A CT of the head revealed chronic infarction in the left basal ganglia (Fig. 4).



The diagnosis of Myxedema Coma was made on the basis of the clinical presentations. The typical characteristics of myxedema coma, including bradycardia and hypothermia were present in this case. The patient was transferred to the ICU. He was started on oral levothyroxine 200µg/day via RT. His mental condition improved dramatically within a few days along with the lowering of thyroid hormone. The Chilaiditi syndrome is a phenomenon

non where there is an interposition of the colon between the liver and the abdominal wall leading to clinical symptoms. but was asymptomatic in this case or might have been intermittent and episodic in nature. The presentations can vary significantly. Surgical consultation was done and no intervention was required. This case remained undiagnosed until recently. This case raises an interesting point that the syndrome may be intermittent in nature.

## DISCUSSION

Thyroid hormone plays a key role in regulating the body's metabolic processes. myxedema coma is an infrequent life threatening complication of hypothyroidism. Myxedema coma may be part of the natural progression of hypothyroidism or may be triggered in patients with chronic hypothyroidism by conditions such as drug overdose, myocardial infarction, cerebral infarction, injury, or cold exposure with previously existing chronic hypothyroidism.

It is thought to most commonly affect elderly women. Hypothyroidism is present in about 6% of the population to varying degrees, but myxedema coma is seen in only 0.1% of this sub group of patients. In clinical practice, myxedema coma is often diagnosed based on symptoms and physical examination, without waiting for laboratory results. Among the most significant features of myxedema coma are its cardiovascular complications, characterized by low voltage complexes on electrocardiogram.

Hypothyroid patients are often hypotensive due to decreased cardiac output, and patients with severe hypothyroidism may experience both decreased heart rate and myocardial contractility.<sup>6</sup> Although the patient described here did not have low blood pressure, or hyponatremia, his respiratory function was slightly impaired and his consciousness was affected. Hypoxemia has been described in 80% and hypercapnia in 54% of myxedema crisis patients.

Although this may be challenging to distinguish in practice, careful attention to detail and awareness of the possibility of hypothyroidism in patients will improve outcomes. In this case, appropriate management of hypothyroidism resulted in improvement.

Presentation of Chilaiditi syndrome can vary significantly. Many patients are completely asymptomatic and are diagnosed incidentally. While the disease can manifest itself with mild GI

symptoms for decades without any complications, feared complications include the development of volvulus or perforations.

## CONCLUSION

In summary, we described a rare case of myxedema coma with atypical features associated with chilaiditi syndrome. The patient presented with type II respiratory failure and a reduced level of consciousness without hypotension, or hyponatremia. Myxedema is rarely experienced in our practice. Therefore, myxedema coma must be considered in the differential diagnosis. Treatment should be started when a patient presents with coma, even in the absence of hypotension, hypothermia, hyponatremia, and hypoxemia.

Treatment for Chilaiditi syndrome varies depending on the severity of the symptoms. Patients who are asymptomatic do not require any intervention. Patients who present with mild or intermittent symptoms can often be treated initially with conservative management including bowel rest, IV fluids, bowel decompression, enemas, and laxatives. In many patients who undergo this treatment, repeat CT scans show resolution of

both the interposition and the clinical symptoms. Surgical treatment is reserved for patients whose symptoms do not resolve with conservative management or for suspicion of a complication such as ischemia or perforation.

## REFERENCES

1. Easily managed with thyroid hoSssrmone medications[1] <https://www.hindawi.com/journals/cricc/2016/3438080/>.
2. <https://www.ncbi.nlm.nih.gov/pmc/articles/PMC8895252/>.
3. Beynon J, Akhtar S, Kearney T. Predictors of Outcome in Myxoedema Coma. *Crit Care* (2008) 12:111. doi: 10.1186/cc6218 [PMC free article] [PubMed] [CrossRef] [Google Scholar].
4. Wall CR. Myxedema Coma: Diagnosis and Treatment. *Am Fam Physician* (2000) 62:2485-90. [PubMed] [Google Scholar].
5. Dawn Maldonado 1 , Urja Patel 1 , Nancy Tarlin 2 <https://pdfs.semanticscholar.org/d374/d51b28ed4eb07b945f6f7d020ffe45cee049.pdf>.
6. Sherif Elkattawy,1 Preanka Dhanoa,2 Juliet Kotys,2 Hardik Fichadiya,3 and Ari Eckman1<https://www.ncbi.nlm.nih.gov/pmc/articles/PMC8235691/>.