

A Study of Histopathological Analysis of Endometrium in Abnormal Uterine Bleeding in a Tertiary Care Centre

R. Aruna Geethanjali¹, Kalaivani Amitkumar², CD. Anand³, Shivashekar Ganapathy⁴

¹Final Year Post Graduate ²Associate Professor ³Assistant Professor ⁴Professor and Head, Department of Pathology, SRM Medical College Hospital and Research Centre, Potheri, Chengalpattu, Tamil Nadu 603211, India.

Abstract

Context: Abnormal uterine bleeding (AUB) is an important clinical entity in females.

Aims: The objective of the study was to study the histopathological (HPE) features of endometrium and to correlate its incidence with age factor in patients presenting with history of AUB.

Settings and Design: Methods and Material: 198 endometrial curetting and 2 endometrial biopsies were included. Samples that are autolysed and inadequate were excluded. Histopathological patterns were studied with Haematoxylin and Eosin (H&E) staining.

Statistical analysis used: Association between various histopathological patterns with age were assessed using chi square test.

Results: Maximum cases of AUB were in the perimenopausal women. The most common cause of AUB was cyclical endometrium followed by hyperplasia without atypia. Histopathological patterns significantly correlated with age factors in our study.

Conclusions: Our study provides specific stratification of patients with AUB based on many new differentials (compared to conventional approach) that would allow for specific treatment options and thereby improve quality of life for the patients.

Keywords: Abnormal Uterine Bleeding; Perimenopausal; Endometrium; Hyperplasia.

Corresponding Author:

Kalaivani Amitkumar, Associate Professor,
Department of Pathology, SRM Medical
College Hospital and Research Centre, Potheri,
Chengalpattu, Tamil Nadu 603211, India.

E-mail: drkalaivani1980@gmail.com

Received on 12.02.2019,

Accepted on 07.03.2019

How to cite this article:

R. Aruna Geethanjali, Kalaivani Amitkumar, C D. Anand et al. A Study of Histopathological Analysis of Endometrium in Abnormal Uterine Bleeding in a Tertiary Care Centre. Indian J Pathol Res Pract. 2019;8(2):199-204.



Introduction

Abnormal uterine bleeding (AUB) is an important clinical entity [1]. AUB has a lifetime prevalence of 30% during reproductive age group [2] that continues until menopause [3]. AUB accounts for 25% of total gynaecological surgeries [4]. AUB is defined as bleeding from the uterine corpus that is abnormal in volume, regularity and / or timing that has been present for the majority of last 6 months [1]. The need for proper evaluation in AUB is to categorise the patients for appropriate management according to the cause and to exclude atypical hyperplasia and carcinoma [5]. Hence the management is aimed at the improvement of symptoms and to improve better quality of life in women [3]. The aim of the study is to study the histopathological features of endometrium and to correlate its incidence with age group in patients presenting with the history of abnormal uterine bleeding.

Subjects and Methods

The present study was a cross sectional study done at Department of Pathology from March 2017 to June 2018. Endometrial curettings of 198 patients and endometrial biopsies of 2 patients were included in the study. Clinical history were collected from the patient's case files. Endometrial curetting and biopsy specimen were received in 10% formalin. According to the standard protocol for surgical grossing of endometrial biopsy or diagnostic curettage, all tissues were submitted not filling the cassette more than half full in every case [6]. Paraffin sections of 5µm thickness were stained by H&E for histopathological study. Samples were obtained for the study by endometrial curettage as well as endometrial biopsy. Endometrial curettage was done using the sharp edge of the curette and scrapings from anterior, posterior and lateral borders were obtained.

Categorical variables were reported using frequency and percentage. Statistical analysis was done using SPSS software version 17.0. Association between various histopathological patterns with age were assessed using chi square test. 'p' value of less than 0.05 was considered statistically significant ($p < 0.05$).

Results

Patient Characteristics

The age of the patients with AUB studied were

divided into three groups namely, reproductive, perimenopausal and post - menopausal. Patients' age ranged from 20-75 years with a mean age of 43.13 years. Maximum cases of AUB were found in age group 41-50 years (50.5%) followed by 18-40 years (35%) together accounting for almost two third of the cases. Least number of cases was reported in the age group more than 50 years (14.5%). Age group distribution of the study cases is represented in Table 1.

Table 1: Age group distribution of patients presenting with AUB

Age group	Frequency	Percentage (%)
18-40 years (reproductive)	70	35.0
41-50 years (perimenopausal)	101	50.5
>50 years (post menopausal)	29	14.5
Total	200	100

Among the 200 cases, the most common histopathological diagnosis was cyclical endometrium, proliferative pattern (Fig. 1), (23.0%) and secretory pattern (Fig. 2), (15.0%) together accounted for 38%, followed by hyperplasia without atypia (Fig. 3), (28.5%), the disordered proliferative endometrium (13.5%), atrophic endometrium (6.5%), endometrial polyp (5%), endometrial adenocarcinoma (3.5%), pill endometrium (2.5%), atypical hyperplasia (1.5%) and endometritis (1.0%). The distribution of various histopathological patterns in the study group is represented in Table 2.

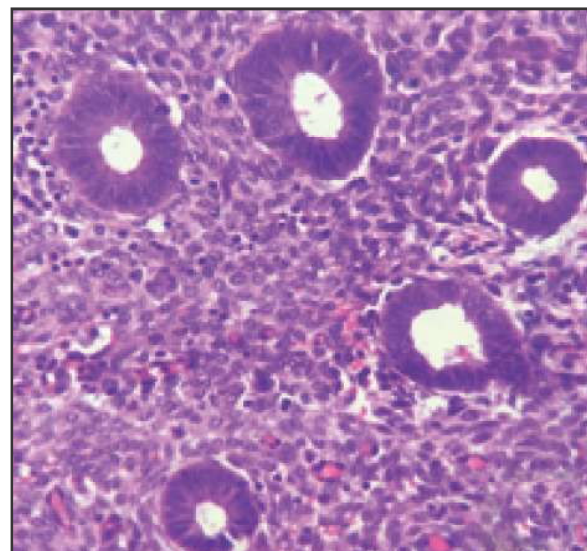


Fig. 1: Proliferative phase endometrium - Punched out, regular glands in a compact stroma H & E X 400

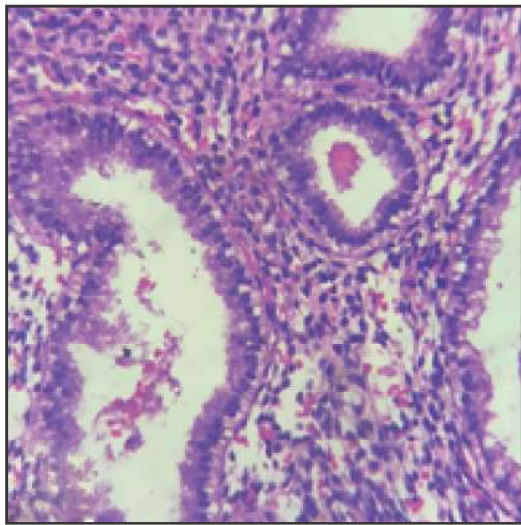


Fig. 2: Secretory phase endometrium - Glands with subnuclear vacuolations embedded in an oedematous stroma H & E x 400

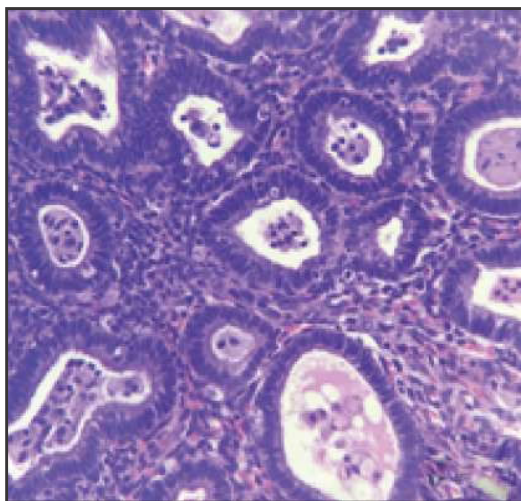


Fig. 3: Hyperplasia without atypia - Increased gland to stromal ratio composed of crowded glands with epithelial stratification and small amount of interspersed stroma. The nuclear polarity is maintained.

Correlations

The association between age and various histopathological patterns was significant with a p value of 0.0001. In the reproductive age group, the most common histopathological diagnosis was cyclical endometrium, proliferative phase endometrium (27.1%) and secretory pattern (24.3%), both together comprising nearly half of the patients, followed by simple hyperplasia without atypia (25.7%), and disordered proliferative endometrium (14.3%). The least common patterns were endometrial polyp (4.3%), pill endometrium (2.9%) and endometritis (1.4%). Atrophic pattern, hyperplasia with atypia and adenocarcinoma were totally absent in this age group.

In the perimenopausal age group, the most common histopathological pattern was hyperplasia without atypia (30.7%), followed by proliferative phase (26.7%), secretory phase (11.9%), disordered proliferative phase (11.9%), endometrial polyp (6.9%) and atrophic pattern (5.9%). The least common patterns were pill endometrium (3.0%), hyperplasia with atypia (2.0%) and endometritis (1.0%).

In the post menopausal age group the most common histopathological diagnosis was atrophic endometrium (24.1%), endometrial adenocarcinoma (24.1%), followed by hyperplasia without atypia (27.6%) and disordered proliferative endometrium (17.2%).

This indicates that cyclical endometrium is the most common cause for AUB in the reproductive age group and progression towards disordered proliferative pattern, hyperplasia and carcinoma increases with age factor. The association between age group and various histopathological patterns is represented in Table 3.

Table 2: Various histopathological patterns in patients presenting with AUB

Histopathological diagnosis	Total	Percentage (%)
Hyperplasia without atypia	57	28.5
Proliferative phase	46	23.0
Secretory phase	30	15.0
Disordered proliferative phase	27	13.5
Atrophic endometrium	13	6.5
Endometrial polyp	10	5.0
Adenocarcinoma endometrium	7	3.5
Pill endometrium	5	2.5
Hyperplasia with atypia	3	1.5
Endometritis	2	1.0
Total	200	100

Table 3: Association between Age and various Histopathological Patterns

Histopathological Diagnosis	Age Group (Years)			Total	(%)	Chisquare	Pvalue
	18-40	41-50	>50				
Hyperplasia without atypia	18 (25.7%)	31 (30.7%)	8 (27.6%)	57	28.5		
Proliferative phase	19 (27.1%)	27 (26.7%)	0	46	23.0		
Secretory phase	17 (24.3%)	12 (11.9%)	1 (3.5%)	30	15.0		
Disordered proliferative phase	10 (14.3%)	12 (11.9%)	5 (17.2%)	27	13.5		
Atrophic endometrium	0	6 (5.9%)	7 (24.1%)	13	6.5		
Endometrial polyp	3 (4.3%)	7 (6.9%)	0	10	5.0	81.198	0.0001
Adenocarcinoma endometrium	0	0	7 (24.1%)	7	3.5		
Pill endometrium	2 (2.9%)	3 (3.0%)	0	5	2.5		
Hyperplasia with atypia	0	2 (2.0%)	1 (3.5%)	3	1.5		
Endometritis	1 (1.4%)	1 (1.0%)	0	2	1.0		
Total	70 (100%)	101 (100%)	29 (100%)	200	100		

Discussion

In our study a total of 200 cases had been enrolled. Out of these cases the patients' age ranged between 20-75 years. Nearly half of them belonged to perimenopausal age group (50.5%), followed by the reproductive age group (35%) [Table 1], which is similar to the studies done by Soleymani et al in which perimenopausal age group was 61.6% [7] and Sweta et al., 53.98% [8] that can be explained due the increased incidence of intrauterine lesions in perimenopausal age group. This disagrees with the study done by Deka et al., 34% [9] in which reproductive age group was most commonly affected that can be explained by the increased incidence of pregnancy related complications in their study group.

In our study the most common histopathological pattern was cyclical endometrium, proliferative (23.0%) and secretory pattern (15.0%) together accounted for 38%, [Table 2], mainly affecting the reproductive age group. This association of cyclical endometrium with reproductive age group was highly significant in our study with a p value of 0.0001 [Table 3]. The cause for higher incidence of AUB in reproductive group can be explained due to imbalance between the levels of oestrogen and progesterone during the reproductive age period [10]. This was in concordance with other studies done by Abdullah et al that have reported 46.6% of cyclical endometrium [11], Abid et al., 34% [10] and Bhatta et al., 26.23% [12].

In our study the second most common histopathological pattern was hyperplasia (30%) [Table 2], most commonly affecting the perimenopausal women (32.7%). Bhatta et al. [12] have reported hyperplasia as second most common

histopathological pattern (18.03%), most commonly affecting the perimenopausal women (45.4%). Shah et al. [13] have reported hyperplasia (42.9%) as the second most cause of AUB that commonly affects the perimenopausal women (57.1%). Sajitha et al [14] have reported hyperplasia (25%) as the most common cause of AUB that commonly affects the perimenopausal age group (56.4%). The cause for high incidence of hyperplasia in perimenopausal age group is that as menopause approaches decreased number of ovarian follicles and increased resistance to gonadotrophic stimulation results in a decreased oestrogen level which cannot keep the normal endometrium growing [13].

In our study disordered proliferative endometrium was reported in 13.5% cases [Table2]. Maximum incidence of this finding (20.53%) is seen in study done by Doraiswami et al [15]. It is also a common cause of AUB in study done by Soleymani E et al. [7], where it accounted for 15.3% of cases.

In our study the incidence of atrophic endometrium was 6.5% [Table 2], that was mostly reported in postmenopausal women (24.1%), followed by perimenopausal women (5.9%) and is absent in reproductive age group [Table 3]. There was a positive correlation between atrophic endometrium and perimenopausal age group in our study with a highly significant p value of 0.0001 [Table 3]. These observations were similar to the previous studies done by Abid et al [10] and Sajitha et al. [14]. Atrophic endometrium is sometimes reported in perimenopausal women, but it is a common finding in post-menopausal women due to lack of ovarian oestrogen [10]. The exact reason for bleeding from atrophic endometrium is not known. It has been postulated that it may be due to anatomic vascular variations or local abnormal haemostatic mechanisms. Thin walled veins

superficial to the expanding cystic glands make the vessels subjected for injury [15].

In our study the incidence of endometrial polyp was 5.0% [Table 2]. Abid et al. [10] has reported highest incidence of polyps (14% of cases). Doraiswami et al. [15] have reported the second highest incidence of polyps (11.24%) in their study.

Malignancies are less common, but an important cause of abnormal uterine bleeding. In our study, 7 (3.5%) cases of endometrial adenocarcinoma were reported, most commonly affecting the post menopausal women (24.1%). This association of endometrial carcinoma with postmenopausal age group was highly significant in our study with a p value of 0.0001 [Table 3]. These observations are in concordance with previous studies like Doraiswami et al. [15] that have reported 4.4% cases of endometrial carcinoma, in which 72.2% of patients were postmenopausal women. Sweta et al. [8] have reported 27.77% cases of endometrial cancer, of which 32.5% of patients were postmenopausal women. Bhatta et al [12] have reported 5.74% of endometrial carcinoma, of which 17.9% of patients were postmenopausal women. In a previous study done by Dangal et al. [16] it is stated that a lower incidence of endometrial carcinoma is attributable to early childbearing and multiparity. Possibly the same factor contributed to a lower incidence of carcinoma in our patients. Few studies also state that in patients presenting with AUB and endometrial hyperplasia or malignancy, the probable incidence of synchronous tumour like Adult granulosa cell tumour of Ovary should also be kept in mind [17].

In our study the incidence of endometritis is 1.0%. A high incidence of endometritis is reported in previous studies done by Jairajpuri et al. [18], Bhatta et al. [12] and Patne et al. [19]. This difference can be explained due various factors such as hygienic conditions, socioeconomic status or exposure to any surgical intervention [10].

Conclusion

Abnormal uterine bleeding (AUB) is a common gynaecological problem with various underlying pathological conditions (non-neoplastic and neoplastic). The present study has further categorised the pathological conditions in patients with AUB by correlating various histomorphological patterns of the endometrium with age factor. The most common histopathological diagnosis was cyclical endometrium affecting the reproductive age group. In perimenopausal age group the most common

histopathological diagnosis was hyperplasia without atypia and in post menopausal age group it was endometrial carcinoma and atrophic endometrium. This specific stratification of patients with AUB based on many new differentials (compared to conventional approach) would allow for specific treatment options and thereby improve quality of life for the patients.

References

1. Whitaker L, Critchley HOD. Abnormal uterine bleeding. *Best Pract Res Clin Obstet Gynaecol.* 2016 Jul;34(1):54-65.
2. Maheux-Lacroix S, Mennen J, Arnold A, Budden A, Nesbitt-Hawes E, Won H, et al. The need for further surgical intervention following primary hysteroscopic morcellation of submucosal leiomyomas in women with abnormal uterine bleeding. *Aust N Z J Obstet Gynaecol.* 2018 Oct; 58(5):570-5.
3. Cheong Y, Cameron II, Critchley HOD. Abnormal uterine bleeding. *Br Med Bull.* 2017 Sep;123(1):103-14.
4. Sinha P, Yadav N, Gupta U. Use of Hysteroscopy in Abnormal Uterine Bleeding: An Edge Over Histopathological Examination. *J Obstet Gynecol India.* 2018 Feb;68(1):45-50.
5. Goldstein SR, Lumsden MA. Abnormal uterine bleeding in perimenopause. *Climacteric.* 2017 Sep 3;20(5):414-20.
6. Rosai J editor. *Rosai and Ackerman's surgical pathology.* 10th ed. Philadelphia, PA: Mosby Elsevier; 2011.
7. Soleymani E, Ziari K, Rahmani O, Dadpay M, Taheri-Dolatabadi M, Alizadeh K, et al. Histopathological findings of endometrial specimens in abnormal uterine bleeding. *Arch Gynecol Obstet.* 2014 Apr; 289(4):845-9.
8. Sweta A, Asha M, Kusum V. Histopathological study of endometrium in abnormal uterine bleeding women of all age groups in Western Rajasthan (400 cases). *International Journal of Basic and Applied Sciences.* 2014;4(3):15-8.
9. Deka RR, Saikia T, Handique A, Sonowal B. Histopathological Spectrum of endometrial changes in women presenting with abnormal uterine bleeding with special reference to endometrial malignancies: A two years hospital based study. *Annals of Applied Bio-Sciences.* 2016 May 12;3(2):151-157.
10. Abid M, Hashmi AA, Malik B, Haroon S, Faridi N, Edhi MM, Khan M. Clinical pattern and spectrum of endometrial pathologies in patients with abnormal uterine bleeding in Pakistan: need to adopt a more conservative approach to treatment. *BMC women's health.* 2014 Dec;14(1):132.

11. Abdullah LS, Bondagji NS. Histopathological pattern of endometrial sampling performed for abnormal uterine bleeding. *Bahrain Med Bull.* 2011 Dec;33(4):1-6.
 12. Bhatta S, Sinha AK. Histopathological study of endometrium in abnormal uterine bleeding. *Journal of Pathology of Nepal.* 2012 Jan 1;2(4):297-300.
 13. Shah R, Dayal A, Kothari S, Patel S, Dalal B. Histopathological interpretation of endometrium in abnormal uterine bleeding. *Int J Med Sci Public Health.* 2014;3(4):452.
 14. Sajitha K, Shetty KJ, Hegde P, KishanPrasad H, Padma S, Permi H. Study of histopathological patterns of endometrium in abnormal uterine bleeding. *CHRISMED J Health Res.* 2014;1(2):76.
 15. Doraiswami S, Johnson T, Rao S, Rajkumar A, Vijayaraghavan J, Panicker VK. Study of Endometrial Pathology in Abnormal Uterine Bleeding. *J Obstet Gynecol India.* 2011 Aug;61(4):426-30.
 16. Dangal G. A study of endometrium of patients with abnormal uterine bleeding at Chitwan Valley. *Kathmandu Univ Med J KUMJ.* 2003 Jun;1(2):110-2.
 17. Jagtap SV, Beniwal A, Shah H, Kshirsagar NS, Jagtap SS. Endometrial Carcinoma Associated with Bilateral Ovarian Adult Granulosa Cell Tumor: Synchronous Malignancy. *Indian Journal of Pathology.* 2015 May 1;4(2):77.
 18. Jairajpuri ZS, Rana S, Jetley S. Atypical uterine bleeding-Histopathological audit of endometrium A study of 638 cases. *Al Ameen J Med Sci.* 2013; 6(1):21-8.
 19. Patne SS, Sirpurkar MS. Validation of endometrial curettage in abnormal uterine bleeding in a teaching institute of central India: A prospective study. *Int J Med Res Health Sci.* 2013;2(3):491.
-