

## Comparative Evaluation between Ropivacaine versus Ropivacaine with Dexmedetomidine in Ultrasound Guided Parasagittal Brachial Plexus Approach in Upper Limb Orthopedic Surgeries

Karthik GS<sup>1</sup>, Sudheer R<sup>2</sup>, Mahima KB<sup>3</sup>, Shivasharn K Hosalli<sup>4</sup>,  
S. Rangalakshmi<sup>5</sup>, Nivedha P<sup>6</sup>

### Author's Affiliation:

<sup>1,2</sup>Professor, <sup>3</sup>Professor and Head of Department, <sup>3,4,6</sup>Junior Resident, Department of Anesthesiology, Rajarajeswari Medical College and Hospital, Bangalore, Karnataka 560074, India.

### Abstract

**Background:** Ropivacaine has been used for brachial plexus block because of its safety profile. Dexmedetomidine is one of the adjuvants added to Ropivacaine as it is known to potentiate sensory and motor blockade.

**Aim:** Our aim was to compare and assess the effectiveness of adding Dexmedetomidine as an adjuvant to 0.75% ropivacaine in supraclavicular brachial plexus block using parasagittal approach for duration of analgesia primarily. Onset and duration of sensory and motor blockade were also the variables compared.

**Materials and methods:** A prospective single blinded randomized comparative clinical study was carried out among in eighty patients of ASA Grade I and II between the ages of 20-60yrs, scheduled for elective upper limb orthopedic surgeries involving the forearm under supraclavicular brachial plexus block using parasagittal approach. Group R received 20ml of 0.75% ropivacaine along with 1ml of normal saline while Group RD received 20ml of 0.75% ropivacaine along with 0.5mcg/kg dexmedetomidine constituted to 1ml. Sensory, motor blockade & analgesic efficacy was determined.

**Statistical Analysis:** Student t-test was used for demographic and hemodynamic data analysis. Unpaired t-test was used for evaluation of data which consisted of onset, duration of sensory and motor blockade along with duration of analgesia. The results were statistically significant if p-value <0.05. P-value <0.001 was considered highly significant.

**Results:** Duration of analgesia lasted longer in Group RD (991.09 ± 16.34) when compared to Group R (542.57 ± 18.37). Onset time for sensory and motor blockade were rapid in Group RD (7.71 ± 1.23, 13.66 ± 1.03) when compared to Group R (10.14 ± 1.00, 18.60 ± 1.54). Duration of sensory blockade was prolonged in Group RD (780.26 ± 31.43) when compared to Group R (455.57 ± 20.28). Duration of motor blockade was also enhanced in Group RD (725.57 ± 25.18) when compared to Group R (397.74 ± 24.92).

**Conclusion:** Addition of Dexmedetomidine to Ropivacaine provided superior analgesia along with faster onset and longer duration of sensory and motor blockade.

**Keyword:** Brachial Plexus; Supraclavicular; Parasagittal; Ultrasound; Ropivacaine; Dexmedetomidine.

### How to cite this article:

Karthik GS, Sudheer R, Mahima KB et al./Comparative Evaluation between Ropivacaine versus Ropivacaine with Dexmedetomidine in Ultrasound Guided Parasagittal Brachial Plexus Approach in Upper Limb Orthopedic Surgeries/Indian J Anesth Analg. 2021; 8(2): 197-203.

**Corresponding Author:** Mahima KB, Junior Resident, Department of Anesthesiology, Rajarajeswari Medical College and Hospital, Bangalore, Karnataka 560074, India.

**E-mail:** mahimabalakrishnaiah@gmail.com



This work is licensed under a Creative Commons Attribution-NonCommercial-ShareAlike 4.0.

## Introduction

Brachial plexus block has evolved as a safe alternative to general anesthesia for upper limb surgery and for relief of perioperative pain. Advancements in regional anesthesia techniques in terms of local anesthetic drugs, newer adjuvant drugs and use of ultrasound for safe and successful conduct of block has increased its popularity. It helps in reduced hospital stay, less financial burden and also leads to avoidance of undesirable side-effects of general anesthesia.<sup>1</sup>

Ropivacaine is a local anaesthetic effective for both intraoperative anaesthesia and post-operative analgesia by binding to open voltage-gated Na<sup>+</sup> channels thereby increasing the frequency of nerve depolarization in a reversible and concentration-dependent manner. Lower lipid solubility of ropivacaine causes greater sensory and motor differential blockade, which is advantageous.<sup>2,3</sup>

Several adjuvants may increase the duration of nerve block. Adjuvant drugs such as alpha-2 adrenergic receptor agonists, opioids, ketamine, dexamethasone and others can be used to increase block duration. Dexmedetomidine is a highly selective alpha-2 adrenergic receptor agonist,<sup>4</sup> its action in peripheral nerve blockade is due to increase in hyperpolarization activated cation current that prevents the nerve from returning to resting membrane potential.<sup>1</sup>

## Methods

After obtaining institutional ethical committee clearance, patients belonging to ASA status I & II, aged between 20-60 yrs scheduled for elective upper limb (forearm) orthopedic surgeries under ultrasound guided supraclavicular brachial plexus block using parasagittal approach at Rajarajeswari Medical College and Hospital, were recruited for a prospective randomized single blinded study. Patients with bleeding disorders, uncontrolled diabetes mellitus, renal and liver diseases, pregnant and lactating women, patients with epilepsy, neurological diseases & known hypersensitivity to local anesthetics were excluded from the study. The patients in whom block was not found effective were excluded from the study and given general anaesthesia.

Patients were randomly allocated into two groups based on open envelope method, Group R and RD. Based on a previous study conducted by Kathuria et al, with a confidence level of 80% and keeping the mean time of duration of analgesia

as one of the primary variables at the p value of < 0.05, we selected 40 patients in each group for our study. Group R - patients received 20ml of 0.75% ropivacaine along with 1ml of normal saline. Group RD - patients received 20ml of 0.75% ropivacaine along with 0.5 mcg/kg of dexmedetomidine constituted to 1ml.

All patients were subjected to detailed pre-anesthetic workup and evaluation. On the day before surgery patients were attended, examined, explained regarding the procedure and taught to interpret the visual analogue scale (VAS). Written informed consent was taken.

Routine fasting guidelines were maintained. Premedication was given with oral alprazolam 0.25 mg and ranitidine 150 mg night before surgery and inj. Ondansetron 4mg & inj. Ranitidine 50mg, 30 minutes prior to surgery.

After shifting the patient to operation theatre, standard anesthesia monitoring in the form of baseline measurement of heart rate, non-invasive arterial blood pressure, ECG and oxygen saturation (SpO<sub>2</sub>) were started. Intravenous line was secured with 18G cannula in the unaffected limb and I.V. Fluids were given according to the requirement.

The tray containing all necessary drugs and equipments for giving brachial plexus block was prepared. Both groups receiving the block were unaware of the composition of the drugs used. Patients were positioned supine on the table with pillow under the shoulder with the head turned 45 degrees to the contralateral side to make the landmarks more prominent.

An ultrasound machine (sonosite) and a 7-13 MHz linear type probe used, after strict aseptic skin preparation probe was placed in parasagittal plane in the anterior part of supraclavicular fossa, after local anesthetic infiltration with lignocaine, a 23G spinal needle was advanced from the anterior border of the trapezius muscle.

A 10cm extension was attached to the needle. Using an in-plane technique the needle was advanced till the tip entered the sheath of plexus, and then volume of prepared local anesthetic mixture either with 1ml of normal saline or 0.5mcg/kg of dexmedetomidine constituted to 1ml was injected after negative aspiration.

Sensory and motor blocks were assessed soon after the block was given. Post operatively the patients were followed up for the duration of analgesia and other block characteristics at regular intervals.

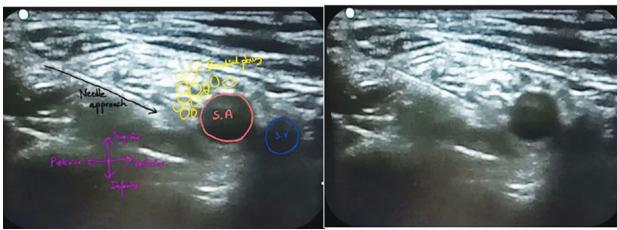


Fig. 1: Ultrasound image of brachial plexus in parasagittal approach.

Since we used Dexmedetomidine as an adjuvant, sedation score was assessed according to the Ramsay Sedation Scale (RSS) intra-operatively & post-operatively.

Any adverse events like bradycardia, hypotension, hypoxemia, sedation, respiratory depression, nausea and vomiting were noted. Bradycardia was defined as heart rate <50 bpm, and hypotension was defined as decline in blood pressure <20% from the baseline recordings. Hemodynamics were assessed intra-operatively and post-operatively. Visual Analogue Scale was used to assess pain and if VAS>4, rescue analgesic was considered. Rescue analgesic used in the post-operative period was inj. paracetamol 1g i.v slow infusion and its requirement in 24 hours post operative period was noted in both groups and computed accordingly.

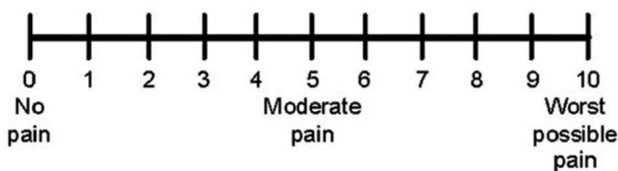


Fig. 2: Visual analogue scale.

Data was computed and entered in MS excel/analyzed using SPSS software version 16. Student t-test was used for demographic and hemodynamic data analysis. Unpaired t-test was used for evaluation of data which included onset, duration of sensory and motor blockade along with duration of analgesia. The results were statistically significant if p-value <0.05. P-value <0.001 was considered highly significant.

## Results

Eighty patients were enrolled for the study as per the study protocol mentioned above, we did not have any dropouts of patient's in our study. There was no block failure noted among patients in any of the groups. Both the groups R and RD were comparable with respect to age, sex distribution, weight, height (demographic variables), ASA

grading and duration of surgery (Table 1). Duration of analgesia lasted longer in Group RD (991.09 ± 16.34) when compared to Group R (542.57 ± 18.37) (p-value <0.001) (Table 2). As per the observation noted in Table 3, the onset time for sensory and motor blockade were rapid in Group RD (7.71 ± 1.23, 13.66± 1.03) when compared to Group R (10.14 ± 1.00, 18.60 ± 1.54) with p-value <0.05. By adding Dexmedetomidine to Ropivacaine in our study, we noted early occurrence of sensory and motor blockade.

Duration of sensory blockade was prolonged in Group RD (780.26 ± 31.43) when compared to Group R (455.57 ± 20.28) with p-value of <0.001 (Table 4). Duration of motor blockade was also enhanced in Group RD (725.57 ± 25.18) when compared to Group R (397.74 ± 24.92) (p-value <0.001) (Table 4).

Sedation scores were higher in Group RD when compared to Group R (Figure 10). VAS scores were less in patients of Group RD which led to reduced total analgesic requirement in Group RD (0.74 ± 1.12) when compared to Group R (2.34 ± 1.45) (p-value <0.001) (Table 4) (Figure 9). As per the observations noted in Figure 6,7,8 hemodynamic stability was maintained in patients of both the groups without any significant variations.

Two patients in Group RD had bradycardia which responded well to inj. glycopyrrolate. One patient in Group RD had transient hypotension. This patient responded to i.v fluids and 6mg bolus of i.v mephentramine. We did not notice hypoxemia, nausea, vomiting and respiratory depression in any of the patients among both the groups (Table 5).

Table 1: Demographic Profile.

Demographic Profile	Group R	Group RD	P-value
Age (in yrs)	38.62 ± 13.20	39.22 ± 15.31	0.411
Height (in cms)	158.74 ± 5.71	159.6 ± 5.14	0.527
Weight (in kgs)	60.27 ± 9.04	61.69 ± 8.93	0.483
Sex (male/female)	21(52.5%)/19(47.5%)	20(50%)/20(50%)	0.832
ASA distribution (I/II)	18(45%)/22(55%)	21(52.5%)/19(47.5%)	0.636
Duration of Surgery (in mins)	68.29± 19.42	63.57± 19.54	0.315

P-value not significant

**Table 2:** Duration of Analgesia.

Variables	Group R	Group RD	P-value
Duration of Analgesia (in min)	542.57 ± 18.37	991.09± 16.34	<0.001
Rescue analgesia-paracetamol (g)	2.34 ± 1.45	0.74 ± 1.12	<0.001

P-value <0.001, statistically significant

**Table 3:** Onset time of Sensory and Motor block.

Variables	Group R	Group RD	P-value
Onset of sensory block (in min)	10.14 ± 1.00	7.71± 1.23	<0.001
Onset of motor block (in min)	18.60 ± 1.54	13.66± 1.03	<0.001

P-value <0.001, statistically significant

**Table 4:** Duration of Sensory and Motor block.

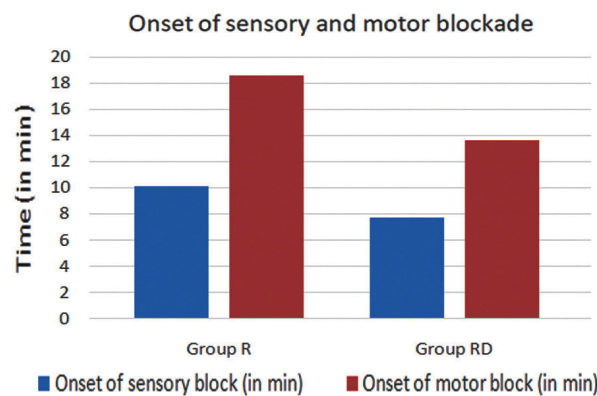
Variables	Group R	Group RD	P-value
Duration of sensory block (in min)	455.57± 20.28	780.26± 31.43	<0.001
Duration of motor block (in min)	397.74 ± 24.92	725.57 ± 25.18	<0.001

P-value <0.001, statistically significant

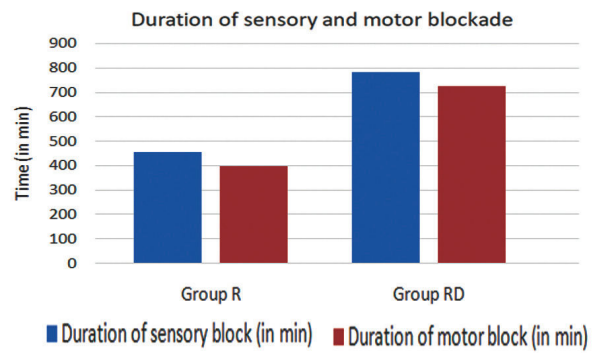
**Table 5:** Side effects.

Variables	Group R	Group RD
Hypotension	0	1
Nausea	0	0
Vomiting	0	0
Bradycardia	0	2
Hypoxemia	0	0
Respiratory Depression	0	0

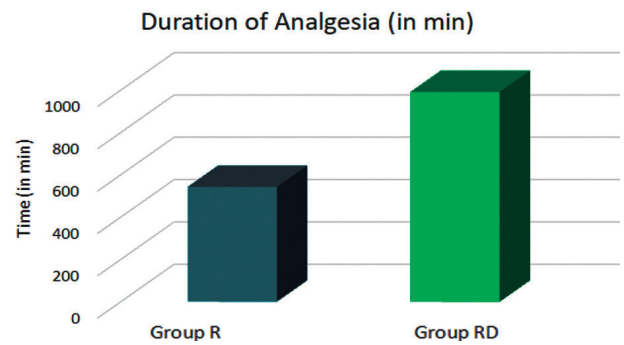
P value >0.05, insignificant



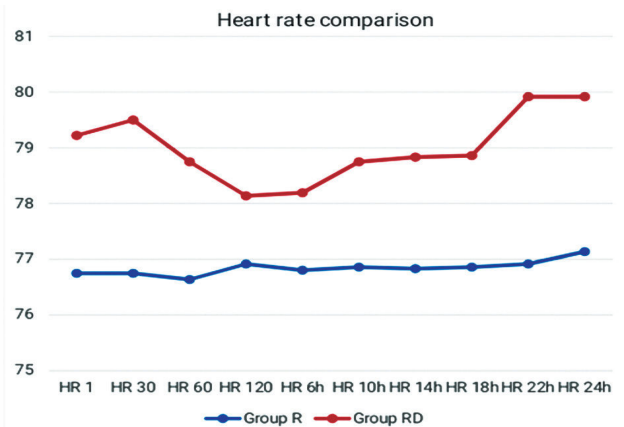
**Fig. 3:** Graphical representation of onset of sensory and motor blockade.



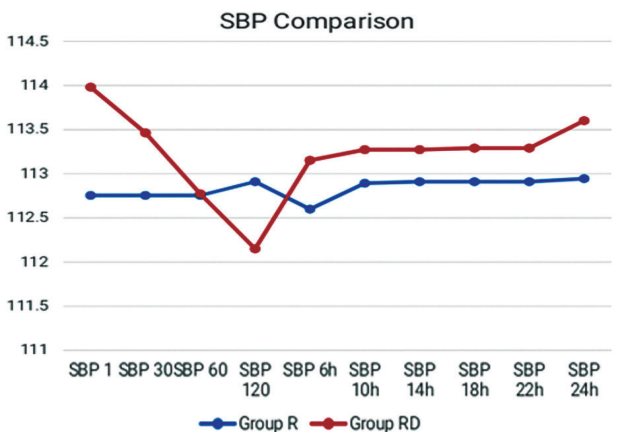
**Fig. 4:** Graphical representation of duration of sensory and motor blockade.



**Fig. 5:** Graphical representation of duration of analgesia.



**Fig. 6:** Graphical Representation of Heart rate comparison between groups.



**Fig. 7:** Graphical representation of Systolic blood pressure comparison between groups.

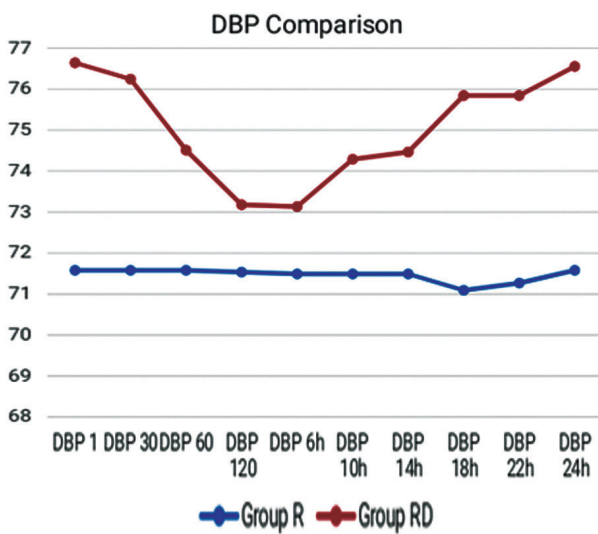


Fig. 8: Graphical Representation of Diastolic blood pressure comparison between groups.

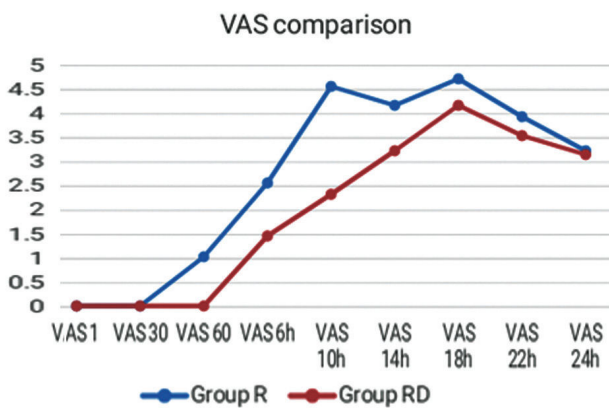


Fig. 9: Graphical representation of VAS comparison between groups.

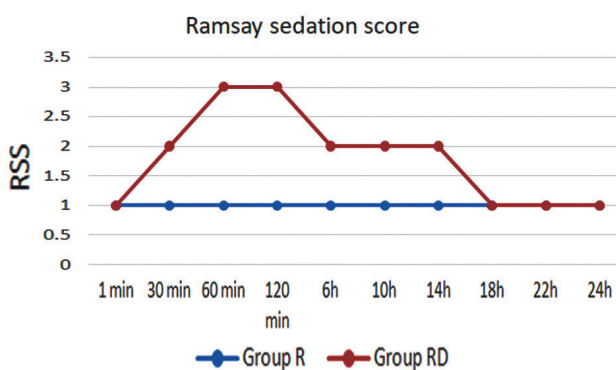


Fig. 10: Graphical representation of Ramsay sedation score comparison between groups.

## Discussion

Supraclavicular blocks are performed at the level of the brachial plexus trunks. Ultrasound guided blocks provides rapid onset, predictable and dense anesthesia along with high success rate. Local anesthetics alone for supraclavicular brachial

plexus block provide good operative conditions but have a shorter duration of postoperative analgesia.<sup>5</sup>

General anesthesia when used for patients undergoing upper limb surgeries results in significant hemodynamic disturbances along with accompanying adverse effects including nausea, vomiting and respiratory insufficiency, to avoid all these adverse effects brachial plexus block is commonly used. With the advent of ultrasound, the nerve clusters can be easily imaged and block quality is also impressive. Intra-arterial injection and pneumothorax can be easily avoided.

Ropivacaine is a local anaesthetic effective for both intraoperative anaesthesia and post-operative analgesia by binding to open voltage-gated Na<sup>+</sup> channels thereby increasing the frequency of nerve depolarization in a reversible and concentration-dependent manner. Lower lipid solubility of ropivacaine causes greater sensory and motor differential blockade. It is considered to be a cardio stable local anesthetic without accompanying neurotoxicity.<sup>2,3</sup>

Several adjuvants may increase the duration of nerve block. Adjuvant drugs such as alpha-2 adrenergic receptor agonists, opioids, ketamine, dexamethasone and others can be used to increase block duration. Dexmedetomidine is a highly selective alpha-2 adrenergic receptor agonist,<sup>4</sup> its action in peripheral nerve blockade is due to increase in hyperpolarization activated cation current that prevents the nerve from returning to resting membrane potential.<sup>1</sup>

Supraclavicular approach described by Chan et.al<sup>8</sup> with a probe resting posterior to clavicle, with posterolatero-anteromedial orientation provides a very stable location in terms of anatomical delineation.

Similar to the study conducted by Adrian Searle et.al<sup>6</sup> in our study, we have used posterior parasagittal approach to the brachial plexus at the supraclavicular level, utilizing the arc of the first rib to provide a deep limit to needle transit, and probe stability by resting against the scalene muscles medially, and clavicle anteriorly.<sup>6</sup> In this approach, subclavian vein is well-separated from the brachial plexus and the subclavian artery, with the plexus positioned posterior to the artery.

Injury to major structures before the needle approaches the brachial plexus is almost prevented. This technique ensures that the needle tip does not trespass the first rib or the pleural dome eliminating the risk of pneumothorax. So, we used this approach.

Lot of studies are being done using Dexmedetomidine as an adjuvant to local anesthetics, accordingly superiority has been established by using Dexmedetomidine perineurally in various studies.

In our study, we used 0.5mcg/kg of Dexmedetomidine as an additive to Ropivacaine and we found that Dexmedetomidine prolonged the duration of sensory and motor blockade. Moreover, even the duration of analgesia was also enhanced (which was our primary objective). The rescue analgesic medication used in the post-operative period was of lesser doses in the group which received Dexmedetomidine as an adjuvant (Group RD). These observations in our study correlates to a similar study which was conducted by Gurajala et.al.<sup>2</sup> They used 50mcg of Dexmedetomidine as an adjuvant to 0.5% Ropivacaine and found that onset of motor block was earlier and durations of analgesia, sensory and motor blockade were significantly prolonged in group who received Dexmedetomidine.

In a study conducted by Suneet Kathuria et.al<sup>1</sup> they found that sensory and motor block onset was earlier in group who received Dexmedetomidine. The duration of sensory and motor block, duration of analgesia was also prolonged in group who received Dexmedetomidine perineurally when compared with group who received intravenous Dexmedetomidine.

Our study correlates with the study conducted by Faraj et.al<sup>18</sup> wherein they randomized patients into three groups, Dex-P, Dex-IV and control group, duration of analgesia was 10.9 hours on addition of 0.5 mcg/kg Dexmedetomidine to 0.5 % Ropivacaine (Dex-P). Dexmedetomidine also reduced the 24-hour cumulative morphine consumption to 63.9mg (Dex-P) compared to Group Dex-IV.

In one of the studies conducted by Srinivasa Rao et.al<sup>17</sup> they randomly allocated patients into Group LD50 and Group LD100. Group LD50 received 0.5% levobupivacaine plus 50mcg of dexmedetomidine. Group LD100 received 0.5% levobupivacaine plus 100mcg of dexmedetomidine. They concluded that 100mcg dose of dexmedetomidine in brachial plexus block hastens the onset and prolongs the duration of sensorimotor blockade and analgesia, but with higher incidence of bradycardia and sedation. Keeping this in consideration, we have used 0.5mcg/kg of Dexmedetomidine rather than 1mcg/kg dosage. In a study conducted by Ranjit et.al<sup>16</sup> they concluded that perineural dexmedetomidine prolonged the analgesic duration and reduced 24-hour postoperative analgesic consumption

(8h 36min +/- 1h 36min and 10h 42min +/- 1h 36min) when used as an adjuvant to bupivacaine in fascia iliaca compartment block. They concluded that intravenous dexmedetomidine is less efficacious than perineural dexmedetomidine in terms of evaluating block characteristics. When intravenous analgesics were used for patients for postoperative analgesia in comparison to perineural administration of Dexmedetomidine, it was derived that perineural adjuvant added to local anesthetic was more efficacious in terms of analgesia.

Sarita et.al<sup>11</sup> conducted a study to compare the efficacy between the two alpha-2 agonists, dexmedetomidine and clonidine in supraclavicular brachial plexus block, they found out that the patients who had received Dexmedetomidine had prolonged duration of analgesia (456+/-97min) when compared to patients who received clonidine (289+/-62 min), thus they derived that Dexmedetomidine when compared to clonidine provided superior quality of block.

Dexmedetomidine when used perineurally was associated with bradycardia and hypotension as reported by Esmagolu et.al<sup>15</sup> wherein they used 100mcg of dexmedetomidine to levobupivacaine for brachial plexus block. Hence, we chose 50mcg of Dexmedetomidine, we did not notice any significant bradycardia or hypotension.

As postulated by Guo TZ et.al<sup>12</sup> alpha-2 agonists prevent the release of norepinephrine in the locus coeruleus causing sedation and hypnosis, they also terminate propagation of pain signals leading to pain relief. They were of the opinion that stimulation of alpha-2 receptors brings about sedation, analgesia, and anxiolysis.

Eisenach JC et.al<sup>13</sup> in their clinical review emphasized the importance of alpha-2 agonists in reducing the anesthetic drug requirements by virtue of their sedative, analgesic, antihypertensive and antiemetic effects.

Dexmedetomidine has emerged as an adjuvant for local anesthetics in epidural, intrathecal and other peripheral nerve blocks as suggested by Ribeiro RN et.al.<sup>14</sup> The sedation caused by alpha-2 agonists is thought to be due to central inhibition of substance P release in the nociceptive pathway and it has well been documented that patients are easily arousable. There were no problems when side effects were taken into consideration, as we did not notice any major adverse effects. Dexmedetomidine in the dose of 50 mcg prolongs analgesic duration. Analgesic requirements were minimal in patients in whom Dexmedetomidine was used.

Dexmedetomidine, thus acted as a good additive to Ropivacaine. Our study has provided superior block characteristics along with prolonged post-operative analgesia with addition of Dexmedetomidine as an adjuvant to 0.75% Ropivacaine when compared to Ropivacaine alone in supraclavicular brachial plexus block. Our study had some limitations, we chose 50mcg of dexmedetomidine as earlier studies had a mention of bradycardia and hypotension with higher doses. Hence, we evaluated the efficacy of lower dose concentration of dexmedetomidine in block keeping in view of not causing any adverse effects. However, further studies need to be carried out with larger samples to validate our observations using different dosage protocols.

### Conclusion

We conclude from our present study that addition of 0.5mcg/kg of Dexmedetomidine to 0.75% Ropivacaine enhanced the quality of block as the duration of analgesia was significantly prolonged and onset of both sensory and motor blockade was rapid. It also prolonged the duration of sensory and motor blockade, making it as one of the potential adjuvants for ropivacaine in upper limb forearm orthopedic surgeries.

Financial Support and Sponsorship: NIL

Conflicts of Interest: No conflicts of interest.

### References

1. Kathuria S, Gupta S, Dhawan I. Dexmedetomidine as an adjuvant to ropivacaine in supraclavicular brachial plexus block. *Saudi journal of anaesthesia*. 2015 Apr;9(2):148.
2. Gujarala I, Thippampall AK, Durga P, Gopinath R. Effect of perineural dexmedetomidine on the quality of supraclavicular brachial plexus block with 0.5% ropivacaine and its interaction with general anaesthesia. *Indian J Anaesth* 2015; 59:89-95.
3. Taylor A, McLeod G. Basic pharmacology of local anaesthetics. *BJA education*. 2020 Feb 1;20(2):34-41.
4. Keplinger M, Marhofer P, Kettner SC, Marhofer D, Kimberger O, Zeitlinger M. A pharmacodynamic evaluation of dexmedetomidine as an additive drug to ropivacaine for peripheral nerve blockade: a randomised, triple-blind, controlled study in volunteers. *European Journal of Anaesthesiology | EJA*. 2015 Nov 1;32(11):790-6.
5. Das A, Majumdar S, Halder S, Chattopadhyay S, Pal S, Kundu R, Mandal SK, Chattopadhyay S. Effect of dexmedetomidine as adjuvant in ropivacaine-induced supraclavicular brachial plexus block: A prospective, double-blinded and randomized controlled study. *Saudi journal of anaesthesia*. 2014 Nov; 8(Suppl 1): S72.
6. Searle A, Niraj G. Ultrasound-guided brachial plexus block at the supraclavicular level: A new parasagittal approach. *Int J Ultrasound Appl Technol Perioper Care* 2010; 1:19-22.
7. Winnie AP. Historical considerations. In: *Plexus Anaesthesia, Perivascular Techniques of the Brachial Plexus*. Philadelphia: WB Saunders 1983;68-69.
8. Chan VWS, Perlas A, Rawson R, Odukoya O. Ultrasound-Guided Supraclavicular Brachial Plexus Block. *Anaesth Analg* 2003; 97:1514-17.
9. Sekar C, Mistry T, Senthilkumar B, Elayavendhan K. Ultrasound guided subclavian perivascular block: The modified parasagittal approach. *Saudi J Anaesth* 2019; 13:256-7.
10. Kuthiala G, Chaudhary G. Ropivacaine: A review of its pharmacology and clinical use. *Indian Journal of Anaesthesia*. 2011;55(2):104.
11. Swami SS, Keniya VM, Ladi SD, Rao R. Comparison of dexmedetomidine and clonidine ( $\alpha_2$  agonist drugs) as an adjuvant to local anaesthesia in supraclavicular brachial plexus block: A randomised double-blind prospective study. *Indian J Anaesth* 2012; 56:243-9.
12. Guo TZ, Jiang JY, Buttermann AE, Maze M. Dexmedetomidine injection into locus coeruleus produces antinociception. *Anesthesiology*. 1996; 84: 873-881.
13. Eisenach JC, Dekock M, Klimscha W. Alpha (2) adrenergic agonists for regional anaesthesia. A clinical review of clonidine (1984-1995). *Anesthesiology* 1996; 85: 655-74.
14. Riberio RN, Nascimento JP. The use of dexmedetomidine in anaesthesiology. *Rev Bras Anesthesiol* 2003; 53: 97-113
15. Esmaoglu A, Mizrak A, Akin A, Turk Y, Boyaci A. Addition of dexmedetomidine to lidocaine for intravenous regional anaesthesia. *Eur J Anaesthesiol*. 2005; 22: 447-451.
16. Sivakumar RK, Panneerselvam S, Cherian A, Rudingwa P, Menon J. Perineural vs. intravenous dexmedetomidine as an adjunct to bupivacaine in ultrasound guided fascia iliaca compartment block for femur surgeries: A randomized control trial. *Indian J Anaesth* 2018; 62:851-7.
17. Nallam SR, Chiruvella S, Karanam S. Supraclavicular brachial plexus block: Comparison of varying doses of dexmedetomidine combined with levobupivacaine: A double-blind randomized trial. *Indian J Anaesth* 2017; 61:256-61.
18. Abdallah FW, Dwyer T, Chan VW, Niazi AU, Ogilvie-Harris DJ, Oldfield S, Patel R, Oh J, Brull R. IV and perineural dexmedetomidine similarly prolong the duration of analgesia after interscalene brachial plexus block: a randomized, three-arm, triple-masked, placebo-controlled trial. *Anesthesiology*. 2016 Mar;124(3):683-95.