

Original Article

COVID-19 Associated Mucormycosis (CAM): A Clinico Histopathological Study of at A Tertiary Care Centre**Sunil V Jagtap¹, Swati S Jagtap², Atul Hulwan³, Snigdha A Vartak⁴,
Divya Brahmhatt⁵, Shubhang Monpara⁶****How to cite this article:**

Sunil V Jagtap, Swati S Jagtap, Atul Hulwan, et. al./COVID-19 Associated Mucormycosis (CAM): A Clinico Histopathological Study of at A Tertiary Care Centre/J Pathol Res Pract 2022;11(1):19-26.

Abstract

During the current pandemic of COVID-19 there are increased cases with super infections by mucormycosis. This study is performed with an aim to evaluate clinico histomorphological features of COVID-19 associated mucormycosis(CAM).

Material and Methods: A total of 3365 COVID 19 positive cases were reported during the last 8 months. A total of 494 patients with COVID 19 were admitted for >24 hours during this study period. Among these 13 cases of mucormycosis were diagnosed. All cases were positive for Reverse transcriptase polymerase chain reaction RT PCR assay. The detail clinical examination and required investigations were included. The operative details and histopathological gross and microscopic findings were noted. The characteristics type of inflammation, necrosis, fungal hyphae, presence of granulomatous reaction, angioinvasion and perineural invasion, bony tissue pathology were noted. The special stain like PAS, Grocott Gomori's methenaminesilver stain were done. The data was analysed.

Results: The age range of patients was from 10 to 65 year. There was a male preponderance. The 6 (46%) patients had pre existing diabetes mellitus, 3 (23%) patients had received steroids during the treatment, 1 patient had co-existing HIV/ AIDS infection, 3 (23%) patients had history of hypertension. The radio imaging revealed soft tissue swelling in the preseptal, malar, premaxillary and retrobulbar regions with paranasal sinusitis. Nasal involvement was seen in all 13 cases (100%), orbital involvement in 5 cases (37%) and cerebral involvement in 3 cases (23%). On histomorphological study characteristic fungal hyphae of mucormycosis were seen in all cases. The acute or chronic inflammation, necrosis were seen in all cases. The granulomatous reaction was seen in 23%, angioinvasion in 46% and perineural invasion in 15% cases. One case revealed co-existing HIV/ AIDS and another with actinomycosis co-infection.

Conclusions: In COVID 19 patients Mucormycosis is one of the important associated infection within this pandemic. This increase in incidence is related to various risk factors being systemic preexisting disease, IV infection, diabetics, use of steroid and immunosuppression etc. The mucormycosis patients are treated by early identification, monitoring risk factors, followed by proper surgical intervention and administration of the appropriate antifungal medication. This histopathological study will be of importance in early diagnosis and management of patients with COVID-19 and would help improve outcomes in world pandemic time. We are presenting these cases of CAM for its clinical, radio imaging, and histopathological findings.

Keywords: COVID-19; Mucormycosis; Fungal infections; RT-PCR Test.

Author Affiliation: ¹Professor, ²Associate Professor, ³Assistant Professor, ^{4,5,6}Assistant Lecturer, Department of Pathology, Krishna Institute of Medical Sciences, Deemed University, Karad 415110, Maharashtra, India.

Corresponding Author: Sunil Vitthalrao Jagtap, Professor, Department of Pathology, Krishna Institute of Medical Sciences, Deemed University, Karad 415110, Maharashtra, India.

E-mail: drsvjagtap@gmail.com

Received on: 31.12.2021

Accepted on: 01.02.2022

Introduction

The coronavirus disease 2019 (COVID-19) infection caused by the novel severe acute respiratory syndrome coronavirus 2 (SARS-CoV-2).¹ WHO first noted of this new virus on 31 December 2019, following a report of a cluster of cases of 'viral pneumonia' in Wuhan, China.² There have been confirmed 198,778,175 cases of COVID-19, including 4,235,559 deaths, reported globally to

WHO as of 3 August 2021. India confirmed cases were 31,726,507 with 425,195 deaths as on 3 August 2021, reported to WHO.

A wide range of bacterial and fungal co infections may exist and may be associated with preexisting morbidity.³ During the current pandemic of CAM is being looked upon as one of the coinfection. The co existing immunosuppression, pre-existing comorbidities such as diabetes mellitus as well as possibility of nosocomial infection are risk factors for occurrence of mucormycosis in COVID-19 positive patients. Corticosteroid therapy and a past history of chronic pulmonary disease were associated with a higher risk of invasive fungal disease.⁴ The histopathologist has a key role in early diagnosis for invasive fungal infection of mucormycosis. The microbiological culture, radioimaging studies MRI/CT are supportive modalities.

Materials and Methods

This is a prospective, analytical, observational type of study conducted at the Department of Pathology at a Tertiary Care Centre in India. This study is performed with an aim to evaluate clinico

histomorphological features in CAM. The study includes 13 cases of mucormycosis diagnosed over a period of 8 months from January 2021 to 2021. The demographic, clinical details, laboratory investigations, RT-PCR report and imaging findings of all cases were noted from medical case records. Resected specimens of suspected cases were received in formalin in the Department of Pathology. Specimens were fixed overnight and grossed subsequently. Slides were stained with Haematoxylin and Eosin, Silver Methanamine and Periodic Acid Schiff (PAS) stains. The characteristics type of inflammation, necrosis, fungal hyphae, presence of granulomatous reaction, angioinvasion and perineural invasion, bony tissue pathology were noted.

Results

A total of 3365 COVID 19 positive cases were reported during the last 8 months. A total of 494 patients with COVID 19 were admitted for >24 hours during this study period. A total of 13 cases of COVID 19 associated with mucormycosis were reported. The COVID-19 positive status of the patients was confirmed by RT-PCR test in all cases.

Table 1: Clinico-histopathological findings of CAM cases.

Case No.	Clinical details	Age sex	Covid 19 status RTPCR	Site and tissue for histopatho	HRCT/MRI	Type 2 DM	History of steroids used	Amphotericin B	Mucor H & E stain	PAS Stain
1	Fever since 10 days cough since 6 days swelling in right eye	31/M	+	Post exenterated eye ball with necrotic tissue	+ /MRI brain suggestive of mucor	+	+	+	+	+
2	Post operative orbital exenteration of soft tissue orbit ophthalmoplegia	58/M	+	Orbital soft tissue	+ / Invasive sinusitis with opacities and bony erosion-	+ Since 10 years uncontrolled	+	+	+	+
3	Fever, Maxilla, face and tooth pain, Dysnea	47/M	+	Right left maxilla, hard palate, tooth	+ /CT/MRI brains invasive sinusitis with opacities and bony erosion	+	+	+	++++	+++
4	Fever, cough and nasal discharge, breathless	52/M	+	Nasal crust left side	+ /Rhino sinus orbital cerebral mucor mycosis	-	-	+	++	+
5	Nasal obstruction facial swelling complete ptosis of left eye with ophthalmoplegia with visual loss	37/M	+	+	+ / Maxillary sinusitis ? fungal invasive sinusitis with opacities and bony erosion	Since 4 years	+	+	++++	+++
6	Fever and cough and nasal discharge debridement nasal crust	40/M	+	nasal It maxilla	+ /CT PNS MRI mucosal thickening, + / leftmaxillary sinusitis -reaching to ipsilateral ethmoid	-	-	-	++	+

7	Fever and nasal discharge Swelling over Left maxilla and sphenoid	50/M	+	bony necrotic left maxilla and sphenoid	+HRCT 11/25 corad patchy ground glass opacity	+ 3Year	-	+	+	+
8	Right maxillary Sinus pain facial pain, breathless	41/M	+	right maxilla	invasive fungal sinusitis		-	-	+	+
9	Fever, Right maxillary teeth pain and right nasal pain	46/M	+	right maxillary teeth right nasal cavity	suggestive of invasive fungal sinusitis		-	+	+	+ with actino mycetes
10	Fever, Mass in right nasal cavity, breathless	46/F	+	right nasal cavity	+ /nasal cavity mucosal thickening -		-	-	-	+
11	Paranasal sinus, eye swelling and ptosis	58/M	+	paranasal sinus	nasal cavity mucosal thickening -	+ 2 Year	-	+	+	+
12	right and left nasal cavity swelling	10/M	+	right and left nasal cavity	known case of mucor mycosis right and left nasal cavity mucosal thickening		-	-	+	+
13	Orbital pain and loss of vision since 10 days, breathless	65/M	+	left sided sinuses and turbinates post septum bony tissue, orbit	+ /left sided sinuses and turbinates post septum bony tissue	Since 20 years	-	+	+	+

The age range of patients was from 10 to 65 years with a median of 46 years. There was male preponderance. The 6 patients of diabetes mellitus were noted. The 3 patients had received steroids during treatment of COVID-19 infection. One patient was having HIV infection. Three patients had history of hypertension. In these patients the presenting clinical features were fever, lethargy, swelling, nasal or sinus congestion, black lesions on nasal bridge or upper inside of mouth (Figure 1). In few cases having nasal discharge nasal obstruction, loose tooth, facial pain, visual impairment, proptosis. The sinusitis was the

commonest presentation in all 13 cases (100%), orbital involvement in 5 cases (37%) and cerebral involvement in 3 cases (23%). The imaging findings on Computed Tomography (CT) and MRI were soft tissue opacification of sinuses with hyperdense material, nodular mucosal thickening, and an absence of fluid levels in the maxillary, ethmoid, frontal, and sphenoid sinuses, (Figure 2, 3). The surgically resected specimens included nasal debridement, sinuses tissue with necrosed bony fragments, crusts, partial maxillectomy and orbital exenteration. The mortality in our study was noted in two patient (15.3%).

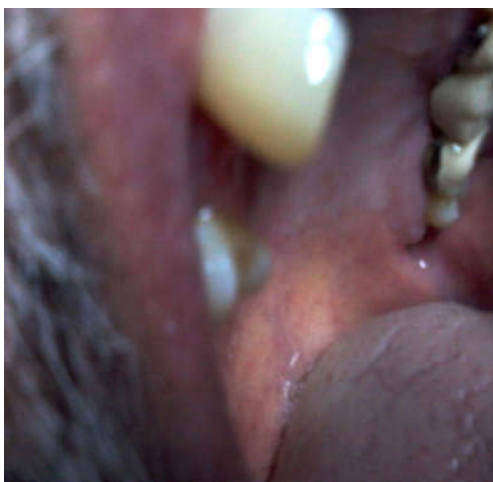

Fig. 1: Clinical Image Oral Mucormycosis Infection.

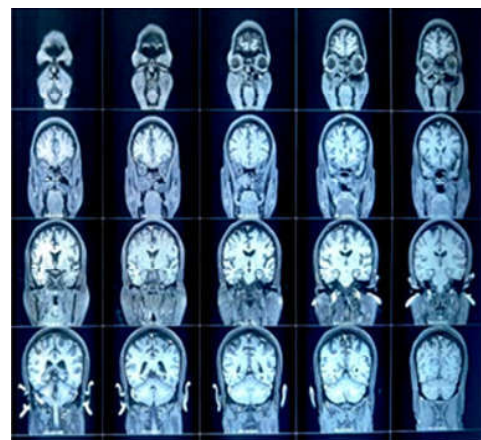


Fig. 2,3: The radio imaging shows soft-tissue opacification of sinuses with hyperdense material, nodular mucosal thickening, and an absence of fluid levels in the maxillary, ethmoid, frontal, and sphenoid sinuses.

On gross examination of infected tissue revealed grey brown or black, firm to hard necrotic tissue with congestion. The histopathology section revealed characteristic broad, aseptate, thin walled hyphae with non parallel sides. Fungal hyphae

having focal bulbous dilatations and occasional irregular branching were noted. The hyphae appeared basophilic in H and E-stained sections and magenta coloured in PAS stained sections (Figure-4, 5).

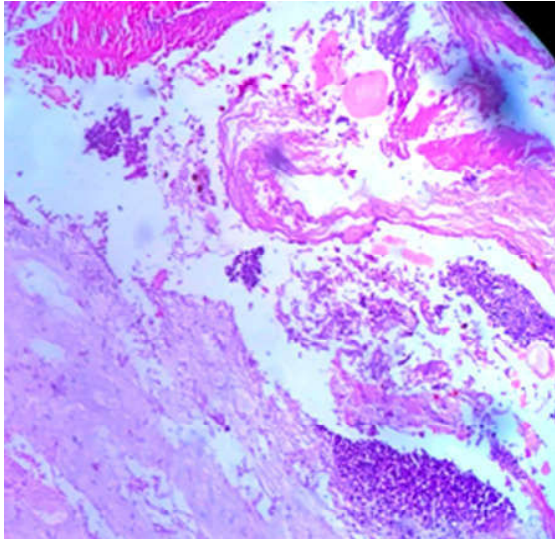


Fig. 4: Chronic inflammation, necrosis in mucormycosis (H & E stain, 40x).

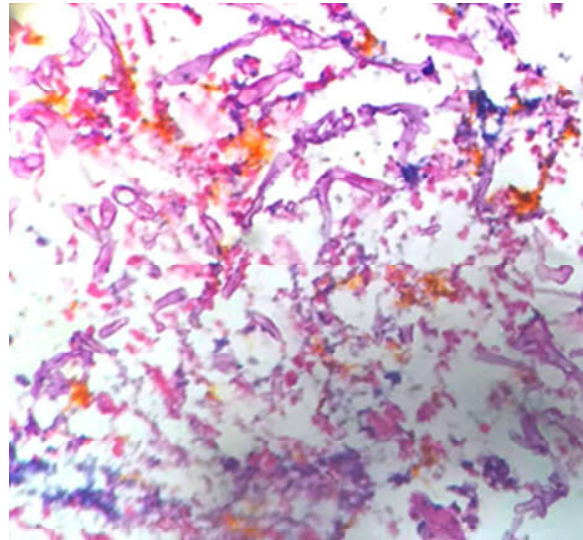


Fig. 5: Figure 4 broad, aseptate, thin-walled hyphae of mucormycosis (PAS stain, 100x)

Acute necrotising, chronic inflammation, bone necrosis (Figure 6,7), granulomas or mixed inflammation were noted.

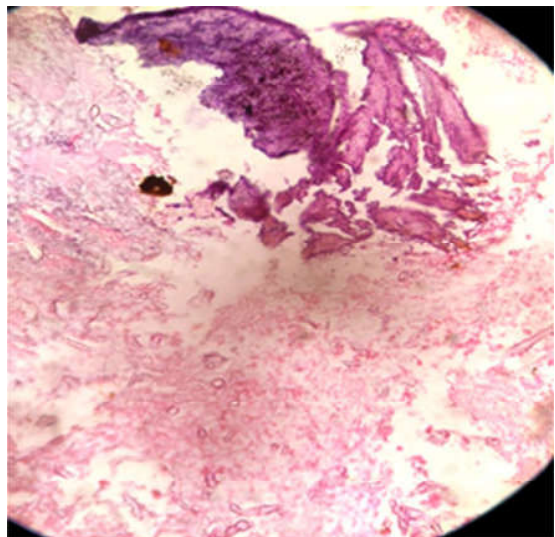


Fig. 6: Severe Inflammation with hyphae of mucormycosis and bony necrosis (H & E stain, 40x)

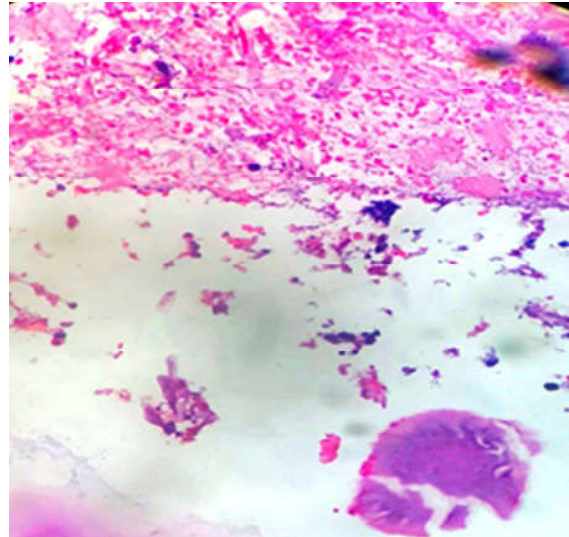


Fig. 7: Acute necrotising inflammation in mucormycosis (H & E stain, 40x)

Necrosis of vessel wall with mycotic thrombi were seen in 6 cases (46%). Foreign body granulomatous reaction were present in 3 cases (23%). Perineural invasion were seen in 2 cases (15 Grocott Gomori's

methenamine silver stain%). Special stains for fungal hyphae: PAS and were positive. KOH mount revealed fungal hyphae in all cases. (Figure 8,9).

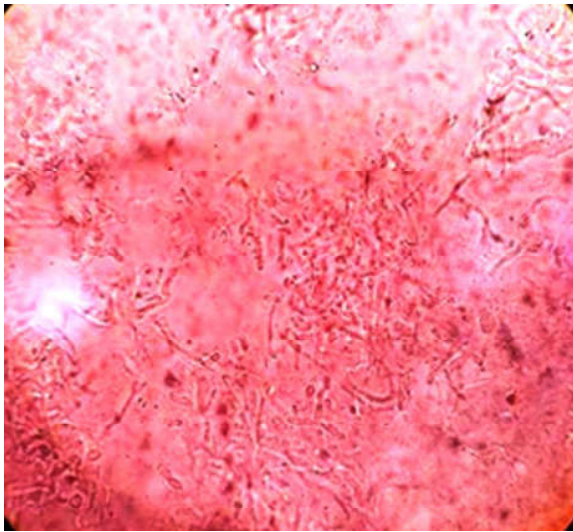


Fig. 8: KOH mount fungal hyphae in mucormycosis.




Fig. 9: Fungal hyphae of mucormycosis-Grocott-Gomori's methenamine silver stain.

Discussion

Mucormycosis/zygomycosis is the term used to name invasive fungal infections caused by saprophytic environmental fungi, belonging to the subphylum Mucoromycotina, order Mucorales.

Mucormycosis is an angioinvasive disease caused by mold fungi of the genus *Rhizopus*, *Mucor*, *Rhizomucor*, *Cunninghamella* and *Absidia*.⁵

The *Rhizopus Oryzae* is most common type and responsible for nearly 60% of mucormycosis cases the the global prevalence of mucormycosis varied from 0.005 to 1.7 per million population, while its prevalence is nearly 80 times higher (0.14 per 1000) in India.⁶

In the present study CAM was noted more common in males. The age range from 10 to 65 years. The 6 cases (46.15%) patients were diabetic. The 3 cases (23.07%) had received corticosteroids (table-1). The clinical sites for presentation were nasal, maxillary sinuses, orbital, and cerebral. Orbital exenteration was done in one case. The necrotic tissue with inflammation and diagnostic fungal hyphae of mucormycosis were seen in all cases. Cases with angioinvasion 46% and granulomatous reaction in 23% cases.

During the current pandemic, COVID-19 associated sepsis has emerged as a significant problem in India.⁷ The potential increase in cases of CAM were reported in the India, it is estimated that there are more than 4,000 people with CAM.⁸

Most CAM cases were diagnosed >8 days after COVID-19 diagnoses. Mucormycosis is a rare but critical problem complicating the later part of the

clinical course of COVID-19.⁹

Elderly diabetic patients in India are significantly associated with severe disease.¹⁰ In addition, COVID-19 is associated with a significant incidence of secondary infections, both bacterial and fungal probably due to immune dysregulation.¹¹ Hypoxemia due to COVID-19 and inappropriate use of glucocorticoid drugs were independently associated with development of late CAM. In a recent review, by Rawson et al, 8% patients had secondary bacterial or fungal infections during hospital admission.¹² A complex interplay of factors, including pre existing diabetes mellitus, previous respiratory pathology, use of immunosuppressive therapy, the risk of hospital-acquired infections, malignancies, organ transplantation, prolonged neutropenia, corticosteroid therapy, iron overload, severe burns, acquired immunodeficiency syndrome (AIDS), intravenous drug abusers, malnutrition and open wound following trauma and systemic immune alterations of COVID-19 infection itself may lead to secondary fungal infections.^{13,14,15} Extensive use of steroids, broad-spectrum antibiotics may lead to the exacerbation of a fungal disease.

In India between September to December 2020, it was found that among 287 patients with mucormycosis, 187 (65.2%) had CAM.¹⁶ India has a high prevalence rate of diabetes mellitus, which is a known risk-factor for infection by *Mucor*.¹⁷ A short course of corticosteroids has recently been reported to link with mucormycosis especially in people with DM.¹⁸ Mucormycosis is a rare but highly invasive opportunistic infection.

Nosocomial mucormycosis has been associated with iatrogenic immunosuppression and a variety of procedures or devices used in hospitals, including antifungal prophylaxis, bandages or medication patches, intravenous catheters and even tongue depressors.¹⁹ The occurrence of infection by *Candida* and *Aspergillus* in COVID-19 patients has been described.²⁰

Mucormycosis is caused by zygomycetes of order Mucorales. Species belonging to the family Mucoraceae are isolated more frequently from patients with mucormycosis, (*Rhizopus* spp.) being the most common cause of infection.¹ Based on clinical presentation and the involvement anatomic site, mucormycosis is divided into clinical various categories as rhinocerebral, pulmonary, cutaneous, gastrointestinal, disseminated, and miscellaneous. Rhino orbito cerebral mucormycosis typically develops in patients with diabetes, whereas such patients very rarely develop lung infection.²¹ Mucormycosis is life-threatening and has high mortality rate. Of the various categories rhinocerebral mucormycosis is the commonest form. Rhinocerebral mucormycosis, is a rare disease caused by filamentous fungi involving the nose, paranasal sinuses, and brain. In the present study maxillary sinus was the commonest site of infection. Mucormycosis of nose and paranasal sinus maxillary sinusitis was common site noted in a study by Saldanha M et al.²²

After inhalation into the nasal cavity and paranasal sinuses, the fungi infect the host by causing necrotizing vasculitis of the nose and sinuses, and rapidly extend into the orbits, deep face, meninges, and cranial cavity. Mucormycosis is characterized by infarction and necrosis of the host's tissues.

The patients who are immunosuppressed, neutropenic or having dysfunctional phagocytes are at increased risk of developing mucormycosis. In patients with hyperglycemia, low pH in diabetic ketoacidosis, have elevated levels of free iron in their serum; this unbound iron is an essential element for cell growth and development of Mucorales. Also phagocytes are dysfunctional and have impaired chemotaxis and defective intracellular killing, predisposing these patients to mucormycosis. COVID-19 often causes endothelialitis, endothelial damage, thrombosis, lymphopenia, and reduction in CD4+ and CD8+ T-cell level and thus predisposes to secondary or opportunistic fungal infection.²³

The spectrum of thrombotic microangiopathies owing to COVID-19 pathogenesis contributes to aggressiveness of the disease. COVID-19 display

evidence of endothelial damage, complement activation, which leads to a pro-coagulable state.²⁴ The thrombotic microangiopathy as being a contributing factor in the thrombotic and multi-organ complications in COVID-19.²⁵ In our study, angioinvasion was identified in 6 cases (46%). A study by Sravani et al, angioinvasion was present in 25 out of 30 cases (83%).²⁶ Clinical spectrum ranges from noninvasive sinusitis in immunocompetent patients. In its invasive form, fungal infection typically spreads by osseous erosion or vascular invasion, with perineural extension being an unusual mode of spread.²⁷ In the present study, perineural spread was identified in 2 cases (15%). In study by Sravani et al, peripheral nerves were identified in 19 biopsies only and perineural spread was identified in 15 biopsies out of 30 (50%).²⁶

A high index of clinical suspicion is required for diagnosis of rhinocerebral mucormycosis. Imaging techniques may be suggestive of mucormycosis. The imaging findings of rhinocerebral mucormycosis on computed tomography (CT) and MRI are diagnostic. These include soft tissue opacification of sinuses with hyperdense material, nodular mucosal thickening, and an absence of fluid levels in the maxillary, ethmoid, frontal, and sphenoid sinuses, in decreasing order of incidence.²⁸

The microbial culture from a potentially infected site is rarely sufficient to establish the diagnosis of mucormycosis.

The hallmark of mucormycosis is eosinophilic necrosis of tissue along with fungal hyphae, giant cells, and thrombosis of vessels. Therefore, the gold standard for diagnosis of mucormycosis is histopathology of infected tissues. The gross examination of resected specimen reveals infected tissue which is congested, oedematous, blackish and necrotic. On histopathology, it is important to identify fungal hyphae and to distinguish mucormycosis from other fungi such as *Aspergillus*. The hyphae of mucorales are broader, infrequently septate, have non parallel sides and exhibit irregular non dichotomous branching. In contrast, aspergilli have narrower and septate hyphae with parallel walls and dichotomous acute angled branching.

The rare cases of COVID-19 associated with coinfection of mucormycosis and actinomycosis has been noted.²⁹

Mucormycosis is difficult to treat. Prompt and aggressive surgical debridement and therapy with an amphotericin B formulation are necessary for successful treatment. A multidisciplinary team approach may sometimes require, both intravenous antifungal therapy and surgical excision.

Liposomal amphotericin B is the drug of choice and needs to be initiated early. Other antifungals like posaconazole, or isavuconazole have also been used to treat. The overall prognosis depends on various factors like early diagnosis, prompt treatment, the site of infection, invasion, necrosis, the patient's underlying conditions, better glycemic control in those with diabetes, degree of immunosuppression and associated co infections. Diagnosis is often delayed, and disease tends to progress rapidly. The mortality in our study was noted in two patient (15.3%) which is less as compared to others. The fatality rate is estimated at 40-80% in various studies.³⁰ This study shows that the early recognition, diagnosis and prompt administration of appropriate antifungal treatment and surgical debridement are important for improving outcomes for patients with mucormycosis.

Conclusion

We are presenting these cases of CAM for its clinical, radio imaging, and histopathological findings. The awareness of the possibility of invasive secondary fungal infections in patients with COVID-19 infection especially in patients with preexisting risk factors and should enable early diagnosis and treatment. The histopathological study plays a significant role in early diagnosis and management of these cases are necessary to improve outcomes.

References

1. Coronaviridae Study Group of the International Committee on Taxonomy of Viruses. The species Severe acute respiratory syndrome-related coronavirus: classifying 2019-nCoV and naming it SARS-CoV-2. *Nat Microbiol.* 2020;5, 536–544.
2. World Health Organization. Novel coronavirus China. 2020 (<https://www.who.int/csr/don/12-january-2020-novel-coronavirus-china/en/in>). Emergency Situational Updates. Weekly epidemiological update on COVID-19 - 27 July 2021. Edition 50, 27 July 2021.
3. Kubin CJ, McConville TH, Dietz D, et al. Characterization of Bacterial and Fungal Infections in Hospitalized Patients With Coronavirus Disease 2019 and Factors Associated With Health Care-Associated Infections. *Open Forum Infect Dis.* 2021;8(6):of201.
4. Woon H. Chong, Biplab K. Saha, Ananthkrishnan Ramani, Amit Chopra. State-of-the-art review of secondary pulmonary infections in patients with COVID-19 pneumonia. *Infection* 49:4, 591-605.
5. Eucker J., Sezer O., Graf B., Possinger K. Mucormycoses. *Mycoses.* 2001;44(7):253-260

6. Skiada A, Pavleas I, Drogari-Apiranthitou M. Epidemiology and Diagnosis of Mucormycosis: An Update. *J Fungi (Basel).* 2020;6(4):265.
7. Adhikari S.P., Meng S., Wu Y.J., Mao Y.P et al. Epidemiology, causes, clinical manifestation and diagnosis, prevention and control of coronavirus disease (COVID-19) during the early outbreak period: a scoping review. *Infect. Dis. Poverty.* 2020;17(9):29.
8. Global Action Fund for Fungal Infections (GAFFI). Doctors around the world call for rapid response to deadly mucormycosis (the so-called "black fungus") found in COVID patients in India. Available at <https://bit.ly/352wj9F>
9. Garg D, Muthu V, Sehgal IS, Ramachandran R, Kaur H, Bhalla A, Puri GD, Chakrabarti A, Agarwal R. Coronavirus Disease (Covid-19) Associated Mucormycosis (CAM): Case Report and Systematic Review of Literature. *Mycopathologia.* 2021;186(2):289-298.
10. Shiv LalSoni, Kamal Kajal, L. N. Yaddanapudi, Pankaj Malhotra, GoverdhanDuttPuri, Ashish Bhalla, et al. Demographic and clinical profile of patients with COVID-19 at a tertiary care hospital in north India. *Indian J Med Res* 2021;153:115-125.
11. Mehta S, Pandey A. Rhino-Orbital Mucormycosis Associated With COVID-19. *Cureus* 2020;12(9).
12. Rawson TM, Moore LSP, Zhu N, et al.: Bacterial and fungal co-infection in individuals with coronavirus: a rapid review to support COVID-19 antimicrobial prescribing. *Clin Infect Dis.* 2020;3;71(9):2459-68.
13. Y.P. Talmi, A. Goldschmied, Reouven, M. Bakon, I. Barshack, M. Wolf, Z. Horowitz, et al. Rhino-orbital and rhino-orbito-cerebral mucormycosis. *Otolaryngol. Head Neck Surg.*, 2002;127,1 : 22-31.
14. Jagtap S V, Jagtap S S, Nagar V , Varshney K , Invasive mucormycosis in post COVID-19 infection: Case report with review. *IP Arch Cytol Histopathol Res* 2021;6(2):135-139.
15. Prakash H., Chakrabarti A. Global epidemiology of mucormycosis. *J Fungi.* 2019;5:26.
16. Patel A, Kaur H, Xess I, Michael JS, Savio J, Rudramurthy S, et al. A multicentre observational study on the epidemiology, risk factors, management and outcomes of mucormycosis in India. *Clin Microbiol Infect.* 2020;26:944.e9–15.
17. International Diabetes Federation . (2020). Accessed: July 7, 2020: <https://idf.org/our-network/regions-members/south-east-asia/members/94-india.html>.
18. Hoang K., Abdo T., Reinersman J.M., Lu R., Higuaita N.I.A. A case of invasive pulmonary mucormycosis resulting from short courses of corticosteroids in a well-controlled diabetic patient. *Med Mycol Case Rep.* 2020;29(1):22–24
19. RajeevSoman, Ayesha Sunavala. Post COVID-19 Mucormycosis – from the Frying Pan into the Fire.

- JAPI Jan 2021;69:46.
20. Chowdhary A, Tarai B, Singh A, Sharma A: Multidrug-resistant *Candida auris* infections in critically ill coronavirus disease patients, India, April-July 2020. *Emerg Infect Dis.* 2020, 26:11. 10.
 21. Roden MM, Zaoutis TE, Buchanan WL, et al. Epidemiology and outcome of zygomycosis: a review of 929 reported cases. *Clin Infect Dis* 2005; 41: 634-53.
 22. Saldanha M, Reddy, R. & Vincent, M.J. Title of the Article: Paranasal Mucormycosis in COVID-19 Patient. *Indian J Otolaryngol Head Neck Surg*, 2021 ;22:1-4.
 23. Singh AK, Singh R, Joshi SR, Misra A. Mucormycosis in COVID-19: A systematic review of cases reported worldwide and in India [published online ahead of print, 2021 May 21]. *Diabetes Metab Syndr.* 2021;15(4):102146.
 24. Wang X, Sahu KK, Cerny J. Coagulopathy, endothelial dysfunction, thrombotic microangiopathy and complement activation: potential role of complement system inhibition in COVID-19. *J Thromb Thrombolysis.* 2021 ;51(3):657-662.
 25. Tiwari NR, Phatak S, Sharma VR, Agarwal SK. COVID-19 and thrombotic microangiopathies. *Thromb Res.* 2021 ;202:191-198.
 26. Sravani T, Uppin SG, Uppin MS, Sundaram C. Rhinocerebralmucormycosis: Pathology revisited with emphasis on perineural spread. *Neurol India.* 2014;62:383-6.
 27. Kandpal H, Aneesh MK, Seith A, Sharma S. Symptomatic perineural extension of fungal sinusitis in an immune competent person: Imaging features. *Singapore Med J.* 2008;49:171-4.
 28. Gamba JL, Woodruff WW, Djang WT, Yeates AE. Craniofacial mucormycosis: Assessment with CT. *Radiology.* 1986;160:207-7.
 29. Jagtap SV, Hulwan A, Vartak S et.al. Co-infection of mucormycosis and actinomycosis in COVID-19 infection. *Int J Health Sci Res.* 2021; 11(8): 127-130.
 30. Cornely OA, Alastruey-Izquierdo A, Arenz D, Chen SCA, Dannaoui E, Hochhegger B, et al. Mucormycosis ECMM MSG Global Guideline Writing Group. Global guideline for the diagnosis and management of mucormycosis: an initiative of the European Confederation of Medical Mycology in cooperation with the Mycoses Study Group Education and Research Consortium. *Lancet Infect Dis.* 2019 ;19(12):e405-e421.

