

Use of Dexmedetomidine as an Adjuvant in Pediatric MRI Procedures

Swarnalatha J¹, Jyotsna S Paranjpe²

¹Junior Resident, ²Professor and Head, Department of Anesthesia, Bharati Vidyapeeth Deemed University Medical College and Hospital, Sangli, Maharashtra 416410, India.

Abstract

Introduction: The success of sedation for MRI has typically been measured by two factors: comfortable immobility during the procedure enabling successful completion of the diagnostic examination and the safety of the sedation procedure. We have tried to assess the role of Dexmedetomidine as an adjuvant in pediatric MRI procedures. **Aims and Objectives:** To assess the effectiveness of intravenous dexmedetomidine as an adjuvant to the combination of Ketamine and Midazolam in pediatric patients undergoing MRI study and to compare incidence and severity of adverse effects found in the groups with and without Dexmedetomidine. **Materials and Methods:** After obtaining ethical committee approval and consent from the parents, 60 children posted for MRI study of duration less than 60 minutes, of age group 6 months to 5 years were selected for the study purpose and randomly divided into two groups. Children under group A received Inj. Ketamine 2 mg/kg + Inj. Midazolam 0.05 mg/kg. Children under Group B received Inj. Ketamine 0.5 mg/kg + Inj. Midazolam 0.03 mg/kg + Inj. Dexmedetomidine 2 mcg/kg. Monitoring of SpO₂, RR, HR were done with the help of MRI compatible monitors. 3-point score to assess grade of immobility during the procedure was used to assess the quality of sedation. Ramsay sedation score was used to assess duration of post-procedure sedation. Incidences of adverse events were noted. Inj. Propofol 0.5 mg/kg was used as rescue sedative and Inj. Atropine 0.02 mg/kg for treatment of bradycardia if any. All the patients received nasal Oxygen at 2 lt/min. **Observations and Results:** Movement during MRI procedure was noted in one patient from Group B. Postoperative Ramsay sedation scores were significantly higher >3 in 12 patients (40%) from Group A vs in 5 patients (16.7%) from Group B ($p < 0.05$). Intraoperative quality of sedation was better with Group B ($p < 0.05$). 5.5% patients from group A desaturated within 10 min of administration of drugs which recovered spontaneously within 5 min of continuation of supplemental oxygen. **Conclusion:** Addition of Dexmedetomidine (2 mcg/kg) reduces doses of Midazolam and Ketamine hence reducing the incidence of dose related side effects without causing compromise in efficacy. It produces stable hemodynamics, better immobility during the procedure and enables early recovery from anesthesia.

Keywords: Dexmedetomidine; Ketamine; Midazolam; MRI procedure; Pediatric.

How to cite this article:

Swarnalatha J, Jyotsna S Paranjpe. Use of Dexmedetomidine as an Adjuvant in Pediatric MRI Procedures. Indian J Anesth Analg. 2019;6(5 P-II):1840-1846.

Introduction

MRI in children, due to high ambient noise warrants deep sedation for immobilization to complete

the procedure successfully. Due to remoteness of MRI suite, lack of MRI compatible monitors and equipment, anesthesia for MRI becomes challenging. Total intravenous anesthesia (TIVA)

Corresponding Author: Jyotsna S Paranjpe, Professor and Head, Department of Anesthesia, Bharati Vidyapeeth Deemed University Medical College and Hospital, Sangli, Maharashtra 416410, India.

E-mail: san_jyotsna@yahoo.co.in

Received on 18.06.2019, **Accepted on** 16.08.2019



This work is licensed under a Creative Commons Attribution-NonCommercial-ShareAlike 4.0.

continues to be the most widely preferred mode of sedation for children at remote locations like MRI suite.¹ An increasing number of procedures are done under TIVA since the range of drugs that can be safely used has expanded exponentially.

Propofol (2, 6-di-isopropyl phenol) is used for TIVA for short procedures in pediatric patients due to its rapidity of onset and offset.² However, the same property makes it unsuitable for MRI procedures since frequent additional doses are required for completion of MRI procedures which extend more than twenty minutes. Propofol is given in the form of a continuous infusion³ for continued effect for prolonged period, but due to difficulty in obtaining MRI compatible supportive equipment required for an infusion; like IV stands and infusion pumps make its use unsuitable for MRI procedures. Also, Propofol does not possess intrinsic analgesic properties⁴ and causes cardiorespiratory depression that discourages its use in MRI for paediatric patients.

Ketamine, an N- methyl-D-aspartate receptor antagonist anesthetic agent, is a well tried and tested drug that ensures safety and efficacy in remote areas especially for pediatric patients. Its intrinsic bronchodilator action combined with the anti-nociceptive effects at a spinal level preserves protective reflexes while providing profound analgesia. Conversely, its sole use in pediatrics pose the risk of sympathomimetic exacerbation and emergence phenomenon leading to cognitive impairment and delirium.⁵

Midazolam, a short-acting benzodiazepine, has excellent sedative effects but the respiratory depressant activity predominates and persist seven in titrated doses in pediatric patients.⁶

Dexmedetomidine, a centrally acting alpha-2 agonist drug, has been proven safe when used in titrated doses and does not differ in pharmacodynamics when used in pediatric population. It gives excellent sedation without respiratory depression⁷ and has been proven effective even in high-risk cases.

Using a combination of drugs that have complementary action when used together produces excellent sedoanalgesia. Moreover, Ketamine and Dexmedetomidine by virtue of their counter balancing properties may produce stable hemodynamics while circumventing the complications of the said drugs.⁶

In present study, we have tried to evaluate and compare efficacy and safety of the combination of sedative doses of Ketamine (2 mg/kg) and

Midazolam (0.5 mg/kg) versus the same drugs in reduced doses; Ketamine 0.5 mg/kg and Midazolam 0.03 mg/kg along with Dexmedetomidine at the dose of 2 mcg/kg⁷ for MRI procedures in pediatric patients.

Materials and Methods

After Institutional Ethics Committee approval and written parental consent, ASA physical status I-II children aged between 6 months to 5 years of both sexes undergoing MRI were included in this study. They were randomly divided into 2 groups by lottery method.

Group A received Inj. Ketamine at 2 mg/kg and Inj. Midazolam 0.05 mg/kg and 10 cc of distilled water in another prefilled syringe.

Group B received Inj. Ketamine 0.5 mg/kg plus Inj. Midazolam 0.03 mg/kg and 10 cc of Inj. Dexmedetomidine 2 mcg/kg diluted with distilled water in a prefilled syringe.

Patients with CNS/Extremity trauma with convulsions or with airway abnormalities, intubated and ventilator dependent patients, patients on sedatives or refusal of the parent for their child to be a subject were excluded from the study. Patients with known allergies to the study drugs or patients having received any study drug in the last 30 days were also excluded.

All subjects were kept nil per oral for solids and milk for 4 hours and clear fluids for 2 hours.

The prefilled study drugs were administered intravenously slowly over 10 minutes following which the MRI procedure was commenced. A blinded observer recorded baseline values and subsequent readings of Heart rate, SpO₂, RR, 3 point sedation scale every 5 minutes till the end of procedure. Post procedure for 30 minutes, the comfort of the patient, complications if any and wakefulness were assessed by Ramsay sedation score.

Statistical Analysis

Sample size was calculated based on in-patient admissions in the department of pediatrics in Bharati hospital spanning over six months. Taking the population (N) as 70 and margin of error as 5% with Z score 1.96 for a 95% confidence level, sample size was calculated using the following formula

$$\text{Sample size} = \frac{z^2 \times p(1-p)}{e^2} \div \left[1 + \left(\frac{z^2 \times p(1-p)}{e^2 N} \right) \right] \text{ and was found to be } 56.$$

So sixty subjects were randomly chosen and divided into two groups by lottery method.

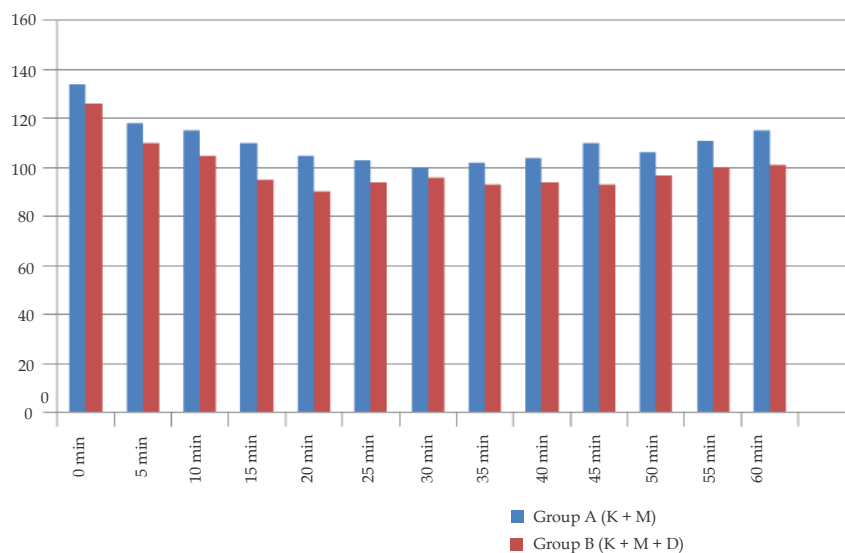
The data was entered in Microsoft Excel spreadsheet and analyzed using SPSS 22 version software. Categorical data was represented in the form of frequencies and proportions. Chi-square test was used to analyze qualitative data represented as mean and standard deviation. Paired-*t* test was the test of significance used for paired data. '*p*' value of <0.05 was considered statistically significant.

Results

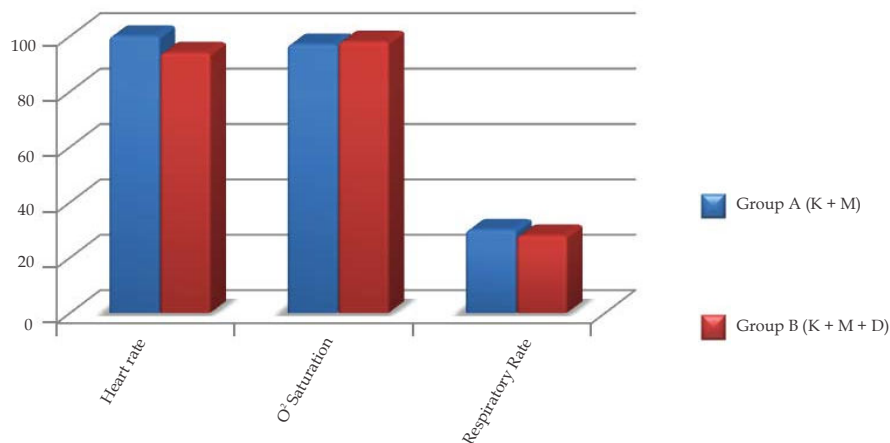
Demographic data was comparable with respect to Age, Weight, ASA physical status and gender status in both groups (Table 1). Throughout the procedure, the subjects maintained stable hemodynamics in both the groups (Table 2). Variation in heart rate was lesser in Group B when compared to Group A. however, the differences were statistically insignificant (Graph 2).

Table 1: Demographic Data

Demographic data	Group A (n=30)	Group B (n=30)	<i>p</i> value	Significance
Age (years)	2.1 ± 2.9	2.3 ± 2.7	> 0.05	Not significant
Sex (M)	20	19	> 0.05	Not significant
Sex (F)	10	11	> 0.05	Not significant
Weight (kg)	9.2 ± 4	8.9 ± 4.4	> 0.05	Not significant
ASA I	9	8	>0.05	Not significant
ASA II	21	22	>0.05	Not significant



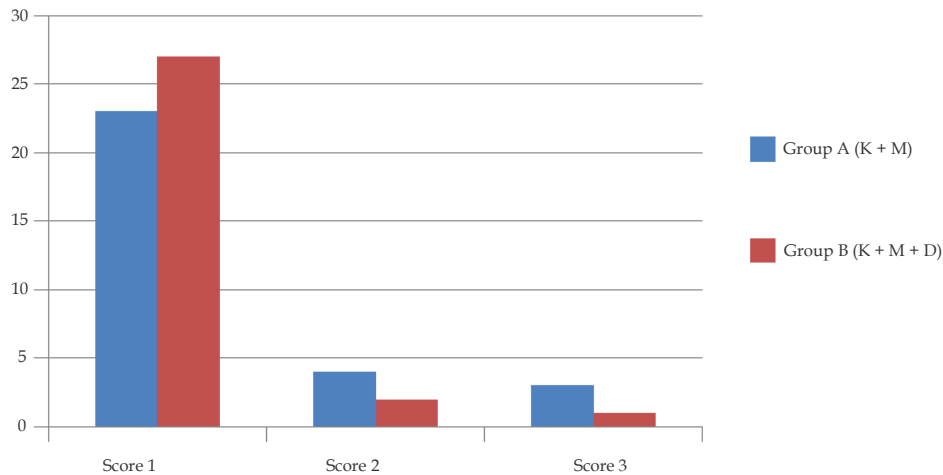
Graph 1: Comparison of variation in intraprocedural heart rates between the two groups



Graph 2: Comparison of Heart rates, Oxygen saturation and Respiratory rates between the groups

Table 2: Comparison of Hemodynamic Parameters

Parameter	Group A (n=30)	Group B (n=30)	p value	Significance
Heart rate	100 ± 30	94 ± 24	> 0.05	Not significant
SpO ₂	97 ± 2	98 ± 2	> 0.05	Not significant
Respiratory rate	30 ± 4	29 ± 5	> 0.05	Not significant
Use of rescue analgesic	—	—	—	—



Graph 3: Comparison of intra-procedural sedation scores between the groups

Table 3: Comparison of Adverse Effects during the Study Period

Adverse events	Group A (n = 30)	Group B (n = 30)
Tachycardia >20% baseline	1	—
Bradycardia <20% baseline	1	2
Movement during procedure	—	1
Respiratory depression (reduction in SpO ₂ less than 90%)	3	—
Post-procedure Respiratory obstruction	5	—
Post-procedure agitation	1	—

Rescue analgesic was not required in any of the study subjects in both the groups.

Intraprocedural quality of sedation (Graph 3) was assessed by a 3-point sedation score where the scores were credited as follows:

Sedation Score

- 1 - No motion
- 2 - Minor movement
- 3 - Major movement requiring repeat scan

Optimal immobilization (Score 1) was observed in 90% of the subjects in Group B whereas in Group A, 76.67% of the subjects were adequately immobilized. Quality of sedation was found to be significantly better (*p* value < 0.05) in Group B as compared to Group A.

Bradycardia was observed in 2 subjects among the group receiving Dexmedetomidine which was treated with Inj. Atropine at 0.02 mg/kg but the procedure was continued; thereby, the sedation score was unaffected (Table 3).

Respiratory rates were observed to be decreased following bolus doses of the group a combination but stabilized following continuation of oxygen supplementation. Group B subjects showed adequate oxygenation which was assessed clinically by chest movements.

The subjects were observed in the recovery room for a period of thirty minutes post procedure. 16.67% of the subjects in Group A required continued oxygen supplementation in the post-procedure period. Once they regained complete consciousness they maintained on ambient atmosphere. Group B subjects were observed to have adequate oxygen

saturation in the post-procedure period and did not require supplementation.

Postoperative respiratory obstruction was relieved by extending neck in recovery position.

Overall respiratory adverse effects noted were more with group a patient.

Post procedure agitation was observed in 1 subject in group a, which subsided without any intervention within 10 minutes. No such incidence was observed in Group B (Table 4).

Table 4: Comparison of Post-procedural Sedation Scores between the Two Groups

Ramsay sedation scale	Group A (n = 30)	Group B (n = 30)
Postoperative RSS 3 or < 3	18	25
Postoperative RSS > 3	12	5

Ramsay sedation scale

1. Patient is anxious, agitated and restless
2. Patient is oriented, cooperative and tranquil
3. Patient responds to commands only
4. Patient exhibits brisk response to light tactile stimuli or loud auditory stimulus
5. Patient exhibits sluggish response to light tactile stimuli or loud auditory stimulus
6. Patient exhibits no response

Group B subjects showed spontaneous arousability at the end of the procedure with clear headed recovery which was contributory to the parents' (of the study subjects) satisfaction. 83% of the patients in Group B were arousable on light tactile stimulus by the parent whereas in Group A, 60% were spontaneously arousable. Also, the duration of sedation post procedure was significantly longer in group A. The difference was statistically significant ($p < 0.05$).

Both the groups did not show statistically significant deviation in hemodynamic parameters throughout the study period. In terms of hemodynamic stability, both the groups were comparable. Respiratory complications were observed in Group A while Group B had no such incidence. Intra-procedural sedation scores were better in Group B but the difference was statistically insignificant. Post procedure arousability, assessed with the aid of Ramsay sedation score (RSS), was significantly better in the subjects of Group B where 83% of the subjects had an RSS > 3 while compared to group A where only 60% had the same score. Intergroup difference was statistically significant. ($p < 0.05$)

Discussion

The success of sedation for MRI has typically been measured by two factors: the safety of the sedation procedure (lack of adverse events) and the effectiveness of the procedure (successful completion of the diagnostic examination).³ Sedation of children for MRI is usually associated with inadequate or failed sedation because of difficulty in having patients motionless while maintaining hemodynamic and respiratory stability.

Various drugs have been tried from time to time in TIVA. Since no single drug can provide all the characteristics of an ideal intravenous agent, several drugs are used in different combinations to provide balanced anesthesia in TIVA, that is, amnesia, hypnosis and analgesia.⁶

Ahmet Koroglu *et al.*⁷ compared the sedative, hemodynamic, and respiratory effects of Dexmedetomidine and Propofol in children undergoing magnetic resonance imaging examination. Their results suggested that, although Propofol provided faster induction and recovery, it caused hypotension and desaturation owing to its depressant action on upper airway reflexes. They also inferred that Dexmedetomidine was a better sedative than Propofol in pediatric patients.

In another study on same subset of patients for same purpose Haesesler *et al.*⁸ inferred that co-administration of ketamine and midazolam by initial rectal and later supplemental intravenous route proved safer and useful alternative to general anesthesia.

Current guidelines for safe practice of TIVA in remote areas like MRI suite were put forth by Nimmo *et al.*⁹ in 2018. According to their consensus document, continuous infusion of routinely used TIVA drugs like Propofol should be closely monitored to attain steady state plasma concentration with the help of target controlled infusions⁹ (TCI) and continuous hemodynamic monitoring. As per their recommendations, in the circumstances where the above facilities are not available, only sedative doses of these drugs can be given. Ketamine with its intrinsic bronchodilatory activity complements the respiratory depressant activity of Midazolam. Dexmedetomidine, the wonder drug, further lowers the doses while enhancing the quality of sedation when used as an adjunct to the aforementioned drugs.^{10,11}

In our study, we also tried to evaluate safety and efficacy of Dexmedetomidine as an adjuvant. We found that addition of it reduced the doses of

Ketamine and Midazolam without compromising depth of sedation. Our observations confirmed that it also offered the advantage of airway protection and early recovery.

Mason *et al.*¹² reviewed almost 200 studies and reports published regarding the use of dexmedetomidine in infants and children. They observed that the drug had minimal depressant effects on the respiratory system which maintained a patent airway. They also had a useful conclusion that besides providing and augmenting analgesia it diminished shivering as well as agitation postoperatively. In present study, we also did not observe any untoward emergence effects in Dexmedetomidine group.

Dexmedetomidine although not orally active, shows good bioavailability when administered via various other routes like intranasal, buccal, intramuscular and intravenous. Since its side effects are predictable and easily treatable, use of Dexmedetomidine in higher doses (>1.5 mcg/kg), has found place in fast-tracking anesthesia regimens like MRI in children.¹³ So we selected 2 mcg/kg dose.

Ketamine, a general anesthetic agent, works primarily by antagonizing N-methyl-D-aspartate (NMDA) receptors. Electroencephalographic studies show that Ketamine anesthesia is associated with increased gamma and theta activity during administration and emergence.⁵ This increased neuronal activity may prove detrimental in the presence on an underlying cerebral pathology which may trigger increased firing resulting in a seizure episode mid-procedure. Hence in our study, Midazolam with its anticonvulsant property¹⁵ was used to counteract the above-mentioned effect of Ketamine.

Ketamine, with its cardio-stimulatory response on administration, causes a net effect of an increase in systolic blood pressure, heart rate and cardiac output.⁵ In a study conducted by Gupta *et al.*,¹⁰ Ketamine anesthesia administered with Dexmedetomidine at the dose of 1 µg/kg as a premedication in the study group and with Midazolam at the dose of 0.02 mg/kg in the control group. The group where Dexmedetomidine was administered, minimal deviations from baseline hemodynamic parameters were observed whereas in the control group, a significant rise of 27.5% from baseline systolic arterial pressure and a 17–25 beats per minute rise in heart rate were observed.

As per a meta-analysis by Shukry and Miller¹⁴ Dexmedetomidine was used for sedation in

monitored anesthesia care (MAC), airway procedures including fiber-optic bronchoscopy, dental procedures, ophthalmological procedures, head and neck procedures, neurosurgery, and vascular surgery. The literature suggested that Dexmedetomidine loading dose ranged from 0.5 to 5 µg kg⁻¹, and infusion dose ranged from 0.2 to 10 µg kg⁻¹ h⁻¹. Dexmedetomidine was administered in conjunction with local anesthesia and/or other sedatives. Ketamine was administered with Dexmedetomidine and opposed its bradycardia effects.

Considering safety of Dexmedetomidine up to a bolus dose of 5 µg/kg¹⁶, we ventured to use a dose of 2 µg/kg. We also tried to evaluate effect of addition of Dexmedetomidine (2 mcg/kg) in reducing the doses of Ketamine to 0.5 mg/kg and Midazolam to 0.03 mg/kg. Our secondary aim was whether it facilitates early and clear headed recovery immediately after the procedure without requiring additional incremental dose which can cause interruption in the ongoing procedure.

The particular combination of Ketamine and Dexmedetomidine for non-invasive diagnostic procedural sedation was studied by Tobias¹³ in a meta-analysis consisting of four major cohort studies which established the utility of combination of Ketamine and Dexmedetomidine in the doses 1–2 mg/kg and 1 µ/kg respectively for non-invasive procedures.

Results of a valuable meta-analysis by Shukry and Miller¹⁴ Ketamine and Dexmedetomidine suggested that they have counter balancing effects on hemodynamics rendering optimal conditions for pediatric sedation in remote areas.

Limitations

Intra-procedural monitoring of ECG, capnography and blood pressure was not done due to non-availability of MRI compatible monitors. The aforementioned limitations may have influenced the outcomes of the study.

Conclusion

Addition of Dexmedetomidine in dose (2 mcg/kg) not only reduced the dosage of Ketamine and Midazolam with resultant reduction in their side effects but also enhanced the quality of MRI while maintaining stable hemodynamics. Patients in Dexmedetomidine group had early, clear headed recovery when compared to those who did not receive it. Addition of Dexmedetomidine to

Ketamine and Midazolam proved more efficacious and safe in pediatric MRI patients.

Conflict of Interest: None declared

Source of Funding: Nil

References

1. Malviya S, Voepel-Lewis T, Eldervik OP, *et al.* Sedation and general anesthesia in children undergoing MRI and CT: Adverse events and outcomes. *Br J Anaesth.* 2000; 84:743-8.
2. Singh Bajwa SJ, Bajwa SK, Kaur J. Comparison of two drug combinations in total intravenous anesthesia: Propofol-ketamine and propofol-fentanyl. *Saudi J Anaesth.* 2010;4(2):72-9.
3. Dalal PG, Murray D, Cox T, *et al.* Sedation and Anesthesia Protocols Used for Magnetic Resonance Imaging Studies in Infants: Provider and Pharmacologic Considerations. *Anesth Analg* 2006;103:863-8.
4. Andrew G, Usher AG, Kearney RA, *et al.* Propofol total intravenous anesthesia for MRI in children. *Pediatr Anesth.* 2005;15:23-8.
5. Vlisides PE, Bel-Bahar T, Lee U, *et al.* Neurophysiologic correlates of ketamine sedation and anesthesia: a high-density electroencephalography study in healthy volunteers. *Anesthesiology.* 2017;127: 58-69.
6. Schulte-Uentrop L, Goepfert MS. Anesthesia or sedation for MRI in children. *Current opinion in Anesthesiology* 2010;23(4):513-7.
7. Koroglu A, Teksan H, Sagir O, *et al.* A Comparison of the Sedative, Hemodynamic, and Respiratory Effects of Dexmedetomidine and Propofol in Children Undergoing Magnetic Resonance Imaging. *Anesth Analg.* 2006;103:63-7.
8. Haeseler G, Zuzan O, Kohn G, *et al.* Anesthesia with midazolam and S-(+)-ketamine in spontaneously breathing paediatric patients during magnetic resonance imaging. *Paediatr Anaesth.* 2000;10:513-9.
9. Nimmo AF, Absalom AR, Bagshaw O *et al.* Guidelines for the safe practice of total intravenous anaesthesia (TIVA): Joint Guidelines from the Association of Anaesthetists and the Society for Intravenous Anaesthesia. *Anesthesia.* 2019 Feb;74(2):211-24.
10. Gupta K, Gupta A, Gupta PK *et al.* Dexmedetomidine premedication in relevance to ketamine anesthesia: A prospective study. *Anesth Essays Res.* 2011;5(1):87-91.
11. Paranjpe JS. Dexmedetomidine: Expanding role in anesthesia. *Med J DY Patil Univ.* 2013;6(1):5-13.
12. Mason KP, Lubisch NB, Robinson F, *et al.* Intramuscular Dexmedetomidine Sedation for Pediatric MRI and CT. *Am J Roentgenol* 2011;197: 720-5.
13. Tobias JD. Dexmedetomidine and Ketamine: an effective alternative for procedural sedation? *Pediatr Crit Care Med.* 2012;13(4):423-7.
14. Shukry M, Miller JA. Update on dexmedetomidine: use in non-intubated patients requiring sedation for surgical procedures. *Ther Clin Risk Manag.* 2010;6:111-21.
15. Umamaheswara Rao GS. What is New about Neuroanesthesia? *Indian J Anaesth.* 2009;53:395-8.
16. Mason KP, Lerman J. Dexmedetomidine in Children: Current Knowledge and Future Applications. *Anaesth Analg* 2011;113:1129-42.