

Continuous Spinal is Safe in a Patient with Wolff-Parkinson-White syndrome for Hysterectomy

Monisha B¹, Ravi Madhusudhana², Nagaseshu Kumari Vasantha³, Sinchana Bhagavan⁴

Author's Affiliation: ¹Resident, ²Professor & HOD, ³Assistant Professor, ⁴Senior Resident, Department of Anesthesiology, Sri Devaraj Urs Medical College, SDUAHER, Kolar, Karnataka 563101, India.

How to cite this article:

Monisha B, Ravi Madhusudhana, Nagaseshu Kumari Vasantha, et al./Continuous Spinal is Safe in a Patient with Wolff-Parkinson-White Syndrome for Hysterectomy/Indian J Anesth Analg. 2022;9(4):183-186.

Corresponding Author: Ravi Madhusudhana, Professor & HOD, Department of Anesthesiology, Sri Devaraj Urs Medical College, SDUAHER, Kolar, Karnataka 563101, India.

E-mail: ravijaggu@gmail.com

Received on: 19.04.2022, **Accepted on:** 25.05.2022

Abstract

Introduction: Wolff-Parkinson-White syndrome (WPW) is an uncommon cardiac disorder where there is an abnormal band of atrial tissue that connects atria and ventricles. Continuous spinal anesthesia is preferred to avoid multidrug administration and stimulus due to laryngoscopy.

Case Report: A 47 yrs old female, known case of WPW syndrome was posted for hysterectomy. Pre-anesthetic evaluation was done. A 12 lead ECG was done which showed left axis deviation, short PR interval and delta waves. The 2D - Echo showed thickened MV leaflets with grade-1 MR with normal LV systolic function and EF of 60%.

The case was planned to be taken under continuous spinal anesthesia. The Anti-Arrhythmic drugs and Defibrillator were kept ready. Intermittent boluses of Inj. Bupivacaine (H) 0.5% was given through catheter to achieve sensory and motor blockade. Inj. Fentanyl 25mcg was given at the end of the procedure as analgesic dose. Intra operative vitals were stable. Postoperative period was uneventful.

Conclusion: Patient with WPW Syndrome can be managed successfully by continuous spinal anesthesia technique which uses low dose of anesthetic helps in maintaining cardiovascular stability intraoperatively and duration can be extended if surgery is prolonged.

Keywords: Continuous Spinal Anesthesia, WPW Syndrome, Ventricular Tachycardia.

Key Messages: Hemodynamic changes can occur with WPW syndrome with arrhythmias. This can be avoided with definitive treatment like Radiofrequency ablation. Our patient came with WPW Syndrome with stable hemodynamics so continuous spinal anesthesia can offer stable hemodynamics with minimum use of local anesthetics. We are reporting a case of WPW Syndrome with successful anesthetic management.



Introduction

Wolff-Parkinson-White syndrome (WPW) is an uncommon cardiac disorder where there is an abnormal band of atrial tissue that connects atria and ventricles which can electrically bypass the atrioventricular node. The anesthetic management in these patients is challenging because of complications such as paroxysmal supraventricular tachycardia and atrial fibrillation. Continuous spinal anesthesia is preferred compared to general anesthesia to avoid multidrug administration and stimuli due to laryngoscopy. We report successful anesthetic management of Wolff-Parkinson-white syndrome in patient posted for hysterectomy.

Case Report

A 47-year-old female who is a known case of WPW syndrome came with a history of abnormal uterine bleeding for 5 months, was scheduled for vaginal hysterectomy. The patient had breathlessness and sweating 6 years back for which she had taken treatment for one and half years and stopped. Presently, the patient was asymptomatic and with good effort tolerance. There is no history of breathlessness, syncope, dizziness and chest pain on pre-anesthetic evaluation. The patient was newly diagnosed hypertensive and was started on *Tab. Metoprolol* Extended Release 12.5 mg OD and *Tab. Telmisartan* 20mg OD from the past 15 days before surgery. Her blood pressure was 140/90mmhg and her pulse rate was 72bpm. Her physical examination was normal. All laboratory investigations were in the normal range. A 12 lead Electrocardiogram was done which showed a rate of 88/min, left axis deviation, short PR interval (0.08 sec), delta waves (slurred upstroke of QRS), indicative of WPW pattern with an accessory pathway in coronary sinus as per Arruda classification. The 2D - Echocardiography showed thickened MV leaflets with grade-1 MR with normal LV systolic function and an Ejection fraction of 60%.

The patient was explained about spinal anesthesia and consent was taken. *Tab Alprazolam* 0.5mg and *Tab Ranitidine* 150mg was given on the previous night and morning on the day of surgery. Nil per oral maintained. The case was planned to be taken under continuous spinal anesthesia. 18g IV cannula was secured and preloading was done with Ringer lactate. The anti-arrhythmic drugs (*Inj. Amiodarone*, *Inj. Adenosine*, *Inj. Lignocaine*) and defibrillator were kept ready. Electrocardiogram (lead II), Pulse oximeter (SpO₂), and non-invasive blood pressure (NIBP) monitoring were done. L1 - L2 intervertebral space was identified. Under aseptic precautions, Lumbar puncture was done

with 18G Tuohy's needle in L1 - L2 space and after looking for backflow of CSF, the catheter was inserted and fixed at 9cm. *Inj. Bupivacaine*(H) 0.5% was given through catheter after confirming backflow of CSF and sensory and motor blockade was achieved till T8. At hourly intervals 1cc and 0.4cc dosage of drug was given to achieve sensory and motor blockade. Vaginal hysterectomy was converted to total abdominal hysterectomy. *Inj. Fentanyl* 25mcg was given at the end of the surgery as analgesic dose. Surgery lasted for almost 3 hours and intraoperative vitals were stable. Patient was then shifted to recovery room and was under observation for half an hour. Patient was then shifted to post-operative ward. *Inj. Paracetamol* 1g sos was given as analgesia in 1st 24 hours. Postoperative period was uneventful.

Discussion

Wolff-Parkinson-White syndrome is ventricular pre-excitation syndrome which results from an aberrant conduction pathway. The incidence is 0.9-3%. The risk of sudden death in these patients due to malignant arrhythmia is estimated to be around 0.4%/ year. Pre excitation can be due to associated mitral valve prolapse, congenital heart diseases and cardiomyopathies. Diagnosis will be done by history of anxiety, palpitations, angina, anxiety, fatigue and characteristic ECG changes.¹ Common life-threatening arrhythmias can occur that is atrial fibrillation which can lead to Ventricular fibrillation and Ventricular tachycardia or Paroxysmal supraventricular tachycardia.²

In this regional anesthesia is preferred because it prevents use of multiple drugs and sympathetic stimulation will be less. Sympathetic blockade in spinal anesthesia can cause bradycardia and sudden hypotension.²

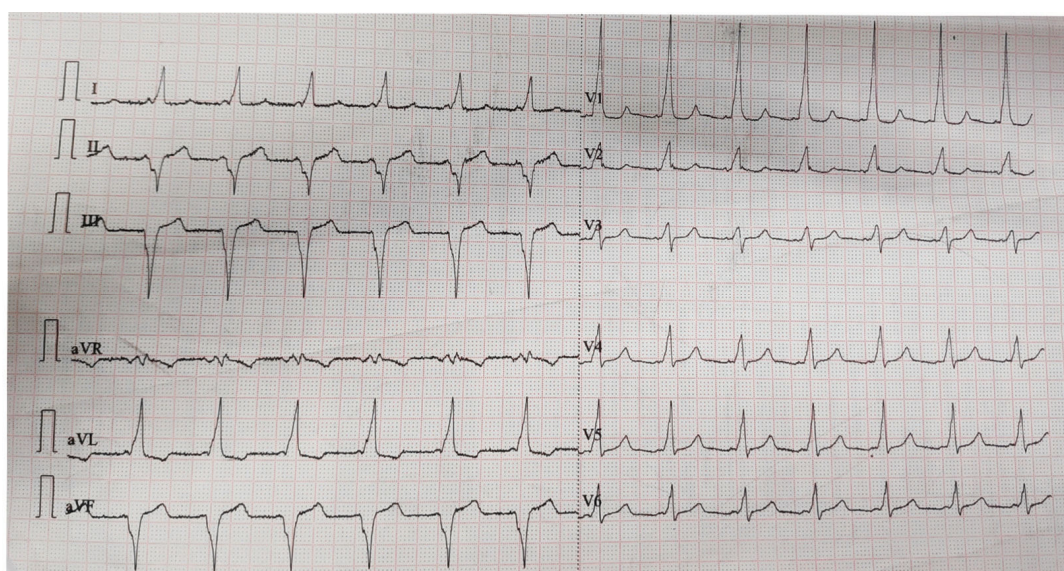
Continuous spinal anesthesia was preferred in this patient because of chances of blockade of cardio accelerator fibers and suppression of AV conduction in a high subarachnoid block. High subarachnoid block can also cause relative excitement of parasympathetic nerves that facilitate conduction through the accessory pathway. Hence, the dosage of the drug given for subarachnoid block should be titrated cautiously to achieve the level required for the surgery.¹ The continuous spinal anesthesia technique (CSA) facilitates slow titration of local anesthetic compared to single-shot spinal. This technique allows maintenance of cardiovascular stability. This CSA technique also provides intraoperative dosing of drug to maintain surgical anesthesia during prolonged surgeries.³

In general anesthesia, it is very important to avoid light planes of anesthesia and drugs that precipitate tachycardia i.e., Glycopyrrolate, Atropine, Ketamine which result in atrial fibrillation or PSVT. Opioids like Fentanyl, Midazolam and Benzodiazepines do not affect extrapyramidal effects of the accessory pathway.⁴ Thiopentone is safe but Propofol can be preferred because it has no effect on refractory period of accessory pathway.⁵

Phenylephrine is effective in treatment of hypotension without causing increase in heart rate, which might be a better choice in patients with WPW syndrome.¹ when Supraventricular Tachycardia occurs with normal QRS complex,

propranolol can be used because it depresses the AV node conduction. Digitalis is contraindicated because it accelerates conduction through accessory pathway.⁵

CSA is associated with many complications such as post dural puncture headache, neurological complications like Cauda Equina syndrome and infection at catheter site. CSA potentially has a higher risk of post-dural puncture headache due to cerebrospinal fluid leakage through the dural puncture and the use of larger bore needle. The development of microcatheters has significantly reduced the incidence of PDPH.



Diagnosis wpw pattern with accessory pathway in coronary sinus (as per arruda classification)

Fig.: Legends

This is a 12 lead ecg with correctly placed leads

With standardization 1mv =10mm with a speed of 25mm/ sec

Rate of 88 /min

Regular rhythm

Axis left axis -70

Pr interval short 0.08 sec

Qrs duration 0.08sec

Qtc 440msec

Delta wave noted

No st t changes

No lvh rvh changes

No bundle blocks

R/s ratio in v1 to v2 >1

Conclusion

Patient with WPW syndrome can be managed successfully by continuous spinal anesthesia technique which helps in maintaining cardiovascular stability intraoperatively and duration of anesthesia can be extended if surgery is prolonged.

Conflict of Interest: Nil

References

1. Devisetti P, Pujari VS. Spinal anesthesia is safe in patient with Wolff-Parkinson-White syndrome undergoing evacuation of molar pregnancy. J Clin Diagn Res. 2016;(10): 1-2.
2. Kabade SD, Sheikh S, Periyadka B. Anesthetic management of a case of Wolff-Parkinson-White Syndrome. Indian J Anaesth. 2011;(10): 381-383.

3. Sultan P, Hilton G, Butwick A, Carvalho B. Continuous spinal anesthesia for caesarean hysterectomy and massive haemorrhage in parturient with placenta increta. *Can J Anaesth.* 2012;(59): 473-477.
4. Sahu S, Karna ST, Karna A, Lata I, Kapoor D. Anesthetic management of Wolff-Parkinson-White Syndrome for hysterectomy. *Indian J Anaesth.* 2011;(55): 378-380.
5. Gupta A, Sharma J, Banarjee N, Sood R. Anesthetic management in a patient with Wolff-Parkinson-White syndrome for laparoscopic cholecystectomy. *Anesth Essays Res.* 2013;(7): 270-272.
6. Parthasarathy S, Annie Sheeba J. Continuous spinal anesthesia: A need for re-emergence? *Asian J Pharm Clin Res.* 2015;(8): 50-53.
7. Beh ZY, Yong PSA, Lye S, Eapen SE, Yoong CS, Woon KL, Lim JGC. Continuous spinal anesthesia: A retrospective analysis of 318 cases. *Indian J Anaesth.* 2018; 62;(10): 765-772.

