

Original Research Article

Clinicopathological Profile of Psoriasis in A Tertiary Care Hospital

Prakashiny S¹, R Revathi Shree²¹Assistant Professor ²Associate Professor, Department of Pathology, Shri Sathya Sai Medical College and Research Institute, Sri Balaji Vidyapeeth (Deemed- To Be University), Ammapettai, Kancheepuram, Tamil Nadu 603108, India.

Corresponding Author:

R Revathi Shree, Associate Professor,
Department of Pathology, Shri Sathya Sai
Medical College and Research Institute, Sri
Balaji Vidyapeeth (Deemed- To Be University),
Ammappettai, Kancheepuram, Tamil Nadu
603108, India.

E-mail: mail2rrevathi@gmail.com

Received on 19.02.2020

Accepted on 20.05.2020

Abstract

Background: Psoriasis is a chronic proliferative and inflammatory disease of genetic etiology. The clinical presentation of psoriasis is varied and often results in incorrect interpretation and misdiagnosis. There is a need for histopathological confirmation for effective case management. This study was carried out to evaluate the clinicopathological presentation of psoriasis. **Methods:** This cross sectional study was carried out among 100 clinically diagnosed psoriasis specimens which were examined for histopathological diagnosis. Hematoxylin and eosin staining was carried out for histopathological evaluation. **Results:** Majority of the participants were aged between 31-50 years and were adults. The most common clinical presentation was silvery scaly plaques which were itchy and pigmented (55%). Most of the patients (95%) had itchy nature of the lesion. Of the 100 cases studied, 86 were diagnosed as psoriasis clinically. Among the 86 cases, 80 were psoriasis vulgaris, 6 were pustular psoriasis. By histological examination of skin biopsies, 96 cases were found to be psoriasis, three cases were psoriasiform dermatitis, one case of psoriasiform hyperplasia. **Conclusion:** Histological confirmation helps in ruling out diagnostic dilemma to psoriasis like alterations in the skin, which often gives a confusion to the clinician.

Keywords: Histopathology; Psoriasis; Plaques; Skin disorder.

How to cite this article:

Prakashiny S, R Revathi Shree. Clinicopathological Profile of Psoriasis in A Tertiary Care Hospital. Indian J Pathol Res Pract. 2020;9(1 Part II):177-181.

Introduction

As one of the largest organs in the body, the functions of skin are multitude, far from being merely an aesthetic structure. The major function of skin is its ability to protect the body from potentially injurious environment. It also helps in regulation of body temperature and synthesizes keratin, lipids, pigments, provitamin D and several enzymes. Skin is also concerned with thermoregulation,

conservation and excretion of fluid, sensory perception and also has the aesthetic role for appearance of the individual. Any disorder of the skin can to a great extent cause derangement in the above-mentioned functions. One such disorder is psoriasis.

Psoriasis is a chronic papillosquamous disorder affecting 1-2% of population in all geographic areas.¹ It is a proliferative and inflammatory disease of the skin resulting in a seven-fold increase



This work is licensed under a Creative Commons
Attribution-NonCommercial-ShareAlike 4.0.

in the epidermal cell proliferation. Clinically they manifest as asymptomatic plaques that are chronic resulting in recurrent exacerbation and remission that are emotionally and physically debilitating and frustrating for the individuals. Although it is widely distributed across all the world, the prevalence among Asians has been recorded to be between 0.29–1.8%.² Psoriasis is predominantly a genetic disorder, although not as a dominant disorder, but with variable penetrance. Recent advances in cell kinetics, immunology and molecular biology had increased our understanding of the etiopathogenesis of keratinocyte proliferation in this disorder. Environmental factors may modify the course and severity of the disease.

There are several morphological variants of psoriasis. These clinical variants mimic diverse dermatological conditions and may require histopathology for confirmation of the diagnosis. Historically, psoriasis was considered to be a primary disorder of keratinisation but more recently the focus has been in the role of immune system.^{1,3} The susceptibility of psoriasis is limited to Class I and II MHC in human chromosome 6. Psoriasis susceptibility 1 (PSORS 1) is considered to be important in the susceptibility loss. Psoriasis is characterized pathologically by hyperproliferation of keratinocytes and inflammation of the epidermis as well as dermis. These changes are due to a T-lymphocyte mediated skin immune response to unidentified antigenic stimuli. Keratinocytes from psoriatic epidermis show rapid migratory and proliferative activities.¹

Although the magnitude of the problem is low, the quality of life of patients suffering from psoriasis is reduced, due to the diversity in its presentation. Considering these facts, there is an imminent need to explore the clinical and pathological profile of presentation of psoriasis in order to identify measures for early diagnosis and prevention.

Objectives

This study was carried out to evaluate the clinicopathological profile of psoriasis in a tertiary care hospital.

Materials and Methods

Study setting and participants

This study was carried out as a cross sectional study

among the patients who were clinically diagnosed as psoriasis in the Department of Dermatology. The study was carried out for a period of two years from September 2012 to August 2014. Skin biopsy specimens of all the clinically diagnosed psoriasis patients who visited our tertiary care hospital during the study period were taken up for the study.

Sample size and sampling

Based on intensive literature review, the prevalence of psoriasis in India ranged from 0.44–2.2%.⁴

Assuming 1% prevalence, at 95% confidence limits and 2% absolute precision, the sample size was calculated as 95.03 and was rounded off to 100. The study participants were selected by convenient sampling.

Ethical approval and informed consent

Approval from the Institutional Ethics Committee was obtained prior to the commencement of the study. Each participant was explained in detail about the study and informed consent was obtained prior to the data collection.

Data collection

A structured interview schedule was used for obtaining clinical and demographic details of the study participants. Histopathological diagnosis of the skin specimens was done in 10% neutral buffered formalin. Hematoxylin and Eosin stained sections were taken up for histopathological examination.

Data analysis

Data was entered and analyzed using Microsoft Spreadsheet 2010. The clinical and pathological profile of psoriasis were expressed in percentages.

Results

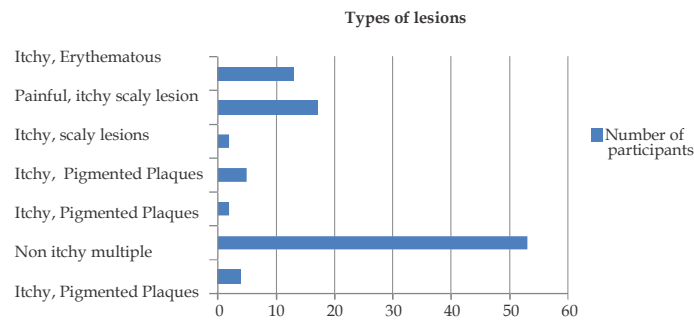
This study was carried out among 100 skin biopsy specimens of the participants clinically diagnosed with psoriasis. Majority of psoriasis patients (32%) were in the age group of 31 to 50 years. The incidence of psoriasis was found to be less (14%) in pediatric age group when compared with adult age group. Overall, majority of the participants were males and were diagnosed with the disease for less than five years (92%) (Table 1).

Table 1: Background characteristics of the study participants:

S. No	Characteristics	Frequency (N = 96)	Percentage (%)
1.	Age (in years)		
	≤14	14	14.58
	15-30	24	25
	31-50	30	31.25
2.	Sex		
	Male	56	58.3
	Female	40	41.7
3.	Duration of the Disease		
	< 5 years	88	91.7
	≥5 years	8	8.3

The most common clinical presentation was silvery scaly plaques which were itchy and pigmented (55%). In two cases, nail pitting was observed. Pustular lesions (both itchy and non-itchy) accounted for 7.2%. Most of the patients

(95%) had itchy nature of the lesion (Fig. 1). Of the 100 cases studied, 86 were diagnosed as psoriasis clinically. Among the 86 cases, 80 were psoriasis vulgaris, 6 were pustular psoriasis (Table 2).

**Fig. 1:** Clinical categories of the lesions.**Table 2:** Clinical diagnosis of psoriasis.

S. No	Characteristics	Frequency	Percentage (%)
1.	Type of lesion (N = 96)		
	Itchy	91	94.8
	Non Itchy	5	5.2
2.	Clinical Types (N = 100)		
	Psoriasis Vulgaris	80	80.0
	Pustular Psoriasis	6	6.0
	Others	14	14.0

By histological examination of skin biopsies, 96 cases were found to be psoriasis, three cases were psoriasiform dermatitis, one case of psoriasiform hyperplasia. Among the 96 cases of histologically

diagnosed psoriasis, 87 were psoriasis vulgaris, eight were pustular psoriasis and one was early psoriasis (Table 3, Fig. 2).

Table 3: Histopathology diagnosis

S. No	Types of Psoriasis	Frequency (N = 100)	Percentage (%)
1.	Psoriasis Vulgaris	87	87
2.	Pustular Psoriasis	8	8
3.	Early Psoriasis	1	1
4.	Psoriaform Dermatitis	3	3
5.	Psoriaform Hyperplasia	1	1

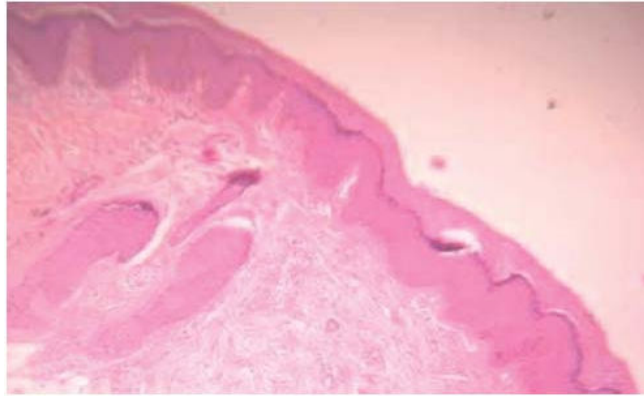


Fig. 2: H&E Stained section of Psoriasis vulgaris in adult showing hyperkeratosis, acanthosis, broad Elongated Rete pegs- low power View (100X).

In this study of 100 cases, 86 cases were clinically diagnosed as psoriasis. Histologically, 96 cases were diagnosed as psoriasis. However, 83 cases correlated clinically and histologically. The overall

sensitivity was 86.46%. Diagnostic accuracy of histopathology in the diagnosis of psoriasis was 84%. (Table 4)

Table 4: Statistical Analysis of Clinicopathological Correlation of Psoriasis

S. No	Clinical Diagnosis	Histopathological Diagnosis		Frequency (N = 100)	Percentage (%)
		Psoriasis	Other than Psoriasis		
1.	Psoriasis	83	3	86	86
2.	Other than Psoriasis	13	1	14	14
Sensitivity 86.4%		Specificity 25%		Diagnostic accuracy 84%	

Discussion

Psoriasis is a genetically mediated, proliferative disorder of the skin of inflammatory pathogenesis. Management of this disorder involves considerable effort as the disease debilitates the individuals physically, psychologically and socially. In addition, the health care costs associated with psoriasis for diagnosis and treatment of remissions make the patient vulnerable for issues associated with coping up strategies and emotional well-being. Although the burden of psoriasis is low in India, the diagnosis of the disease remains a challenge, due to variations in its clinical presentations. Therefore the need for correlating clinical and histopathological diagnosis is necessary for candid assessment of psoriasis.

This study was carried out among 100 cases of clinically diagnosed psoriasis. Majority of the participants were adults and were males. A study done by Dogra S et al. in Chandigarh was also carried out on comparable demographics of the

population.⁴ A comparison of demographic factors in relation to the incidence of psoriasis in published literature showed similar observations in studies done by Karumbaiah et al. and Hesari KK et al.^{5,6}

In our study, itchy pigmented plaques with silvery scales accounted for majority (55%) of cases and erythematous scaly lesion accounted for 14%, pustular variant for 7.2%. Two cases of psoriasis presented with nail pitting. According to Bedi, most common sites of involvement of psoriasis in descending order of frequency were trunk, limbs, scalp, face, palms, soles and flexures.⁷ Kaur et al. reported scalp (25%) as the most common site of involvement followed by legs (20.6%) and arms (11.7%). Oral (0.7%) and genital (0.4%) psoriasis were found to be rare.⁸ Okhandiar et al., found that the extensors are the most common site of involvement followed by scalp (88%). Face, palm, sole and nail were affected in one third of patients. Inverse psoriasis was uncommon.⁹ reported, most common site of lesion involved leg, trunk, back and arm.⁵

Our study correlated the clinical findings with histopathological findings and we observed that histology is absolute gold standard in diagnosing psoriasis. Clinical examination was only a screening tool, although our study demonstrated poor sensitivity and specificity. A study done by Elder D et al. also confirmed with our findings on the validity of histopathology in the diagnosis of psoriasis.³

Conclusion

Histopathology is essential for the diagnosis of psoriasis along with clinical details. The morphological types of psoriasis can be identified by histopathology which is a key to better patient care. Histological confirmation helps in ruling out diagnostic dilemma to psoriasis like alterations in the skin, which often gives a confusion to the clinician.

Conflict of interest: Nil

Funding: Nil

Ethical approval: Obtained

References

1. Camp R.D.R. Chapter 35. Rooks Textbook of Dermatology; 2nd Edition
2. Lee JY, Kang S, Park JS, Jo SJ. Prevalence of psoriasis in Korea: A population based epidemiological study using the Korean National Health Insurance database. *Ann Dermatol* 2017;761-67
3. Levers histopathology of skin Eighth Edition; Lippincot pg:156-61
4. Dogra S, Yadav S. Psoriasis in India: Prevalence and pattern. *Indian Journal of Dermatology, Venereology and Leprology* 2010;76(6):595-601.
5. Karumbaiah K P et al. *Sch. J. App. Med. sci* 2014;2(1c):298-302
6. Kambiz kamyab Hesari, Zahra Safaei Naraghi, Azita Nikoo, et al. Palmopalantar psoriasis versus eczema: major histopathologic clues for diagnosis *Iranian Journal of Pathology* 2014;9(4):251-56.
7. Bedi TR. Clinical profile of psoriasis in North India. *Indian J Dermatol Venereol Leprol* 1995;61:202-5.
8. Kaur I, Handa S, Kumar B. Natural history of psoriasis: a study from the Indian subcontinent. *J Dermatol* 1997;24:230-4.
9. Okhandiar RP, Banerjee BN. Psoriasis in the tropics: An epidemiological survey. *J Indian Med Assoc* 1963;41:550-6

