

Ultrasonography: A Novel and Noninvasive Tool for Airway Assessment

Keniya Varshali M¹, Sancheti Abhay G², Kanoujiya Joti³, Swami Sarita S⁴

¹Associate Professor, ²Assistant Professor, ³Resident, ⁴Professor and Head, Department of Anesthesiology, Bharati Vidyapeeth (Deemed to be University) Medical College, Pune, Pune, Maharashtra 411043, India.

Abstract

Context: Securing the airway to ensure alveolar ventilation and prevent pulmonary aspiration constitutes a crucial component in the practice of clinical anesthesia. Unanticipated difficult intubation still occur despite adoption of various clinical predictors. Ultrasound imaging technique has emerged as new tool for various aspects in anesthesia practice. **Aims:** We have evaluated the feasibility of ultrasonography as an imaging tool in identifying important airway anatomical structures on the anterior aspect of the neck and correlated the ultrasound-guided measurements of the airway parameters with the modified Cormack-Lehane grading of the direct laryngoscopy for prediction of the difficult airway. **Settings and Design:** For this prospective observational study, 100 patients above the age of 18, ASA I to III grades, scheduled for elective surgery, requiring general anesthesia and endotracheal intubation were included. **Methods and Materials:** Modified Mallampati score, Body Mass Index, distance between the anterior commissure to epiglottis (DACE) and distance from epiglottis to midpoint of maximum distance between vocal cords (DEM) using the USG machine followed by MCLS grade on laryngoscopy were noted. **Statistical analysis used:** Software named Statistical package for the social sciences (SPSS version 21.0, IBM Corporation, USA) for MS Windows. **Results:** On data analysis mean of DACE in Easy MCLS group was 0.46 ± 0.19 while in Difficult MCLS group was 0.91 ± 0.23 and the difference was statistically significant. Similarly mean of DEM in Easy MCLS group was 0.66 ± 0.21 while in Difficult MCLS group was 0.59 ± 0.23 . The Mean of Ratio of DACE to DEM in Easy MCLS group was 0.71 ± 0.19 while in Difficult MCLS group was 1.67 ± 0.23 and this difference was also statistically significant. From Receiver operating characteristic (ROC) analyses distribution of area under the curve for DACE/DEM ratio was 0.96 which was significantly higher for prediction of difficult laryngoscopy. **Conclusions:** We as anesthesiologists can use USG as a clinical tool for assessing airway in order to rule out difficult airway and prepare the anesthesia workstation for the benefit of the patient.

Keywords: Difficult airway; Ultrasonography; Distance from the anterior commissure to epiglottis; Distance from epiglottis to midpoint of maximum distance between vocal cords; Laryngoscopy, Modified Cormack-Lehane grading.

How to cite this article:

Keniya Varshali M, Sancheti abhay G, Kanoujiya Joti. Ultrasonography: A Novel and Non-invasive Tool for Airway Assessment. Indian J Anesth Analg. 2019;6(5 P-II):1750-1755.

Introduction

Securing the airway to ensure alveolar ventilation and prevent pulmonary aspiration constitutes a crucial component in the practice of clinical

Anesthesia. Unanticipated difficult intubation still occur despite adoption of various clinical predictors like demographic variables, body mass index, ability to move the lower teeth in front of the upper teeth, interincisor gap, modified Mallampati score,

Corresponding Author: Sancheti Abhay G, Assistant Professor, Department of Anesthesiology, Bharati Vidyapeeth (Deemed to be University) Medical College, Pune, Pune, Maharashtra 411043, India.

E-mail: abhi6264@gmail.com

Received on 15.07.2019, **Accepted on** 08.08.2019



This work is licensed under a Creative Commons Attribution-NonCommercial-ShareAlike 4.0.

thyromental distance, neck flexibility, etc.¹ These bedside physical Airway assessment tools have high inter observer variability, and may be difficult to apply in emergency and critical care settings.

The Cormack-Lehane classification is frequently used to describe the best view of the larynx seen during laryngoscopy. Being too invasive, the major drawback is, it cannot be applied comfortably in awake patient on OPD basis regularly for predicting difficult airway.

Ultrasound imaging technique has recently emerged as a novel, simple, portable, noninvasive tool helpful for airway assessment and management. The ready availability of ultrasound machines along with better probes, high resolution, imaging real-time picture and clinical experience, this has become the potential first line noninvasive airway assessment tool in anesthesia and intensive care practice. Accurate interpretation of ultrasound images requires a basic understanding of the physical principles involved in image generation. Vocal cords are seen forming an isosceles triangle with a central tracheal shadow. During phonation, the vocal cords oscillate and move towards the midline when compared to the false vocal cords which remain relatively immobile.^{2,3}

The purpose of our study is to evaluate the feasibility of sonography as an imaging tool in identifying important airway and anatomic structures on the anterior aspect of the neck and to compare and correlate the ultrasound view of the airway with the Cormack-Lehane classification of the direct laryngoscopy.

Materials and Methods

After institutional ethical committee approval and obtaining the written informed consent for the study, hundred patients undergoing elective surgery under general anesthesia with direct laryngoscopy and endotracheal intubation were enrolled. The study was a prospective observational study conducted in department of anesthesia of a tertiary care center. Patients above the age of 18, without any known airway pathology were included in the study. Those patients with restricted mouth opening, edentulous, cervical spine pathology, high risk of aspiration and patient who are difficult to assess by ultrasonography due to facial and neck abnormality were excluded.

In the preoperative holding area, the Mallampati classification of Pre anesthetic Airway assessment was documented as follows:

Class 1: Full visibility of tonsils uvula and soft palate

Class 2: Visibility of hard palate and soft palate upper portion of tonsil and uvula

Class 3: Soft and hard palate base of the term

Class 4: Only hard palate visible

Subsequently, the ultrasound view of the Airway of study patients was carried out by the same principal investigator with a high frequency linear probe (sonosite, EDGE II). The patient was asked to lie down supine with maximum head tilt chin lift. The probe was then placed transversely in the submandibular area in the midline and was rotated in transverse plane from cranial to caudal without changing the position of the probe till an oblique transverse view that bisects the epiglottis and posterior part of the vocal cord with arytenoids was visualized.

In this plane, the epiglottis is visible as a hypoechoic curvilinear structure. Its anterior border is demarcated by the hyperechoic PES and its posterior border by a bright linear air mucosal interface. The posterior most part of the two vocal folds with arytenoids appears as hyperechoic lateral V-shaped structures facing away from each other (Figure 1). Protrusion of the tongue or swallowing helps to identify the epiglottis. Identification of the vocal folds is facilitated by observing their linear movement during quiet breathing or phonation.

The following study measurements were obtained with the transverse ultrasound view:

- a. The distance between anterior commissure to epiglottis (DACE)
- b. The distance between epiglottis to the midpoint of the cords (DEM)

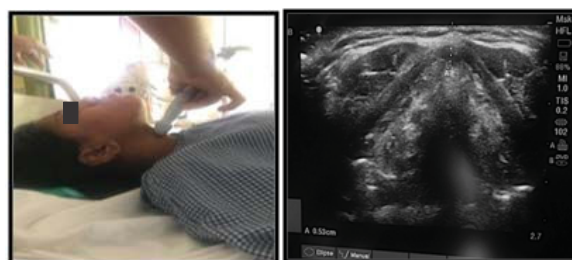


Fig. 1: Probe placement and ultrasound image.

The patients were then taken to the operating room and standard general anesthesia procedure was performed as per the discretion of the attending senior anesthesiologist in accordance with good clinical practice and standard of care. Direct laryngoscopy was performed using a Macintosh blade size number 3 or size 4 as per the built of the

patient. During the intubation the anesthesiologist was asked to note down the Cormack-Lehane grading of the laryngoscopy view. Intubation was classified as easy for Cormack-Lehane grade 1 and 2 or difficult for grade 3 and 4 Cormack-Lehane grading was done as per following scale:

Grade I: Visualization of entire laryngeal aperture

Grade II: IIa: Visualization of parts of the laryngeal aperture or arytenoids

IIb: Only the posterior tip of arytenoids is seen

Grade III: IIIa: Visualization of epiglottis only and it can be lifted

IIIb: Visualization of epiglottis only but cannot be lifted visualization

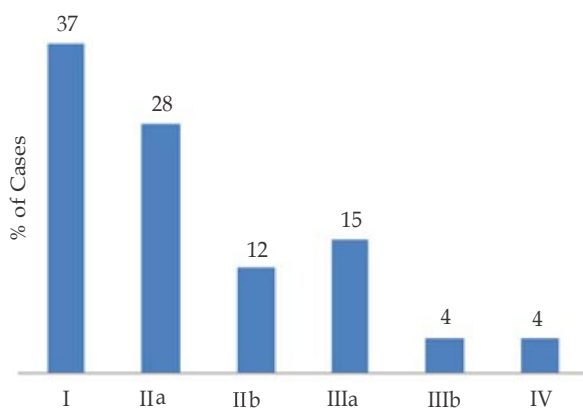
Grade IV: No laryngeal structures are visualized

Appropriate sized endotracheal tube was inserted and anesthesia was maintained. At the end of the surgical procedure anesthesia was reversed and patient extubated.

Results

Hundred patients scheduled for elective surgery and requiring general anesthesia with endotracheal intubation were included in this study.

Of 100 cases studied, 37 (37.0%) had Grade I MCLS, 28 (28.0%) had Grade IIa MCLS, 12 (12.0%) had Grade IIb MCLS, 15 (15.0%) had Grade IIIa MCLS, 4 (4.0%) had Grade IIIb MCLS and 4 (4.0%) had Grade IV MCLS (Graph 1).



Graph 1: Distribution of Cormack-Lehane grades

Depending upon the MCLS, direct laryngoscopy was classified as easy (MCLS Grade I to IIb) or difficult (Grade IIIa to IV) (Table 1).

Table 1: Distribution of Cormack-Lehane

Grades	Status	No. of cases	% of cases
I to IIb	Easy	77	77.0
IIIa to IV	Difficult	23	23.0
Total	-	100	100.0

The distribution of mean age and sex did not differ significantly between groups of cases with easy and difficulty laryngoscopy (p value >0.05) (Table 2)

Table 2: Demographic Data

Parameter	Cormack-Lehane Grades				p -value
	Easy (n=77)		Difficult (n=23)		
	Mean	SD	Mean	SD	
Age (years)	44.06	± 17.97	44.13	± 16.88	0.988 NS
Sex -Male/Female (no)	37/40		11/12		0.985 NS

p -value by independent sample t -test. p -value <0.05 is considered to be statistically significant. NS-Statistically non-significant.

Distribution of means of distance between anterior commissure to epiglottis (DACE), distance from epiglottis to midpoint of cords (DEM) and DACE/DEM ratio according to Cormack-Lehane grades (MCLS).

The distribution of mean DACE is significantly higher in difficult laryngoscopy group compared to mean DACE in easy laryngoscopy group (p -value <0.001).

The distribution of mean DEM did not differ significantly between groups of cases with easy and difficult laryngoscopy (p -value >0.05).

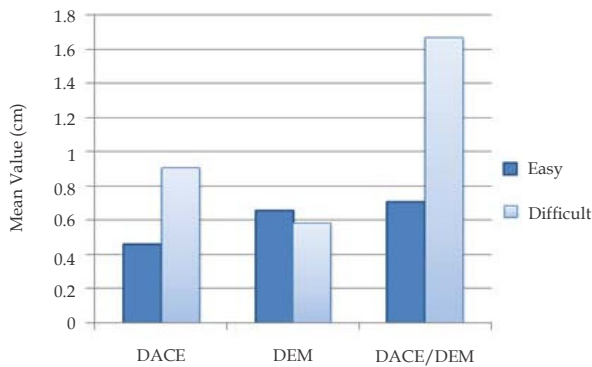
The distribution of mean DACE/DEM ratio is significantly higher in difficult laryngoscopy group compared to mean DACE in easy laryngoscopy group (p -value <0.001). (Table 3) (Graph 2)

Table 3: USG Measurements

Parameters	Cormack-Lehane Grades		p -value	
	Easy (n=77)	Difficult (n=23)		
DACE (cm)	Mean ± SD	0.46 ± 0.19	0.91 ± 0.23	0.001***
	Minimum - Maximum	0.13 - 0.99	0.57 - 1.59	
DEM (cm)	Mean ± SD	0.66 ± 0.21	0.59 ± 0.23	0.218 NS
	Minimum - Maximum	0.30 - 1.15	0.30 - 1.01	
DACE/DEM Ratio	Mean ± SD	0.71 ± 0.19	1.67 ± 0.46	0.001***
	Minimum - Maximum	0.29 - 1.40	1.02 - 2.96	

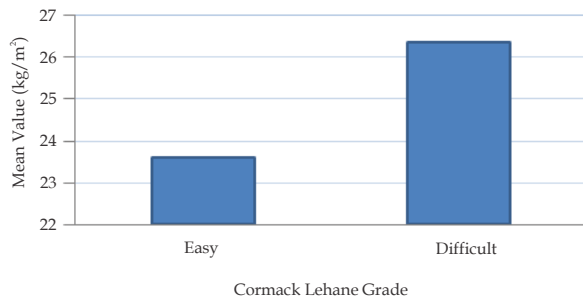
p -values by independent sample t test. p -value <0.05 is considered to be statistically significant.

*** p -value < 0.001 , NS-Statistically non-significant.



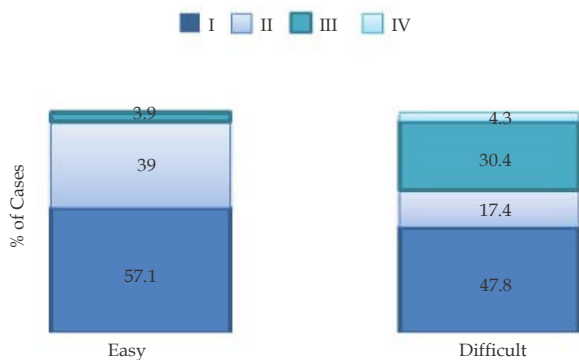
Graph 2: USG measurements

The distribution of mean BMI is significantly higher among the group of cases with difficult laryngoscopy compared to the group of cases with easy laryngoscopy (*p*-value < 0.05) (Graph 3).



Graph 3: Distribution of mean BMI by Cormack Lehane

The distribution of Mallampati grades of cases studied differs significantly between groups of cases with easy and difficult laryngoscopy (*p*-value < 0.001) (Graph 4).



Graph 4: Distribution of Mallampati

The distribution of area under the curve (AUC) is significantly higher for DACE/DEM ratio for the prediction of difficult Laryngoscopy (*p*-value < 0.001).

The distribution of area under the curve (AUC) did not differ significantly for Mallampati Grades for the prediction of difficult laryngoscopy (*p*-value > 0.05).

Based on the ROC analysis, the optimal cut-off of DACE/DEM ratio measurement for the prediction of difficult laryngoscopy is 0.96 with area under the curve being 0.993.

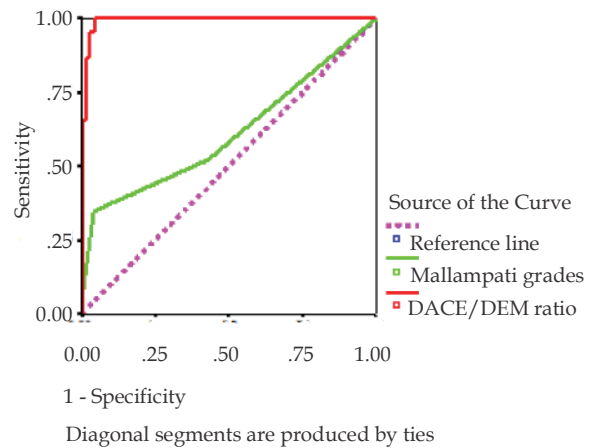
Based on the ROC analysis, the optimal cut-off Mallampati grades for the prediction of difficult laryngoscopy is Grade II and above with area under the curves being 0.612 (Table 4).

Table 4: Distribution of area under the ROC curves (AUC) for DACE/DEM ratio and Mallampati grades for the prediction of difficult laryngoscopy

Parameter	Optimal Cut-Off Based on ROC	AUC ± SE	95% CI of AUC	<i>p</i> -value
DACE/DEM Ratio	0.96	0.993 ± 0.006	0.982 – 0.999	0.001***
Mallampati grades	Grade II	0.612 ± 0.105	0.463 – 0.760	0.105NS

****p*-value < 0.001, NS-Statistically non-significant, Reference value = 0.500; SE - Standard Error.

Receiver operating characteristic (ROC) analyses for DACE/DEM ratio (red line), Mallampati grades (green line). Cormack-Lehane grading of glottis exposure over II was considered the threshold of difficult laryngoscopy during the study. Pink dotted line=reference line. (Graph 5)



Graph 5: ROC curve

Discussion

The major responsibility of anesthesiologist is to provide adequate ventilation to the patient. Recognizing before anesthesia the potential for difficult airway allows time for optimal preparation and proper selection of equipment and technique in difficult airway management. With available noninvasive model airway assessment modality like Mallampati classification, thyromental distance assessment,

neck extension the anesthesiologist usually comes to a conclusion of prediction of airway, as difficult or easy along with other external observations like mouth opening, head and neck pathology, Lemon score. However, as observed, intraoperative laryngoscopy grade, Cormack-Lehane classification may not always correlate adequately well with the preoperative predictors of airway assessment. Also, it is not always viable to do a complete airway assessment in emergency clinical scenarios especially in non-cooperative and unconscious patient. Also, none of them are 100% sensitive and specific.

With latest advancement of ultrasonography, attempts have been made to widen its horizon of utility because of its accuracy and patient friendly noninvasive technique. Airway assessment by ultrasonography can be a good supplementary tool in the busy anesthesiologist armamentarium.

Multiple studies investigating the use of ultrasonography in the evaluation of difficult laryngoscopy by measuring the soft tissue thickness at the level of base floor of the mouth, thyroid bone, epiglottis, thyroid membrane has been undertaken with conflicting results.⁴⁻⁷

The present study was designed to establish a correlation between preoperatively measured USG parameters and the grade of difficulty of visualisation of cords (Cormack Lehane) at direct laryngoscopy.

The parameters assessed by ultrasound in a study were:

A. The distance between anterior commissure to epiglottis (DACE)

B. The distance between epiglottis to the midpoint of the vocal cords (DEM)

Before collecting data for the study group proficiency in assessing the ultrasound imaging for airway assessment was achieved by scanning multiple patients with ultrasonography in pre anesthesia holding area.

Out of 100 cases studied, 77 patients belong to easy laryngoscopy group with CL grade I to IIb where as 23 belong to difficult laryngoscopy group, the patients with CL of grade IIIa-IV. Demographic profile was analyzed for any statistical difference. The age and sex distribution of cases studied did not differ significantly between group of cases with easy and difficult laryngoscopy.

In our study, we observed strong correlation of the mean distance from anterior commissure to epiglottis (DACE) with difficult laryngoscopy

group (p -value 0.001). On the other hand, mean distance between epiglottis to the midpoint of vocal cords (DEM) did not differ much with easy and difficult laryngoscopy.

Also, DACE to DEM ratio was significantly higher in difficult laryngoscopy group compared to easy one. (p value 0.001).

We also compared prediction of difficult Airway with Mallampati grading by plotting distribution of area under the ROC. We observed distribution area under the curve is significantly higher for DACE/DEM ratio for the prediction of difficult laryngoscopy (p value <0.001) with the optimal cut-off value of 0.96 with area under the curve being 0.993. While distribution of area under the curve did not differ significantly for Mallampati grades for prediction of difficult Airway with optimal cut-off for prediction of difficult laryngoscopy is Grade 2 and above with area under the curve being 0.612.

Similar study conducted at Wayne University by Gupta *et al.* attempted to predict CL grading with ultrasound.⁸ They observed positive correlation with pre-epiglottic thickness and negative correlation with epiglottis to vocal cord distance and the ratio of pre- E to E-VC strongest positive correlation with CL grading. They concluded that CL grades could be adequately made by ratios of Pre-E to E-VC distance with 67%-68% sensitivity. Similar findings were found by Preeti Reddy *et al.* where along with the ratio they compared anterior neck soft tissue at the level of hyoid and vocal cords.⁹ They observed prediction of difficult laryngoscopy view using the ratio had a high specificity (86.7%) but very low sensitivity.

The noninvasive prediction of difficult airway can be done by pre-E/EVC ratio (range: 0.29-1.40 corresponds to easy CL grading, 1.02-2.96 corresponding to difficult CL grading. This predictability was similar in the study observed by Rana S *et al.* in their study.¹⁰ They also observed strong positive correlation with AUC of 0.868 with cut-off value 1.77 with sensitivity of 82% and specificity of 80%.

We acknowledge the limitations of our study that the number of the patients was small.

Key Messages: USG guided measurements are better predictors of difficult airway as compared to Mallampati.

Acknowledgement: Nil

Conflict of Interest: Nil

References

1. Crawley SM, Dalton AJ. Predicting difficult airway. *British Journal of Anesthesia*. 2015 Oct;15(5):253-57.
2. Kundra P, Mishra SK, Ramesh A. Ultrasound of the airway. *Indian Journal of Anesthesia*. 2011Sep;55(5):456-62.
3. Garg R, Gupta A. Ultrasound Imaging in Airway Management: A Boon. *Imaging J Clin Med Sciences*. 2014;1(2):014-16.
4. Nazir I, Mehta N. A Comparative Correlation of Pre-anesthetic Airway Assessment Using Ultrasound with Cormack-Lehane Classification of Direct Laryngoscopy. *IOSR Journal of Dental and Medical Sciences*. 2018 Apr;17(4):43-51.
5. Wu J, Dong J, Ding Y, Zheng J. Role of anterior neck soft tissue quantifications by ultrasound in predicting difficult laryngoscopy. *Medical science monitor: International Medical Journal of Experimental and clinical research*. 2014;20:2343-50.
6. Adhikari S, Zeger W, Schmier C, *et al*. Pilot study to determine the utility of point of care ultrasound in the assessment of difficult laryngoscopy. *Academic Emergency Medicine*. 2011 Jul;18(7):754-8.
7. Pinto J, Cordeiro L, Pereira C. Predicting difficult laryngoscopy using ultrasound measurement of distance from skin to epiglottis. *J Crit Care*. 2016 Jun;33:26-31.
8. Gupta S, Sharma R, Jain D. Airway assessment: predictors of the difficult airway. *Indian J Anaesth*. 2005 Jul 1;49(4):257-62.
9. Reddy PB, Punetha P, Chalam KS. Ultrasonography—a viable tool for airway assessment. *Indian journal of Anesthesia*. 2016 Nov;60(11):807.
10. Rana S, Verma V, Bhandari S, *et al*. Point-of-care ultrasound in the airway assessment: A correlation of ultrasonography-guided parameters to the Cormack-Lehane Classification. *Saudi J Anaesth*. 2018;12:292-6.