

Pectoral Nerve Blocks (PECS) for Postoperative Analgesia after Breast Surgeries: A Randomised Clinical Study

Navyashree Krishnashastry Srinivasa¹, Sowmya Madihalli Janardhan Iyengar², Kailash Prakash³, Hiremathada Sahajananda⁴, Maya Dinkar Nadakarni⁵

^{1,3}Post Graduate, ^{2,5}Associate Professor, ⁴Professor, Department of Anesthesia, Rajarajeswari Medical College and Hospital, Kambipura, Mysore Road, Bangalore, Karnataka 560074, India.

Abstract

Context: Pectoral nerve blocks (PECS) is a novel technique introduced to provide analgesia for anterior and lateral chest wall surgeries. **Aims:** The present study was planned to evaluate the efficacy and safety of ultrasound-guided PECS 1 and 2 block for postoperative analgesia after breast surgeries. **Settings and Design:** Prospective, randomized, placebo controlled clinical study. **Methods and Material:** Forty female patients of ASA I/II, undergoing breast surgeries were recruited and randomly allocated into two groups. Group P patients were subjected to ultrasound-guided PECS block with 0.375% Inj. Ropivacaine (10 ml at PECS 1 and 20 ml at PECS 2) and Group C patients were injected with 0.9% saline at PECS I and II sites before reversal from anesthesia. Post operatively VAS scores, time of administration of the first rescue analgesic, number of rescue analgesics, level of blockade were recorded and rescue analgesia with Inj. Fentanyl 1 mcg/kg was given when the VAS score was 4 or more. **Statistical analysis used:** Data collected were tested for normalcy using the Shapiro Wilk test and compared using the Mann Whitney U test, Student T test and Pearson's chi-square test using the SPSS software version 23. *p*-values less than 0.05 was considered statistically significant. **Results:** The VAS scores, total Fentanyl consumption at 24 hours in Group P was less than that of Group C (*p* < 0.05). **Conclusion:** PECS provides effective postoperative analgesia for more than 12 hours from T2 to T5 dermatomal levels with opioid sparing effects after breast surgeries with no adverse effects.

Keywords: Breast surgery; PECS; Postoperative analgesia; Ultrasound.

How to cite this article:

Navyashree Krishnashastry Srinivasa, Sowmya Madihalli Janardhan Iyengar, Kailash Prakash *et al.* Pectoral Nerve Blocks (PECS) for Postoperative Analgesia after Breast Surgeries: A Randomised Clinical Study. Indian J Anesth Analg. 2019;6(5 P-II):1701-1706.

Introduction

Inadequate treatment of postoperative pain after surgeries is known to cause a myriad range of physiologic and psychologic consequences leading to significant morbidity and delay in recovery.¹ The traditional way to overcome postoperative pain in breast surgeries is by providing multimodal

analgesia using non-steroidal anti-inflammatory drugs, paracetamol, opioids and local anesthetic infiltration at the site of surgery. Some anesthetists however prefer using the paravertebral block or thoracic epidural analgesia to tackle postoperative pain.² The appropriateness of these postoperative analgesic techniques become questionable when the breast surgery is performed on a day care basis.³

Corresponding Author: Sowmya Madihalli Janardhan Iyengar, Associate Professor, Department of Anesthesia, Rajarajeswari Medical College and Hospital, Kambipura, Mysore Road, Bangalore, Karnataka 560074, India.

E-mail: drsowmyamj80@gmail.com

Received on 09.07.2019, **Accepted on** 16.08.2019



This work is licensed under a Creative Commons Attribution-NonCommercial-ShareAlike 4.0.

Even relatively minor breast surgery can be associated with significant postoperative pain. A novel inter fascial plane block – PECS was described by R Blanco.⁴ The pectoral nerve block is less invasive and has less complications than the other techniques.² In our study we evaluated the analgesic efficacy of PECS after breast surgeries in comparison with a placebo controlled group. The aim of our study was to compare the pain score, duration of analgesia, total postoperative fentanyl consumption along with the sensory and motor blockade achieved.

Materials and Methods

This prospective, randomized controlled study was conducted after obtaining institutional ethical committee approval and informed consent from all the patients participating in the study. Forty female patients belonging to American Society of Anesthesiologists (ASA) class I and II aged between eighteen and seventy, scheduled for elective breast surgeries were included in the study. Patients with history of hypersensitivity to local anesthetic drugs, bleeding disorders, receiving anti-coagulation therapy, having chest wall deformity, those who were not able to comprehend the Visual Analog Scale (VAS) and pregnant patients were excluded. They were then randomly allocated into either of the two groups using a computer generated table. The groups were PECS Group (Group P) and Control Group (Group C).

Surgery was performed under general anesthesia. All patients were premedicated with Inj. Midazolam 1 mg and Inj. Glycopyrrolate 0.2 mg intravenously. Inj. Fentanyl 2 mcg/kg, Inj. Propofol 2 mg/kg was used for induction. Inj. Vecuronium 0.1 mg/kg was used to facilitate intubation. Patients were intubated with an appropriate sized endotracheal tube and maintained with Isoflurane 1% along with 50% oxygen and nitrous oxide in 1:1 ratio. Inj. Fentanyl 25 mcg and Inj. Vecuronium 1 mg intermittent boluses were given for intraoperative analgesia and maintenance of muscle relaxation respectively. Routine ASA monitoring including non-invasive blood pressure, pulse oximetry, electrocardiography and capnography was carried out.

At the end of surgery, after closure of the skin incision and before wound dressing, the block was performed. With the patient in supine position and arm at 90 degrees abduction, painting of the skin and draping with sterile sheets was performed. The linear ultrasound (US) probe of high frequency

(6–13 MHz, Sonosite, Bothell, WA, USA) after sheathing was placed along the paramedian sagittal plane in the infraclavicular region. The first rib was visualized and the caudal end of the transducer rotated laterally. The transducer in this angle was moved laterally until the second and the third ribs were visualized (Image 1). Once the pectoralis major and minor muscles were identified, color Doppler was used and the pectoral branch of the thoracoacromial artery was localized (Image 2). Skin was infiltrated with 2 ml of Inj Xylocaine 2% and the 23 Gauge needle (Spinal needle, Quincke type point, Becton Dickinson S.A, Madrid, Spain) advanced in plane to the transducer such that its tip just pierces the fascial plane between the pectoralis major and pectoralis minor muscles. Hydrodissection was done to confirm the position of the needle. In patients of Group P, 10 ml of Inj Ropivacaine 0.375% was injected. In patients of Group C, 10 ml of 0.9% saline was injected and PECS I block was completed.

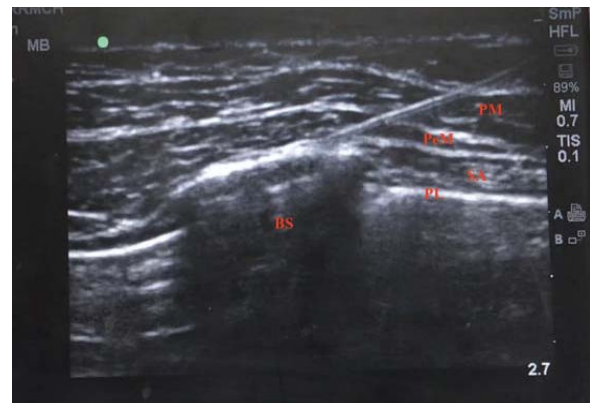

Image 1: Ultrasonographic image showing needle pathway and sonoanatomy. PM = pectoralis major, PeM = pectoralis minor, SA = serratus anterior, PL = parietal pleura, BS = bony shadow.

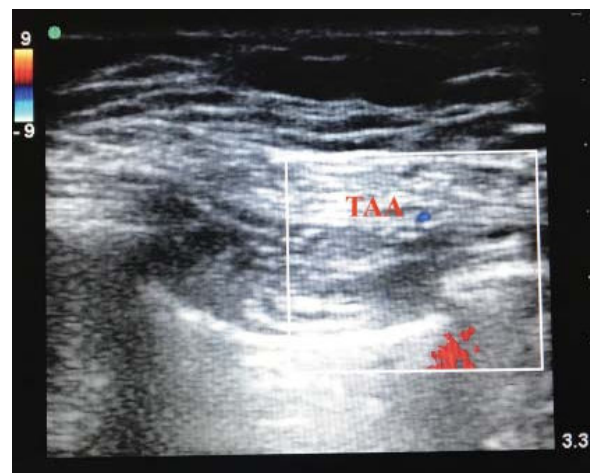


Image 2: Sonoanatomy localising the Thoraco Acromial Artery (TAA).

To perform PECS II, the transducer was moved further laterally until the pectoralis minor and the serratus anterior muscles were visualized over the second, third and fourth ribs. The needle was reinserted to hit the third rib, then it was retracted such that its tip was in the fascial plane separating the pectoralis minor and the serratus muscles. Hydrodissection was performed and position of the needle tip was confirmed. In Group P patients 20 ml of Inj Ropivacaine 0.375% was injected whereas in patients of Group C 20 ml of 0.9% saline was injected. Dressing was applied and the patients were extubated. After recovery from anesthesia, patients were shifted to the postoperative care unit (PACU) and monitored for heart rate, mean blood pressure, pain, sensory and motor blockade at 0, 2, 4, 8, 12 and 24 hours after performing the block. Pain intensity was recorded in the ipsilateral upper limb using the 10 cm VAS. Sensory levels were determined by pinprick and the dermatomal levels that were devoid of pain were recorded. Motor blockade was assessed by evaluating for any weakness of the muscles in the upper limb on the side in which the block was performed. When the VAS score was 4 or more, rescue analgesia with Inj Fentanyl 1 mcg/kg was given. The time to administration of the first rescue analgesic, the total number of rescue analgesics and complications if any (pneumothorax, nausea, vomiting, hypersensitivity reactions, sedation) were recorded. Postoperative nausea and vomiting (PONV) was assessed using a four-point numerical scale (0 = no PONV, 1 = mild nausea, 2 = severe nausea or one episode of vomiting, 3 = vomiting more than once). Sedation if present was graded using the Ramsay sedation score.⁵ The primary outcome measure was the pain score (VAS) in the first 24 hours. Secondary outcome measures were the time to administration of the first rescue analgesic (duration of block), total postoperative fentanyl consumption, the sensory and motor

blockade achieved and complications recorded if any.

Statistics

Based on outcome variables from previous literature for pain assessment at 24 hours, with a mean difference of 0.3 and standard deviation of 0.25, 95% statistical power and 5% level of significance, a sample size of 40 with 20 patients in each group was estimated to be adequate. Statistical analysis was done on a personal computer using the SPSS (Statistical Package for Social Sciences) version 23 software (IBM Corp., Armonk, NY). Normality of numerical data was tested using the Shapiro Wilk test. Normally distributed numerical data were presented as mean and standard deviation. Non normally distributed numerical data were presented as median and interquartile range. The intergroup differences were compared using the Student T test and the Mann Whitney U test for normally and non-normally distributed numerical data respectively. Categorical data were presented as number and percentage and differences between the two groups were compared using the Pearson chi square test. *p*-values less than 0.05 was considered statistically significant.

Results

The groups were comparable with respect to age, weight, duration of surgery and ASA physical status (*p* values > 0.05, as shown in Table 1).

The VAS scores in Group P was less than 4 [median (interquartile ranges)] at 0, 2, 4, 8, 12 and 24 hours and less than the VAS scores of Group C at all time durations (Table 3) which was statistically significant (*p* < 0.05) (Graph 1).

In Group P patients, the analgesia lasted for up

Table 1: Demographic data

Variable	Group P n=20	Group C n=20	<i>p</i> value
Age in years	36.30 +/- 13.41	36.75 +/- 13.75	0.999
Weight in kgs	57.75 +/- 8.71	55.05 +/- 10.45	0.527
Duration of surgery in minutes	57.95 +/- 21.63	64.10 +/- 31.44	0.995
ASA grade I/II	12/8	10/10	0.613

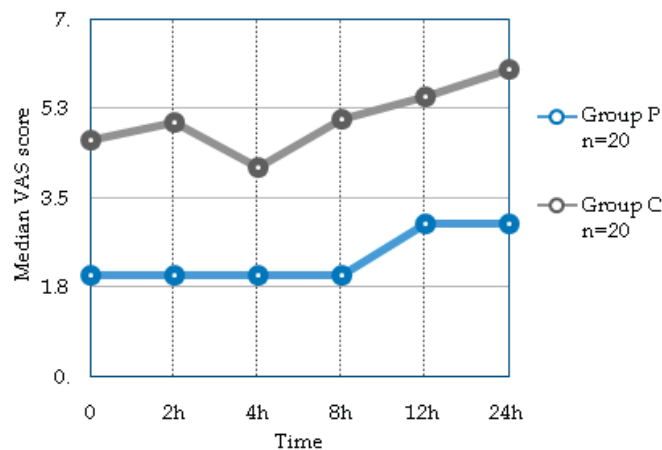
Table 2: Type of surgery

Diagnosis	Group P	Group C
Fibroadenoma	12	10
Fibrocystic disease	2	2
Benign breast tumor	2	3
Ca breast	4	5
Total	20	20

to 12 hours after surgery [median (interquartile range)] whereas, patients in Group C required the first rescue analgesic within 2 hours after completion of surgery (Table 4). The total Fentanyl consumption at 24 hours in Group P was also significantly less when compared to that of Group C

(Table 4, Graph 2).

Sensory analgesia involving the dermatomes T2 to T5, extending from the midline anteriorly up to posterior axillary line laterally was noted on the side where the block was performed in Group P patients. No sensory analgesia was noted in Group



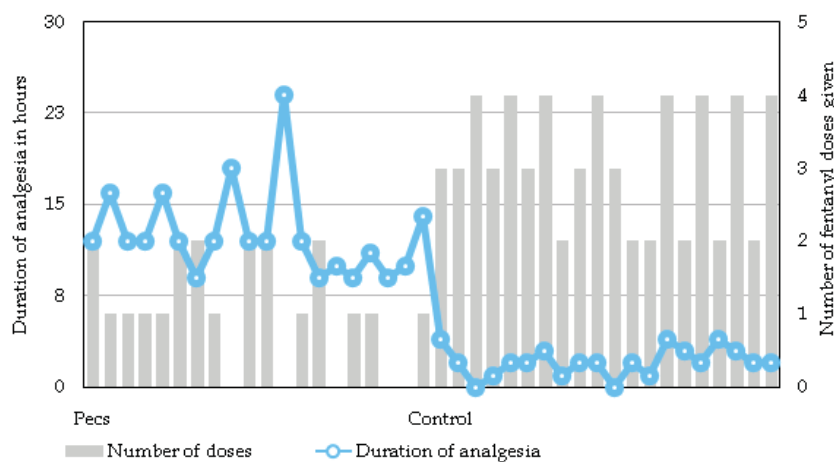
Graph 1: Depicting the difference in VAS score between the two groups.

Table 3: Comparison of VAS, expressed as median and interquartile ranges

VAS scores	0 hour	2 hour	4 hour	8 hour	12 hour	24 hour
Group P n=20	2 (2 - 3)	2 (2 - 3)	2 (2 - 3)	2 (2 - 3)	3 (2 - 3)	3 (3 - 5)
Group C n=20	4.65 (4 - 5)	5 (4 - 6)	4.1 (3 - 5)	5.05 (4.25 - 5.75)	5.5 (5 - 6)	6.05 (5 - 7)
p value	0.000	0.000	0.000	0.000	0.000	0.000

Table 4: Comparing the duration of action (median and interquartile ranges) and the number of fentanyl doses required per patient (mean ± standard deviation)

Variable	Duration of block in hours	Total number of fentanyl dose required per patient in 24 hours (Mean ± SD)
Group P	12 (10 - 13.5)	1.05 ± 0.759
Group C	2 (1.25 - 3)	3.10 ± 0.852
p value	0.004	0.000



Graph 2: Depicting the duration of analgesia achieved and the fentanyl doses given per patient in both the groups.

C. Motor blockade was not observed in either of the groups. No block related complications were noted in either of the groups.

Discussion

The anterior thoracic wall is innervated by the intercostal nerves (T2-T6) which provide segmental somatic innervation to the skin, the medial (C8-T1) and lateral (C5-C7) pectoral nerves which provide innervation to the pectoralis major and minor muscles. The axillary region is supplied by the long thoracic nerve (C5-C7) which supplies the serratus anterior muscle and the thoracodorsal nerve (C6-C8) which supplies latissimus dorsi muscle. PECS I blocks the medial pectoral nerve, the lateral pectoral nerve and the intercostal nerves. PECS II blocks the medial and lateral pectoral nerves, the long thoracic nerve and the thoracodorsal nerve.^{4,6}

The present study was conducted to evaluate the analgesic efficacy of PECS I and II blocks for postoperative analgesia after various breast surgeries. In our study we found that the block was effective and provided adequate postoperative analgesia (VAS scores < 4) and reduced requirement of rescue analgesic agent. The analgesia lasted for up to 12 hours and there was an overall reduction in opioid consumption. Sensory analgesia achieved was adequate (T2-T5) and the patients were comfortable.

Bashandy and Abbas conducted a randomized clinical trial with 2 groups – general anesthesia alone and general anesthesia with PECS for postoperative pain management. PECS group showed significantly lower VAS scores and lower postoperative morphine consumption.⁷ Similarly in another case report by A. Bouzinac *et al.*, patient controlled analgesia with morphine used as the rescue analgesic (dose 1 mg, lockout 7 min). The morphine consumption over the first 24 hours was zero and the pain scores were less than 2 for up to 24 hours postoperatively.⁸

In studies conducted by Eldeen *et al.* and Versyck *et al.*, where Sufentanyl and fentanyl were used respectively as rescue analgesics in the postoperative care unit, similar outcomes of reduced opioid consumption in the PECS group patients was noted.^{9,10}

In several studies conducted on PECS, ropivacaine was the local anesthetic agent used. Depending on the type of surgery 0.5%, 0.375% and 0.2% ropivacaine was used to achieve the block by Kulhari *et al.*, Fujiwara *et al.*, and Bouzinac *et al.*,

in their studies.^{6,8,11} In our study we used 0.375% ropivacaine, 10 ml at the fascial plane between pectoralis major and minor and 20 ml at the plane between pectoralis minor and serratus anterior. In studies conducted by Blanco and Wahba *et al.*, levobupivacaine was used and analgesia for 12 hours was observed.^{3,4} In the study conducted by Eldeen *et al.*, bupivacaine in combination with dexmedetomidine was injected and an increase in the duration of block compared to injection of just the local anesthetic agent alone was observed.⁹

Combipecs - The single injection technique of ultrasound-guided PECS I and II blocks was described by Arunangshu Chakraborty *et al.* They conducted a study on 21 patients where PECS I and II was performed through a single needle pass and postoperative analgesia up to 24 hours was achieved. It was equally effective and less time consuming.¹² The recent approach to increase the duration of analgesia is to place a catheter at the interfascial plane and supplement the analgesic agent as and when needed. Blanco recommends the use of 5 ml/hour infusions of Levobupivacaine 0.25% for up to 7 days if required.⁴ However further studies are required to support this.

Eun-Jin Moon *et al.* reported the use of pectoral nerve block along with sedation for Breast conserving surgery without general anesthesia. In this case report after performing the PECS I and II blocks (using 4 ml of 0.375% and 10 ml of 0.375% ropivacaine respectively) at the start of the surgery when the patient was awake, they confirmed the sensory levels after 15 minutes. Once the patient was comfortable and pain free, Dexmedetomidine continuous intravenous infusion (0.4 microgram/kg/hour) was started to provide sedation and anxiolysis and the surgery was performed. They observed that when PECS was conducted in combination with monitored anesthesia care, it could suffice as primary anesthesia in patients undergoing simple breast surgeries.²

Thoracic epidural analgesia (TEA) is considered the gold standard technique to alleviate pain after breast surgeries.³ It is seconded by thoracic paravertebral blocks and multimodal analgesia which may use a combination of regional anesthetic techniques and intravenous analgesic agents.

Wahba *et al.* in their study compared the analgesic efficacy of thoracic paravertebral block (PVB) with PECS for postoperative analgesia after breast surgeries. They observed that with PVB, ipsilateral dermatomal blockade was seen without contralateral sympathetic chain block (seen commonly with thoracic epidural analgesia). They

also observed that PVB does not block the medial and lateral pectoral nerves, long thoracic nerve and thoracodorsal nerves implying lack of adequate analgesia during breast surgeries involving axillary dissection.³ With PVB 70% of the local anesthetic injected, spread to the epidural space.¹³ Therefore the fact that PVB may transform into epidural block or total spinal anesthesia should be considered. Lönnqvist *et al.* reported various complications associated with PVB like hypotension (4.6%), vascular puncture (3.8%), pleural puncture (1.1%), and pneumothorax (0.5%).¹⁴ These complications make it unsuitable for surgeries being conducted on a day care basis. PECS performed under ultrasound guidance overcomes these complications and is apt for day care surgeries.⁴

Apart from providing analgesia after breast surgeries, studies have shown that PECS I and II also provide analgesia for insertion of cardiac resynchronization devices, analgesia after rib fractures, placement of intercostal drains and analgesia for thoracotomies.^{15,16}

The limitation of this study is that an ultrasound machine with a linear array probe is a must for these blocks and it cannot be performed with blind or landmark techniques. PECS is a simple new alternative for breast surgeries being conducted on a day care basis in which the overall duration of hospital stay is usually less which makes it a feasible and cost-effective mode of postoperative analgesia. The pectoral nerve blocks (PECS 1 and 2) provides effective postoperative analgesia for more than 12 hours from T2 to T5 dermatomal levels with opioid sparing effects after breast surgeries with no adverse effects.

References

- Joshi GP, Ogunnaike BO. Consequences of inadequate postoperative pain relief and chronic persistent postoperative pain. *Anesthesiology Clinics of North America*. 2005 Mar 1;23(1):21-36.
- Moon EJ, Kim SB, Chung JY, *et al.* Pectoral nerve block (Pecs block) with sedation for breast conserving surgery without general anesthesia. *Annals of surgical treatment and research*. 2017 Sep 1;93(3):166-9.
- Wahba SS, Kamal SM. Thoracic paravertebral block versus pectoral nerve block for analgesia after breast surgery. *Egyptian Journal of Anesthesia*. 2014 Apr 1;30(2):129-35.
- Blanco R. The 'pecs block': a novel technique for providing analgesia after breast surgery. *Anesthesia*. 2011 Sep;66(9):847-8.
- Kaplan RF, Cravero JP, Yaster M, *et al.* Sedation for diagnostic and therapeutic procedures outside the operating room. In *A practice of anesthesia for infants and children*. 2009.pp.1023-48. Elsevier Inc.
- Kulhari S, Bharti N, Bala I, *et al.* Efficacy of pectoral nerve block versus thoracic paravertebral block for postoperative analgesia after radical mastectomy: a randomized controlled trial. *BJA: British Journal of Anesthesia*. 2016 Aug 19;117(3):382-6.
- Bashandy GM, Abbas DN. Pectoral nerves I and II blocks in multimodal analgesia for breast cancer surgery: a randomized clinical trial. *Regional anesthesia and pain medicine*. 2015 Jan 1;40(1):68-74.
- Bouzinac A, Brenier G, Dao M, Delbos A. Bilateral association of PECS I block and serratus plane block for postoperative analgesia after double modified radical mastectomy. *Minerva Anesthesiol*. 2015 May 1;81(5):589-90.
- ELdeen HM. Ultrasound-guided pectoral nerve blockade versus thoracic spinal blockade for conservative breast surgery in cancer breast: A randomized controlled trial. *Egyptian Journal of Anesthesia*. 2016 Jan 1;32(1):29-35.
- Versyck B, van Geffen GJ, Van Houwe P. Prospective double blind randomized placebo-controlled clinical trial of the pectoral nerves (PECS) block type II. *Journal of clinical anesthesia*. 2017 Aug 1;40:46-50.
- Murata H, Ichinomiya T and Hara. Pecs block of anesthesia in breast surgery of the elderly. *T.J Anesth*. 2015;29:644.
- Chakraborty A, Khemka R, Datta T, *et al.* Combipecs, the single-injection technique of pectoral nerve blocks 1 and 2: A case series. *Journal of clinical anesthesia*. 2016 Dec 1;35:365-8.
- Purcell-Jones G, Pither CE, Justins DM. Paravertebral somatic nerve block: a clinical, radiographic, and computed tomographic study in chronic pain patients. *Anesthesia and analgesia*. 1989 Jan;68(1):32-9.
- Lönnqvist PA, MacKenzie J, Soni AK, Conacher ID. Paravertebral blockade: failure rate and complications. *Anesthesia*. 1995 Sep;50(9):813-5.
- Fujiwara A, Komasaawa N, Minami T. Pectoral nerves (PECS) and intercostal nerve block for cardiac resynchronization therapy device implantation. *Springerplus*. 2014 Aug 5;3:409.
- Nai AS, Sahoo RK, Ganapathy M, *et al.* Ultrasound-guided blocks for surgeries/procedures involving chest wall (PECS 1, 2 and serratus plane block). *Anesthesia, Pain and Intensive Care*. 2019 Jan 27:348-51.