

Utilizing Amniotic Membrane Allograft as Regenerative Therapy for Treating Burns

Karthikeyan¹, Ravi Kumar Chittoria², Kanav Gupta³, Jacob Antony Chakiath⁴,
Padmalakshmi Bharathi Mohan⁵

How to cite this article:

Karthikeyan, Ravi Kumar Chittoria, Kanav Gupta *et al.* Utilizing Amniotic Membrane Allograft as Regenerative Therapy for Treating Burns Ind. Jr. Med. & Health Sci. 2024;11(1):15-18.

Abstract

Burn injuries are prevalent among all age groups and can result from thermal, scald, or electrical sources. Currently, various scaffolds are employed to enhance the healing process and minimize scar formation. Collagen serves as a scaffold, facilitating tissue regeneration and promoting the formation of new blood vessels. Additionally, scaffolds such as amniotic membrane aid in proper epithelialization and scar reduction, boasting unique anti-inflammatory and bacteriostatic properties. In our study, we utilized amniotic membrane allograft as a biological dressing for burn wounds on a adult patient's gluteal region.

Keywords: Amniotic membrane allograft; Wound healing; Regenerative therapy.

INTRODUCTION

The process of wound healing is a biological response to various forms of injury, encompassing physical, chemical, mechanical, or thermal damage. This process typically involves several sequential phases: homeostasis, inflammation, proliferation/granulation, and remodeling/maturation. However, deviations from the normal healing trajectory often result in stagnation during the inflammatory phase,

particularly evident in cases of burns where standard healing mechanisms may be compromised. In contemporary medicine, the utilization of scaffolds, whether natural or synthetic, has gained traction and recognition. An optimal scaffold should possess specific characteristics: appropriate physical and mechanical properties, a physiological background conducive to cellular adhesion, proliferation, and differentiation, high porosity, a favorable surface area to volume ratio, flexibility to conform to wound shapes, and ideally, biocompatibility and biodegradability. Collagen, whether synthetic or natural, serves as a surrogate for the dermal matrix, facilitating epithelialization during wound healing. Additionally, collagen degradation during this process contributes to neovascularization, thereby promoting angiogenesis. Amniotic membrane, a natural scaffold, exhibits distinctive properties such as anti-inflammatory, bacteriostatic, anti-fibrotic, anti-scarring, and epithelization-promoting qualities. Its low immunogenicity and presence of progenitor cells make it an appealing choice for scaffold applications in wound healing. Silicone functions as a barrier, reducing mechanical

Author Affiliation: ¹Junior Resident, Department of Orthopedic Surgery ²Professor, Head of IT Wing and Telemedicine, ³Senior Resident, ⁴Assistant Professor, Department of Plastic Surgery, JIPMER, Puducherry 605006, India.

Corresponding Author: Ravi Kumar Chittoria, Senior Professor, Head of IT Wing and Telemedicine, Department of Plastic Surgery and Telemedicine, JIPMER, Puducherry 605006, India.

E-mail: drchittoria@yahoo.com

Received on: 08.05.2024

Accepted on: 28.06.2024



friction and transepidermal water loss, factors associated with infection severity. In vitro studies suggest that silicone may modulate inflammatory growth factors implicated in fibrosis and support acute wound healing, including key inflammatory markers like TNF- α , TGF- β , IL-1, and IL-6.

MATERIALS AND METHODS

This research was carried out at a Tertiary Care Centre within the Department of Plastic Surgery following approval from the department's ethical committee. Informed consent was duly obtained. The subject of this study was a seventy-year-old female who sustained accidental second-degree thermal burns affecting the gluteal region. Despite being promptly taken to a nearby hospital, initial resuscitation was inadequate within 30 minutes. She subsequently developed blistering and swelling around the gluteal region the following day and presented to our center with a delay of 12 hours. Upon admission to the tertiary burn care unit, she received initial resuscitation involving intravenous fluids, analgesics, and prophylactic antibiotics. On the fortieth day post-burn, a three-layered scaffold dressing was prepared and applied to the deeper burn areas following dermabrasion-assisted tangential excision. This scaffold comprised sterile amniotic membrane, dry collagen sheet, and silicone sheet, with the amniotic membrane layer directly contacting the wound. The amniotic membrane used was obtained from a freshly delivered placenta, thoroughly washed, and stored in an antibiotic solution in a refrigerator. The dressing remained in place for seven days, during which time the amniotic membrane was completely absorbed, and the silicone sheet layer was also removed. (Fig. 1-3)

RESULTS

Throughout both the intraoperative and postoperative phases, the patient experienced no notable events. Upon opening the dressing on the seventh day post-operation, substantial areas of re-epithelialization and healing were observed. Complete healing of all second-degree superficial burn wounds was achieved without any complications or adverse effects noted throughout the entire procedure. BJWAT wound score improved from 48 at presentation to 32 after utilization of amniotic membrane regenerative therapy. (Fig. 4,5)

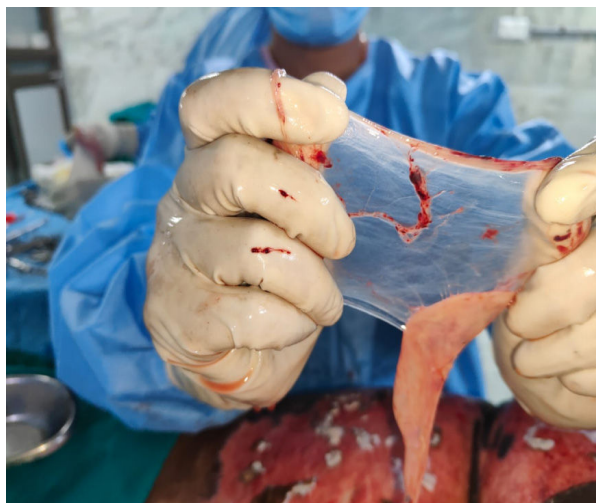

Fig. 1: Amniotic membrane which was harvested from human placenta

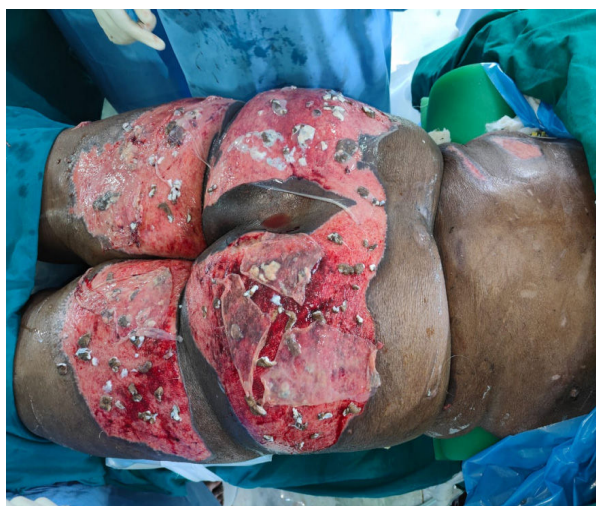

Fig. 2: Amniotic membrane which was harvested from human placenta being applied over the wound over the gluteal region

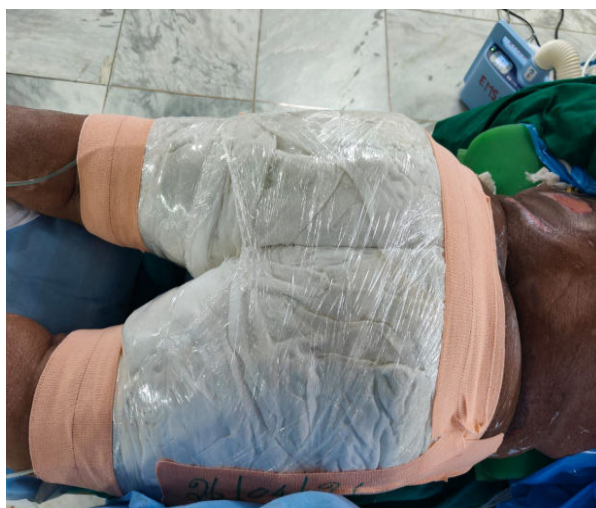

Fig. 3: Application of negative pressure wound therapy to enhance the wound healing and graft uptake

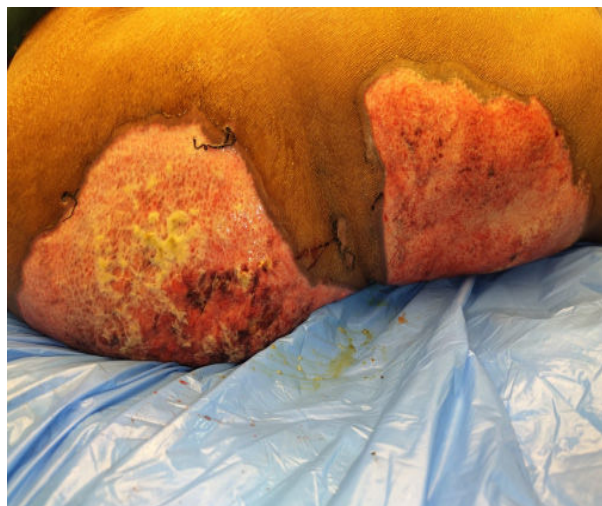


Fig. 4: Condition of the wound at time of presentation (BJWAT wound score - 48)

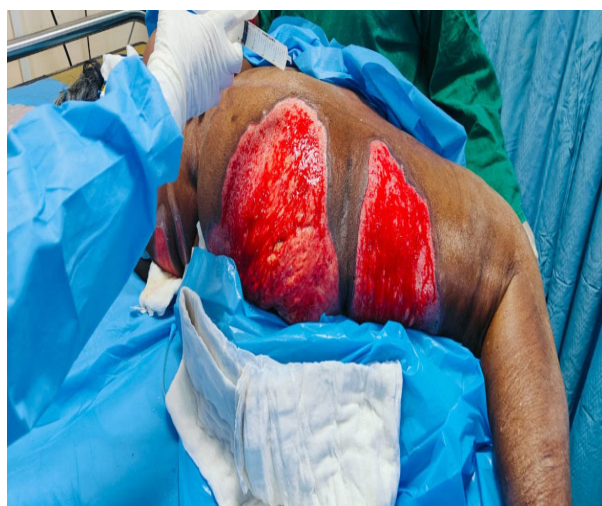

Fig. 5: Condition of the wound after utilization of amniotic membrane regenerative therapy (BJWAT wound score - 32)

DISCUSSION

Partial thickness burn injuries have the potential to heal spontaneously, whereas full-thickness burns typically necessitate skin grafting to achieve complete wound closure. Historically, split-thickness skin autograft has been the preferred method for closing excised full-thickness burn wounds. However, patients with extensive burn injuries may face challenges due to limited availability of donor sites for autograft harvesting, prompting consideration of alternative options such as skin substitutes. Engineered skin substitutes offer temporary coverage for wounds until donor sites are available for autografting or, if containing autologous cells, can provide

permanent closure. While the availability of permanent skin substitutes remains limited, advancements in tissue engineering are anticipated to yield improved models, thus enhancing the options for managing burn wounds. For instance, the commercially available Dermal Regeneration Template comprises a two-layered system. The outer layer, composed of a thin silicone film, serves as a protective barrier against infection and regulates heat and moisture loss. The inner layer, consisting of a collagen glycosaminoglycan (GAG) thermal layer, acts as a biodegradable template facilitating dermal tissue regeneration. The porous nature of the template aids in skin regeneration by serving as a scaffold for tissue growth. Following regeneration of the dermal layer, the outer layer of the template is replaced with a thin epidermal skin graft, allowing for flexible, permanent skin regeneration and promoting faster wound healing with minimal scarring. Seeking to emulate this mechanism, we have developed an indigenous dermal regeneration scaffold using silicone sheet, dry collagen sheets, and amnion. This cost-effective scaffold can be readily prepared and utilized, particularly in hospital settings within developing countries where the affordability of commercial regeneration templates may be a concern.

CONCLUSION

The efficacy of employing a cost-effective regenerative scaffold dressing based on amniotic membrane in treating second degree scald burns has been demonstrated in this investigation. It accelerates the overall healing process of both superficial and deep second-degree wounds to less than a week, thereby reducing hospitalization duration and infection rates. Nevertheless, further extensive multicenter, double-blinded controlled research incorporating statistical analysis is warranted.

REFERENCES

1. Haghpanah S, Bogie K, Wang X, Banks PG, Ho CH. Reliability of electronic versus manual measurement techniques. Arch Phys Med Rehabil.2006;87:1396-1402.
2. Chittoria R K, Kumar P, Baljaj SP, Singh A K, Gupta DK. General clinical guidelines for wound management: Redefining acronym SWCR. Journal of SWCR. 2014;7(1):2-7.
3. Shetty R, Sreekar H, Lamba S, Gupta A K. Anovel and accurate technique of photographic wound

- measurement. *Indian J Plast Surg.* 2012; 45(2): 425-429.
4. Majeske C. Reliability of wound surface area measurement. *Phy Ther.* 1992; 72:138-141.
 5. Mayrovitz HN, Soontupe L B. Wound area by computerized planimetry of digital images. *Adv Skin Wound Care.* 2009; 22:222-229.
 6. Pandey S, Chitoria RK, Mohapatra DP, et al. Application of digital planimetry: A novel technique of wound measurement in diabetic foot ulcer. *Dermatology International.* 2016; 21:343-331.
 7. Pires IM, Garcia NM. Wound area assessment using mobile application. *Proceedings of the International Conference on Biomedical Electronics and Devices Volume 1: Smart Med Dev, International Conference on Biomedical Electronics and Devices; January 12-15; Lisbon, Portugal. 2015. pp. 271-282.*