

Review Article on Management of Postburn Digital Web Space Contracture

Amrutha J S¹, Ravi Kumar Chittoria²

How to cite this article:

Amrutha J S, Ravi Kumar Chittoria. Review Article on Management of Postburn Digital Web Space Contracture. *Ind Jr Anat.* 2023;12(4):147-150.

Abstract

Burn web space contracture refers to the abnormal tightening and narrowing of the skin and underlying tissues that occurs after a burn injury. This condition results from the healing process where scar tissue forms and contracts, leading to limited mobility and functionality in the affected area. In connection with burns, especially in the area between the fingers or other joints, contractures can significantly impair movement and cause functional deficits. Treatment may include surgery, such as skin grafts or releases, coupled with rehabilitation to restore range of motion. This review article covers the different ways to manage digital web contracture.

Keywords: Digital webspace; Contracture; Z plasty; Flaps.

INTRODUCTION

The web space helps with hand movements such as finger abduction, adduction, as well as finger flexion and extension at the metacarpophalangeal joint. Normal web spaces are rectangular in shape with an angle of 45° in the

distal direction to the palmar direction. The arc of the second to fourth web forms a circle.

Blood supply to the web space is from branches of the dorsal and volar digital arteries.¹⁻³ Sensation is via the dorsal radial sensory and ulnar sensory branches. The volar innervation of the nets is branches from the common digital nerves, which are the terminations of the median and ulnar nerves. The first web space mainly by the median nerve and also contributions from the dorsal radial sensory nerve.

The palmar aponeurosis consists of the longitudinal fibers of Legue and Juvar (Fig. 1) in the distal direction, which bifurcate in the proximal extent of the fingers and merge with the tendon sheaths and tissues around the metacarpophalangeal joints volarly and dorsally. They are the endings of the deep fibers of the palmar fascia. Abduction of the finger is limited

Author's Affiliation: ¹Senior Resident, Department of Plastic Surgery, ²Professor, Department of Plastic Surgery & Telemedicine, Jawaharlal Institute of Postgraduate Medical Education and Research, Pondicherry 605006, India.

Corresponding Author: Ravi Kumar Chittoria, Professor, Department of Plastic Surgery & Telemedicine, Jawaharlal Institute of Postgraduate Medical Education and Research, Pondicherry 605006, India.

E-mail: drchittoria@yahoo.com

Received on: 00.00.2023

Accepted on: 00.00.2023

by the transverse subcutaneous band of Bourgerie, which is part of the natatory ligament. This forms the distal extent of the fabric, and its arcuate fibers form the arches between the fingers. These fibers form the volar digital septum of Grayson and the dorsal digital septum of Cleland.

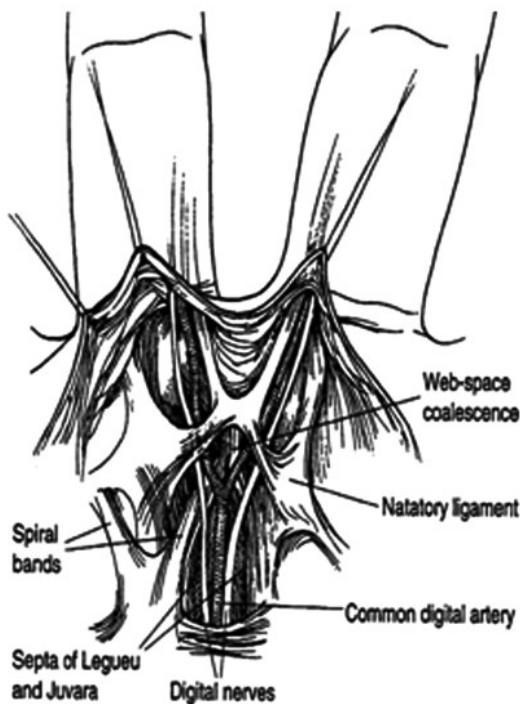


Fig. 1: Webspace anatomy

Postburn contractures affect the arachnoid spaces and lead to major functional and aesthetic deformities. Web contractures are classified according to whether they involve the dorsal web, palmar web, or interdigital space, called burn syndactyly.⁴ Depending on the maturity of the scar tissues, they can again be classified as dynamic or static contractures. Subsequently, burn contractures of the arachnoid spaces limit abduction and independent flexion and extension of the fingers. They can also lead to an inversion of the web space with a bad aesthetic appearance. These contractures affect the normal 45° back slope and palm-to-finger ratio. Contractures of the web of index and thumb may involve only the skin, and in chronic conditions may involve fibrosis and shortening of the adductor pollicis muscle.⁵ In severe and chronic cases, along with soft tissue contractures underlying bony abnormalities, they also occur.

SURGICAL TECHNIQUE

The palmar edge of the web space normally extends to the level of the middle of the proximal phalanx. If the distal edge of the tissue lies between this normal position and 75% of the length of the proximal phalanx, tissue reconstruction can be performed using local tissue rearrangement. If the interdigital contracture exceeds 75% of the length of the proximal phalanx, a dorsal hourglass flap can be performed to reconstruct the web space.⁶ After mesh reconstruction, splinting is necessary to minimize mesh creep and recurrence.

Skin Grafts

Split-thickness skin grafts are not ideal for web space contracture release because they tend to contract during healing. Full-thickness skin grafts contract less and are generally more useful.

Full-thickness skin grafts are widely used in syndactyly release to resurface the adjacent sides of the fingers. The ulnar and thenar eminences can be used. Other sites are the ulnar border of the distal forearm and the medial upper arm. If the male has not yet been circumcised, but if circumcision is planned, the foreskin can also be used as donor skin. The foreskin can provide up to 25 cm² of tissue. If a large amount of skin is needed, the lower abdomen is a good source. Incorporation of Integra as a primary or secondary reconstruction template over which a thin skin graft can be placed has also been described.^{7,8} Using Integra under a skin graft can inhibit contracture and promote improved range of motion.

Local flaps

Local flaps for the reconstruction of webspace contractures are mainly Z-plasties and combinations of Z-plasties with advancement flaps. Various modifications include

- Jumping man flap - Mustarde,
- Five-flap - Hirshowitz and coworkers (Fig. 2).
- V-M flaps - Alexander and coworkers, Lewis and coworkers, and Onishi and coworkers.
- Three-flap web-plasties-Ostrowski and coworkers and Housinger and coworkers (Fig. 3).
- "Goalpost" flap-by Housinger-advancement of a rectangular tissue flap with rotation of small flaps from its distal end along its sides.

- V-Y advancements - used for syndactyly correction by Savaci and coworkers and Sherif. Savaci and coworkers described dorsal and volar V-Y flaps to meet in the center of the web (Fig. 4A).
- Island flap advanced in a V-Y fashion by Sherif to resurface the web (Fig 4B)

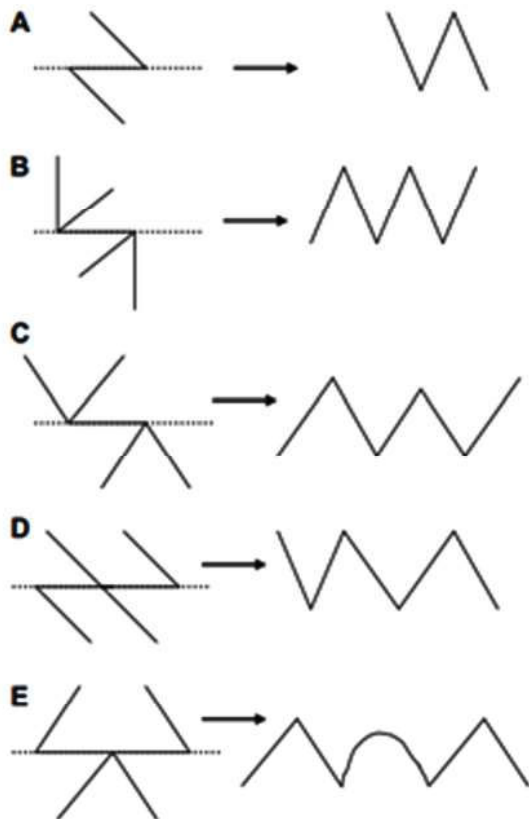


Fig. 2: Variants of Z-plasties. (A) The classic 60-degree angle Z-plasty. (B) The 90-90 degree four-flap Z-plasty. (C) The 120-120 degree four-flap Z-plasty. (D) The Z-plasty in series (E) Double-opposing Z-plasties (butterfly flap). The dotted line refers to the axis of contracture. The figures on the right reflect the appearance after flap rotation.

Regional and free flaps

Regional or free fasciocutaneous flaps are bulky. The most commonly used regional flaps are inguinal flaps. This is flexible and particularly useful if soft tissue wrap is required and if tendon transfers or free-functioning muscle transfers are needed later.

A flap with a transverse arm is also a reconstructive option for first webspace defects. May be more comfortable than groin and abdominal flaps. A defect shaped flap is drawn on the upper

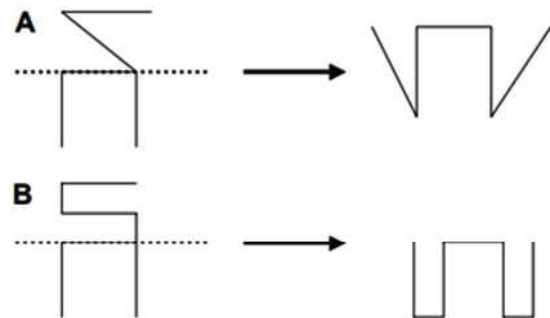


Fig. 3: Three-flap rotation-advancement web-plasties. (A) Triangular flaps of tissue are rotated around the advanced rectangular flap. (B) Rectangular flaps of tissue are rotated around the rectangular flap. The flaps in (B) may be more tenuous and care should be taken in elevating these flaps in tissue that has previously been injured. The dotted line refers to the axis of contracture. The figures on the right reflect the appearance after flap rotation.

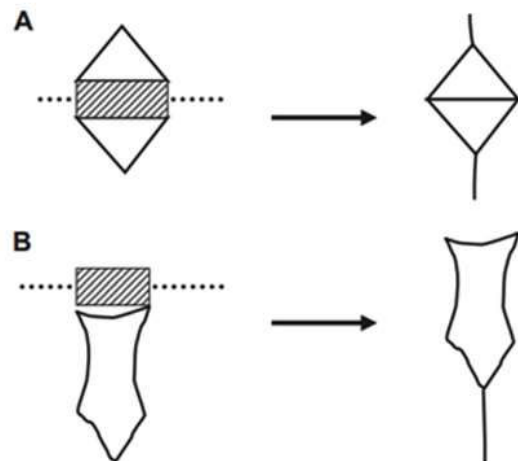


Fig. 4: T V-Y advancement flaps. (A) Opposing V-Y islands as described by Savaci and coworkers. (B) V-Y island advancement as described by Sherif. The dotted line refers to the axis of contracture. The shaded area represents excised scar tissue. The figures on the right reflect the appearance after flap advancement.

arm and the lower half is elevated and sutured to the dorsal part of the web defect. After 2 to 3 weeks, the flap is divided and the upper part is rotated into the defect of the volar structure. The flap needs to be divided of soft tissue for better digital motion and appearance.

The webspace most accessible to free tissue transfer reconstruction or regional flap is the thumb index webspace. The best options for first web reconstruction are reverse radial forearm flap, posterior interosseous artery flap, free dorsalispedis or free temporalis flap, lateral arm flap, scapular or parascapular flap, and various muscle flaps.

CONCLUSION

Basic principles must be followed in the management of web space contractures early non-operative methods are often effective in preventing or limiting the degree of web space contracture, which include early splinting and passive and active range of motion exercises. If operative intervention is necessary for established contractures or for conditions where the occurrence of contractures is likely, the options are many variations and combinations of Z-plasties, V-Y, and V-M advancements.

REFERENCES

1. Zancolli EA, Cozzi EP. The retinaculum cutis of the hand. In: Zancolli EA, Cozzi EP, editors. Atlas of surgical anatomy of the hand. 1st edition. New York: Churchill Livingstone; 1992. p. 1-135.
2. Dautel G, Merle M. Direct and reverse dorsal metacarpal flaps. *Br J Plast Surg* 1992;45:123-30.
3. Chang LY, Yang JY, Wei FC. Reverse dorsometacarpal flap in digits and web-space reconstruction. *Ann Plast Surg* 1994;33:281-9.
4. Gulgonen A, Ozer K. Correction of postburn contractures of the second through fourth web spaces. *J Hand Surg Am.* 2007;32(4):536e564.
5. Smith MA, Munster AM, Spence RJ. Burns of the hand and upper limb a review. *Burns.* 1998;24(6):493e505.
6. Salisbury RE, Bevin AG. Burn syndactyly: the "hourglass" procedure. In: Salisbury RE, Bevin AG, eds. Atlas of Reconstructive Burn Surgery. 1st ed. Philadelphia, PA: Saunders; 2010:180e185.
7. Dantzer E, Queruel P, Salinier L, *et al.* Dermal regeneration template for deep hand burns: clinical utility for both early grafting and reconstructive surgery. *Br J Plast Surg* 2003;56: 764-74.
8. Frame JD, Still J, Lakhel-LeCoadou A, *et al.* Use of dermal regeneration template in contracture release procedures: a multicenter evaluation. *Plast Reconstr Surg* 2004;113:1330-8.

