

## Unilateral Sixth Nerve Palsy Due to Systemic Hypertension

Mridu Bhaskar<sup>1</sup>, Kishalay Datta<sup>2</sup>, Anita Rawat<sup>3</sup>, Uzma Khanam<sup>4</sup>

### How to cite this article:

Mridu Bhaskar, Kishalay Datta et al./Unilateral Sixth Nerve Palsy Due to Systemic Hypertension/Indian J Emerg Med 2022;8(4):147-148.

**Author's Affiliation:** <sup>1</sup>Post Graduate Trainee, <sup>2</sup>Director and HOD, <sup>3</sup>Senior Consultant, <sup>4</sup>Resident, Department of Emergency Medicine, Max Superspeciality Hospital, Shalimar bagh, New Delhi 110088, India.

**Corresponding Author:** Mridu Bhaskar, Post Graduate trainee, Department of Emergency Medicine, Max Superspeciality Hospital, Shalimar bagh, New Delhi 110088, India.

**E-mail:** dr.mridu13@gmail.com

**Received on:** 21.05.2022

**Accepted on:** 24.06.2022

### Abstract

Systemic hypertension has been frequently reported as ischemic cause of sixth nerve palsy, but few rigorous studies have been done to support this study.

**Keywords:** Sixth Nerve Palsy; Systemic Hypertension.

## INTRODUCTION

The sixth cranial nerve runs a long course from the brain stem to lateral rectus muscle. Most common causes implicated in sixth nerve palsy are stroke, trauma, tumour, infection and ischemic causes-systemic hypertension and diabetes mellitus. In this case report, a man presented with headache and difficulty in walking due to blurring of vision.

## CASE

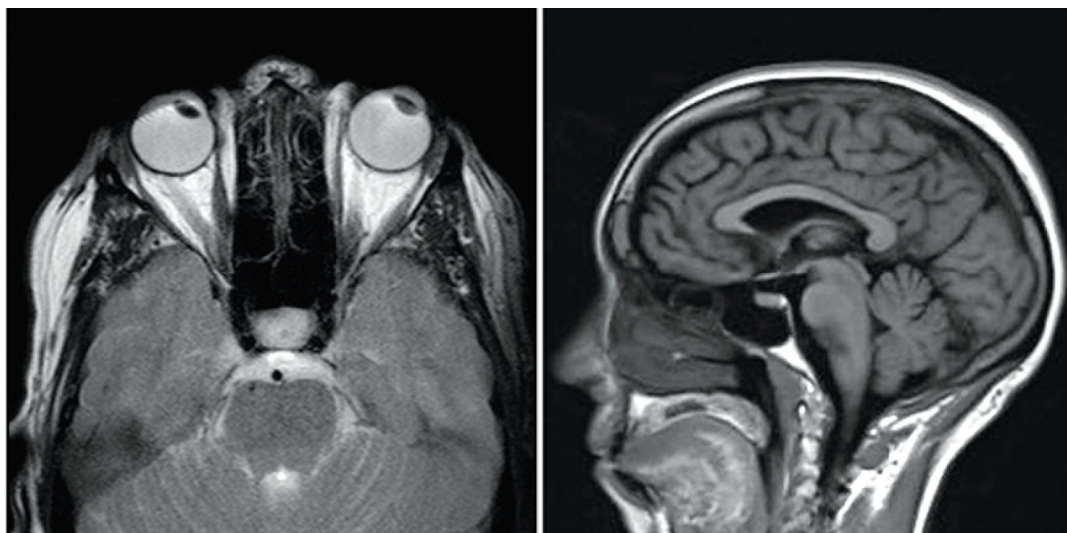
A 63 year old male patient was brought to the Emergency department with complaints of headache and difficulty in walking due to sudden

onset painless blurring of vision since 2 days. Vitals noted were: BP: 120/80 mm hg , RBS: 125 mg/dl. Patient was a known case of hypertension under regular medications. Patient took tablet Telma-AM before coming to emergency.

Patient reported to have raised blood pressure readings at home for 3 consecutive days prior to onset of symptoms. Blood pressure readings reported were - 200/120 mm hg, 190/100 mmhg, 210/110mm hg. No history of trauma, eye pain, fever, cough or any other systemic symptoms were reported. On clinical examination - Right Lateral Rectus palsy suggested by right side blurred vision with diplopia on right sided far gaze was noted. No focal motor deficits in

limbs were seen. A provisional diagnosis of cerebrovascular accident – stroke was made and management was started. Initial MRI Brain report had calcified granulomas in both temporal lobes and non specific foci of altered signal appearing hyperintense on T2 and Flair

involving bilateral cerebral white matter – suggestive of microvascular changes. Stroke, tumor and infections as causative factors were ruled out. Microvascular ischemic changes due to accelerated hypertension was identified as the cause of unilateral lateral rectus palsy.



MRI Contrast of Orbit reported no findings suggestive of tumor

## DISCUSSION

Diplopia with headache usually indicates a potentially serious pathology and requires neuromaging. MRI Brain and orbit – with / without contrast is the imaging of choice due to its superior resolution of cavernous sinus, dura and brainstem. CT scan is study of choice in case of traumatic cause leading to diplopia. Isolated abducens / sixth nerve palsy in elderly patients with vascular risk factors – hypertension is often related to microvascular ischemia. The situation requires diagnosis and treatment of the identified vascular risk factor. The prognosis of the disease is widely dependent on early diagnosis and immediate intervention.

## CONCLUSION

Unilateral lateral rectus palsy presenting as headache and diplopia in elderly patients is

attributed to systemic hypertension induced microvascular ischemia. MRI is the study of choice. Strict control of blood pressure is the mainstay of treatment. Early diagnosis and treatment has shown good prognosis with complete resolution within 6 months.

## REFERENCES

1. Diabetes and hypertension in isolated sixth nerve palsy: a population-based study Sanjay V Patel 1, Jonathan M Holmes, David O Hodge, James P Burke.
2. Isolated bilateral sixth nerve palsy secondary to metastatic carcinoma: a case report with a review of the literature Zafer Kocak 1, Yahya Celik, M Cem Uzal, Kazim Uygun, Meryem Kaya, Sait Albayram.
3. Abducens Nerve Palsy in Pregnancy: A Case Report Journal of Clinical and Diagnostic Research.

