

Study on the Nutrient Foramen of Long Bones of Lower Limb

Makani Thanuja Kumari¹, Lattupalli Hema²

How to cite this article:

Makani Thanuja Kumari, Lattupalli Hema. Study on the Nutrient Foramen of Long Bones of Lower Limb. Indian J Anat. 2020;9(2):142-149.

Author's Affiliation: ¹Assistant Professor, ²Professor and Head, Department of Anatomy, Narayana Medical College, Chintareddypalem, Nellore, Andhra Pradesh 524003, India.

Corresponding Author: Lattupalli Hema, Professor and Head, Department of Anatomy, Narayana Medical College, Chintareddypalem, Nellore, Andhra Pradesh 524003, India.

E-mail: hemakarra06@gmail.com

Received 19.03.2020 | **Accepted** 17.06.2020

Abstract

Introduction: The success of any transplant lies in the surgeon's ability to preserve its vascular supply and its rapid reconstruction, especially in free vascularized bone grafts, which preserve viability of osteocytes, act as space filler and introduce a new vascular bed for the reconstruction of defects following trauma, tumour resection, congenital pseudoarthrosis and any cases of difficult non-union bones.

Aims and Objectives: The aim of the present study is to: To determine the number and position of the nutrient foramina in the upper and lower limb long bones. To determine the location and direction of nutrient canal. To determine whether the nutrient foramina obey the general rule that is directed away from the growing end of long bone.

Material and Methods: The present study is carried out on 150 human cleaned and dried bones of the Upper limb. The samples were taken from Narayana Medical College, Chintareddypalem, Nellore, Andhra Pradesh. The long bones included for the study was as follows: Femur- 50, Tibia- 50, Fibula- 50. All the bones that were taken for the study were normal and had no pathological changes were present. The age and the sex of the bone were unknown. In all these bones after determining the side of bone, the "Nutrient Foramen" were studied in regards with. (1) The number of foramina on the shaft of the bone. (2) Surface on which it was located. (3) Direction from growing end. (4) Location in relation with length of the shaft.

Observation and Results: Total 150 long bones of Lower limb of right and left side of unknown age and

sex were taken for the study. The parameters studied were depending on the number of nutrient foramina, direction of foramina and their distribution at various levels. The results and observations of the study are presented as tables.

Conclusion: Importance of nutrient foramen is relevant to fracture treatment. Combined periosteal and medullary blood supply to the bone cortex helps to explain the success of nailing of long bones fractures particularly in the weight bearing like femur and tibia uses of vascularised fibula bone in bony defects due to trauma. Currently, the detailed study of blood supply to long bone is a determining factor for the success of newer techniques and resection in orthopedics.

Keywords: Nutrient foramina; Nutrient artery; Humerus; Radius; Ulna bones.

Introduction

The nutrient artery is the principal source of the blood to along bone particularly during its growth period in the embryo and fetus as well as during early phases of ossification (Lewis, 1956; Patake & Mysorekar, 1977; Forriol Campos et al., 1987;^{5,16,22} during childhood, long bones receive about 80% of the interosseous blood supply from the nutrient arteries, and in the case of their absence, the vascularisation occurs through the periosteal vessels (Trueta, 1953).²⁵ Because the artery of the shaft of the long bone is largest it is called the "Nutrient Artery". Nutrient canal typically becomes slanted during the growth, the direction



of slant from surface to marrow cavity point towards the end that has grown least rapidly. This is due to greater longitudinal growth at the faster growing end, hence the derivation of the axiom that foramina "seek the elbow and flee from the knee". Bones are structures that adapt to their mechanical environment, and from the fetal age adapt to a naturally occurring holes. The holes or nutrient foramina, allow blood vessel to pass through the bone cortex (Gotzen et al., 2003).⁶ The cavities conducting the blood vessels and peripheral nerves on the surface of shaft of long bones are called as "Nutrient Foramen". The role of nutrient foramen is evident from the term "Nutrient" itself. The nutrient foramina has been studied in the past by Berard (1835), Schwalbe (1876), Langer (1876).^{1,2,3,15}

The location of nutrient foramen is important in longitudinal stress fractures, as they can either initiate from the nutrient foramina or the supero medial aspect: longitudinal stress fractures are more commonly associated with tibia, but occasionally occur in femur, fibula and patella (Craig et al., 2003).³ Clinical fracture of a long bone is usually accompanied by the rupture of the nutrient artery with variable disruption of the peripheral vessels associated with periosteal detachment. Following fracture the ruptured nutrient artery and the periosteal vessels, together with those in the adjacent soft tissue, start bleeding (Trueta, 1974).²⁵ An understanding of the location and the number of the nutrient foramina in long bones is, therefore important in orthopedic surgical procedures such as joint replacement therapy, fracture repair bone grafts and vascularised bone microsurgery as well as medico legal cases (Trueta, 1974; Longia et al., 1980; Guo, 1981; Forril Campos et al., 1978).^{5,17,25}

Detailed data on the blood supply to long bones and the association with the areas of bone supplied has been, and continues to be, a major factor in the development of new transplantation and resection techniques in orthopedics (Kirschner et al., 1998).¹² However, there is still a need for a greater understanding of the location and number of nutrient foramen in bones such as Femur, Tibia and Fibula. By defining this restricted area of "Nutrient Artery" entering into the nutrient canal, surgeons can void that during surgical operations and thereby prevent damage to nutrient artery and minimize or lessen the chances of non-union of fracture of the bone.

Aim and Objectives

The aim of the present study is to:

1. To determine the number and position of the nutrient foramina in the lower limb long bones.
2. To determine the location and direction of nutrient canal.
3. To determine whether the nutrient foramina obey the general rule that is directed away from the growing end of long bone.

Materials and Methods

The present study is carried out on 150 human cleaned and dried bones of the Lower limb. The samples were taken from Narayana Medical College, Chinthareddypalem, Nellore and Sri Venkata Padmavathi Medical college (SVIMS) of Andhra Pradesh. The long bones included for the study was as follows:

- Femur - 50,
- Tibia - 50,
- Fibula - 50.

All the bones that were taken for the study were normal and no pathological changes were present. The age and the sex of the bone were unknown. In all these bones after determining the side of bone, the "Nutrient Foramen" were studied in regards with

1. The number of foramina on the shaft of the bone.
2. Surface on which it was located.
3. Direction from growing end.
4. Location in relation with length of the shaft.

Nutrient foramina were distinguished by the presence of a well marked groove leading to the foramen, and by a well marked often slightly raised edge of the foramen at the commencement of the canal. In doubtful cases a dissecting microscope was used to locate the foramen. For direction of canal fine stiff wire was passed through the foramen to confirm its direction. The size of nutrient foramen was determined by using hypodermic needle No. 20 & 24. (Hidustan Syringes and Dispovan Pvt. Ltd.).

- Large foramen -accepted the No. 20 needle.
- Medium foramen -accepted only the No. 24 needle.
- Small foramen -did not take No. 24 needle.

When more than one foramen was present, the larger one was considered Dominant (DF), and

nutrient foramina smaller than a size 24 hypodermic needle were considered as being secondary nutrient foramina (SF)

Femur: The distance between the superior aspect of the head of the femur and the distal aspect of the medial condyle.

Tibia: The distance between the superior margin of the medial condyle and the distal aspect of medial malleolus

Fibula: The distance between the apex of the head of the fibula and the distal aspect of the lateral malleolus.

All measurements were taken to the nearest 0.1 mm using a digital vernier caliper. The results were analyzed and tabulated using the Statistical Package for the Social Sciences (SPSS) 8.0 windows. The range, mean and standard deviation of Foramina Index were determined.

Observation and Results

Total 150 long bones of Lower limb of right and left side of unknown age and sex were taken for the study. The parameters studied were depending on the number of nutrient foramina, direction of foramina and their distribution at various levels. The observations of the study are presented as tables.

Discussion

In this study, (52%) of the femora examined possessed double nutrient foramina, While (46%) had only one nutrient foramen and (2%) had triple

nutrient foramen. Many authors stated that the majority of femora studied had double nutrient foramina (Mysorekar, 1967);²⁰ (Forriol Campos et al., 1987);⁵ (Nagel, 1993);²¹ (Gumusburun et al., 1994);⁸ (Collipal, 2007),² while others reported the presence of a single foramen in most specimens (Lutken, 1950);¹⁸ (Laing, 1953);¹⁴ (Longia et al., 1980);¹⁷ (Sendemir and Cimen, 1991);²⁴ (Emi Kizilkanat et al., 2007)⁴. Three nutrient foramina were observed in a small number of femora (2.19–10.7%) by many authors (Lutken, 1950);¹⁸ (Longia et al., 1980);¹⁷ (Forriol Campos et al., 1987);⁵ (Nagel, 1993);²¹ (Gumusburun et al., 1994);⁷ (Collipal, 2007),² others confirmed the absence of nutrient foramina in some femora (Mysorekar, 1967);²⁰ (Gumusburun et al., 1994).⁸

In this study, the whole series of tibiae examined had a single nutrient foramen (100%). Previous studies reported the presence of a single nutrient foramen in at least 90% of the tibiae. But, in contradiction with the present results, they also reported the presence of double nutrient foramina in some of the tibiae (Mysorekar, 1967).²⁰ In the fibulae studied, (88%) of the bones presented a single nutrient foramen, while (10%) of the bones possessed double nutrient foramina, and (2%) of the bones had absence of nutrient foramina. Similar data had been reported by Mysorekar (1967),²⁰ Longia et al. (1980),¹⁷ Guo (1981),¹⁰ Mckee et al. (1984),¹⁹ Forriol Campos et al. (1987)⁵ and Sendemir and Cimen (1991),²⁴ while Mckee et al. (1984)¹⁹ reported fibulae with three nutrient foramina. On the other hand, Mysorekar (1967),²⁰ Mckee et al. (1984),¹⁹ Gumusburun et al. (1994)⁸ and Kizilkanat et al. (2007)¹³ reported fibulae with no nutrient foramina. (Table 1).

Table 1. Number of nutrient foramina observed in the long bones of lower limb.

Bone	Number of Bone	Number of Foramina	Percentage (%)
Femur	23	1	46
	26	2	52
	1	3	2
	-	0	-
Tiba	50	1	100
	-	2	-
	-	3	-
	-	0	-
Fibula	44	1	88
	5	2	10
	-	3	-
	1	0	-

Position of Nutrient Foramina

In the present study, most of the nutrient foramina of the femur bone (68%) were located along the linea aspera and a narrow slip along it. These were coinciding with the finding of Lutken (1950)¹⁸ and Longia et al., (1980)¹⁷ who stated that most of the nutrient foramina are concentrated on the linea aspera. In this single foramina were 19 and are dominant foramina, two nutrient foramina had 25 dominant and 7 secondary foramina, three nutrient foramina had 1 dominant and 1 secondary foramina. On the posterior surface only 1% that were double dominant nutrient foramina. On the lateral surface

4% were seen out of which single dominant was 1 and double secondary foramina were two. On the medial aspect the foramina accounted to 27% out of which single dominant foramina are 3 and two secondary foramina are 17. Interesting feature is that all are situated in the proximal 2/3rd, with no foramina detected in the distal third of the femur. These results were in accordance with those of Laing (1953),¹⁴ Mysorekar (1967).²⁰ However, these findings did not coincide with that of Lutken (1950)¹⁸ and Forriol Campos et al. (1987)⁵ who stated that the nutrient foramina are nearer to the hip joint. All these finding are tabulated in Table 2 and photographed in (Fig. 1).

Table 2. Position and number of dominant (DF) and secondary (SF) nutrient foramina observed in the Femur.

Position	Total Number of Foramina	%	Number of Foramina					
			Single		Two		Three	
			DF	SF	DF	SF	DF	SF
Linea aspera	53	68	19	-	25	7	1	1
Posterior surface	1	1	-	-	1	-	-	-
Lateral surface	03	4	1	-	-	2	-	-
Medial surface	21	27	3	-	-	17	-	1

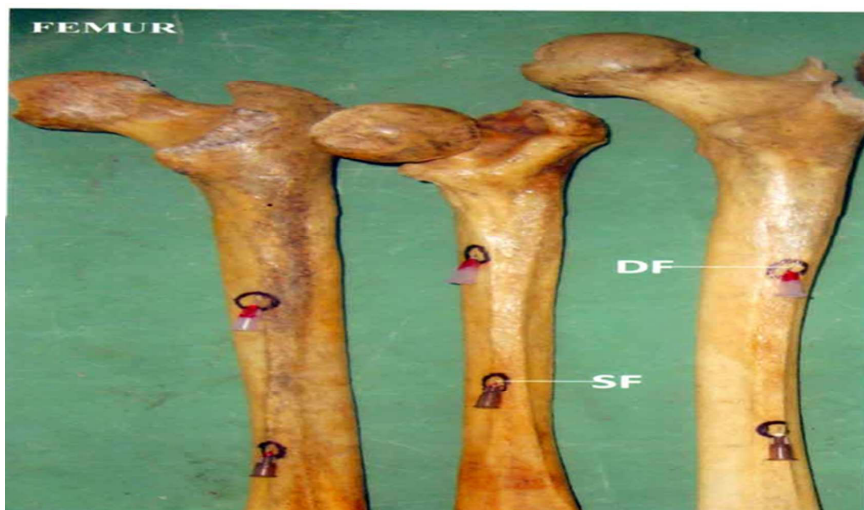

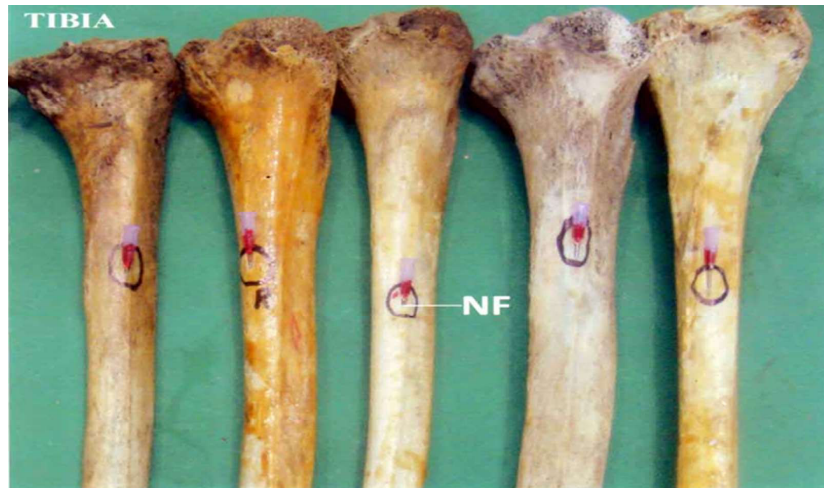Fig. 1: A photograph of the posterior surface of right femora shaft showing double nutrient foramina (NF). Both foramina are directed upwards as shown by the needles inserted.

In the present study, most of the nutrient foramina in the tibiae were in the proximal third 88%. Nutrient foramina were located in the middle third in the rest of the tibiae examined (12%). 94% of the foramina were on posterior surface out of which 47 were single dominant foramina. On the lateral surface 6% of the foramina were seen out of which 3 were dominant single nutrient foramina. There were no foramina in the distal third. Similarly, many authors reported

the presence of the majority of nutrient foramina in the proximal third of the tibia (Mysorekar, 1967; Longia et al., 1980; Gumusburn et al., 1994; Collipal et al., 2007).^{2,8,17,20} The rate of healing of a fracture is related to the vascular supply of the bone. In the present series, most of the nutrient foramina of the fibula were situated in the middle third of the bone (94.4%). The above findings are tabulate in Table 3 and photographed in (Fig. 2).

Table 3. Position and number of dominant (DF) and secondary (SF) nutrient foramina observed in the Tibia.

Position	Total Number of Foramina	%	Number of Foramina			
			Single		Two	
			DF	SF	DF	SF
Posterior surface	47	94	47	-	-	-
Lateral surface	3	6	3	-	-	-

**Fig. 2:** A photograph of the posterior surface of right tibiae showing a single nutrient foramen (NF). The foramen is located in the proximal third (Type 1) and is directed downward.

The single fibula nutrient foramina (1.9%) were located in the distal third of the bone, while 3.7% had nutrient foramina in the upper third. These results were in agreement with most of the previous studies (Mysorekar, 1967; Mckee et al., 1984; Forriol Campos et al., 1987; Sendemir and Cimen, 1991; Gumusburun et al., 1994; Collipal et al., 2007).^{2,5,8,19,20,24} On other hand, Guo (1981)¹⁰ reported that the majority of foramina were located in the proximal third of the fibula.

In this study, 75.9% of the fibular foramina were located on the posterior surface of which 66.66% of foramina were on the medial crest and 75.9% on the posterior surface and remaining 24.1% on the medial surface. On the posterior surface 41% were seen in which dominant foramina were single and 35 in number whereas two nutrient foramina had

2 dominant and four secondary. On the medial surface 24.1% single dominant were 9 and double dominant were 3 and secondary were 1 (Table 4 and Fig. 3). Similarly, Mysorekar (1967)²⁰ reported that 56% of nutrient foramina were located on the medial crest while 33% lied on the posterior surface of fibula. However, some authors observed more nutrient foramina on the posterior surface compared to those on the medial crest (Mckee et al., 1984; Forriol Campos et al., 1987; Gumusburun et al., 1994; Kizilkanat et al., 2007; Collipal et al., 2007).^{2,5,8,13,19} Others, (Sendemir and Cimen, 1991)²⁴ reported that the majority of foramina were on the medial surface of the fibula. Knowing the variations in the distribution of the nutrient foramina is important preoperatively, especially regarding the fibula used in bone grafting.

Table 4. Position and number of dominant (DF) and secondary (SF) nutrient foramina observed in the Fibula.

Position	Total Number of Foramina	%	Number of Foramina			
			Single		Two	
			DF	SF	DF	SF
Posterior surface	41	75.9	35	-	2	4
Midial surface	13	24.1	9	-	3	1

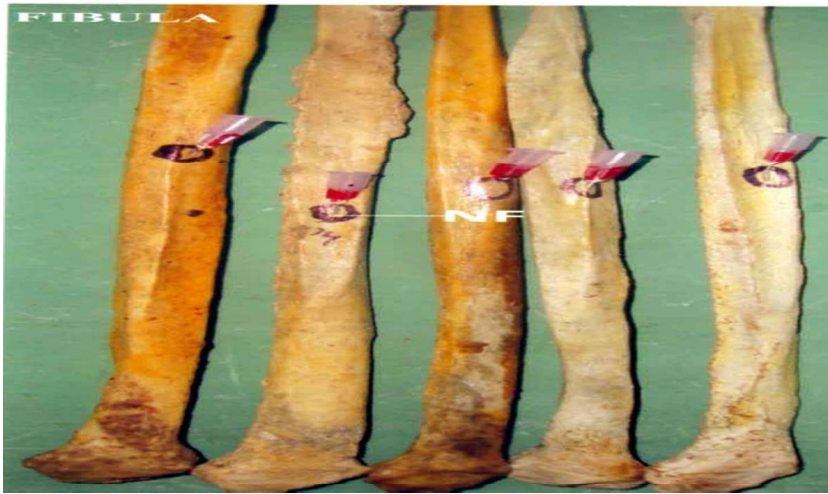


Fig. 3: A photograph of right fibulae showing single nutrient foramina (NF) on the posterior surface of the shaft. Foramen is located in the middle third (Type 2); the foramen is directed downward as shown by the needle inserted.

The present study proved that most of the nutrient foramina were observed to lie on the flexor surface of the bones. Thus, the femur, tibia and fibula, they were located on the posterior surface. Kizilkanat et al. (2007)¹³ stated that the position of the nutrient foramina was directly related to

the requirements of a continuous blood supply to specific aspects of each bone, for example where there were major muscle attachments. It might be that, being more bulky, stronger and more active, flexors need more blood supply compared to extensors of limbs.

Table 5. Position and direction of nutrient foramina in the long bones of lower limb.

Bone	Position		
	Type 1	Type 2	Type 3
Femur	3 (3.8%)	75 (96.2%)	0
Tibia	44 (88%)	6 (12%)	0
Fibula	2 (3.7%)	51 (94.4%)	1 (1.9%)

Size of Nutrient Foramina

The present results showed that, with the exception of the femur in which most of the foramina studied were dominant, all long bones of lower limb possessed a majority of secondary nutrient foramina. These results were in agreement with those of Longia et al. (1980)¹⁷ who reported that about two third of the nutrient foramina were secondary. The present results contradicted with those of kizilkanat et al. (2007)¹³ who stated that most foramina were of the dominant type. They added that wherever a single nutrient foramen was observed, it was always dominant. This was the case in the present study. Sendemir and Cimen (1991)²⁴ stated that there was no femur without a dominant nutrient foramen. Such statement was applicable in the present study.

Direction of Nutrient Foramina

Hughes (1952)¹¹ stated that anomalous canals were found frequently in the femur, which might be the cause of the latter findings. The present study confirmed the previous reports suggesting that the nutrient foramina in the tibiae 1 was directed towards the growing end and remaining all were away from the growing end. (Mysorekar, 1967);²⁰ (Hughes, 1952).¹¹ On the other hand, Longia et al. (1980)¹⁷ observed nutrient foramina directed towards the knee in 3.5% of tibiae examined.

Regarding the fibula, the direction of 3 nutrient foramina was directed towards the growing end, while 46 foramina were directed away from the growing end. In accordance with the present results, Longia et al. (1980)¹⁷ reported nutrient foramina having a proximal direction in 9.5% of

fibula examined. Mysorekar (1967)²⁰ added that variations, in the direction of nutrient foramina were found only in the fibula.

Obliquity of Nutrient Foramina

In all long bones of lower limbs examined, there were no changes in the Obliquity of the foramen whether it was in the centre of the bone or nearer the ends. Such results were in agreement with those of Mysorekar (1967).²⁰ Many theories had been put forward to account for the generally constant direction of the canals, and also the anomalously directed ones. Among these were the 'Periosteal slip' theory of Schwalbe (1876),²³ the vascular theory of Hughes (1952)¹¹ and the muscular theory of Lacorix P (1950)²² the 'vascular theory' appeared to offer the most comprehensive explanation but, instead of only one theory explaining the anomalous foramina, all factors may be appropriately and proportionately responsible in individual bones.

Conclusion

The present study was undertaken to study the nutrient foramina of the lower limb long bone. The study material consisted of 150 long bones; each bone was studied for the number, position, size, direction & obliquity of their nutrient foramina. With the exception of femur, majority of nutrient foramina of all bones were single in number and were secondary in size. Most of the nutrient foramina were concentrated in the middle third of the bone with exception of tibia and ulna in which the nutrient foramina were predominantly observed in the proximal third. Nutrient foramina were mostly located on the posterior surface of the shaft of bones of lower limb. The direction of nutrient foramina followed the growing end theory, with variations in the direction observed in some tibia and fibulae. The results of the present study confirmed previous findings regarding the number and position of nutrient foramina of long bones of the limbs and provided clinical information concerning the nutrient foramina which could be useful as reference for surgical procedures. Accordingly, a well understanding of the characteristic morphological features of the nutrient foramina by orthopedic surgeons is recommended. Exact position of the distribution of the nutrient foramina in bone diaphysis is important to avoid damage to the nutrient vessels during surgical procedure.

References

1. Berard A. Memoire sur le rapport qui existe entre la direction des conduits nourriciers des os longs et l'ordre suivant lequel les epiphysis se soudent au corps de l'os. Archives generales de medicine. 1835;7:176-183.
2. Collipal E, Vargas R, Parra X, et al. Diaphyseal nutrient foramina in the femur, tibia and fibula bones. Int. J. Morphol 2007;25(2):305-08.
3. Craig JG, Widman D, van Holsbeeck M. Longitudinal stress fracture: Patterns of edema and the importance of the nutrient foramen. Skeletal Radiol 2003;32:22-27.
4. Kizilkanata E, Boyana N, Ozsahina ET, et al. A study of the nutrient foramina in human long bones. Surg. Radiol. Anat 1987;9:251-55.
5. Gotzen N, Cross ., Ifju P, et al. Understanding stress concentration about a nutrient foramen. J. Biomech 2003;36:1511-21.
6. Gumusburun E, Adiguzel E, Erdil H, et al. A study of the nutrient foramina in the shaft of the fibula. Okajimas Folia Anat. Jpn 1996;73(2-3):125-28.
7. Gumusburun E, Yucel F, Ozkan Y, et al. A study of the nutrient foramina of lower limb long bones. Surg. Radiol. Anat 1994;16:409-12.
8. Guo F. Fibular blood supply. Chin. Med. J. 1981;94:396-400.
9. Guo F. Observation of the blood supply to the fibula. Arch. Orthop. Traumat. Surg 1981;98:147-51.
10. Hughes H. The factors determining the direction of the canal for the nutrient artery in the long bones of mammals and birds. Acta anat 1952;15:261-80.
11. Kirschner MH, Menck J, Hennerbichler A, et al. Importance of arterial blood supply to the femur and tibia for transplantation of vascularized femoral diaphyses and knee joints. World J. Surg 1998;2:845-52.
12. Kizikanat E, Boyan N, Ozsahin ET, et al. Location number and clinical significance of nutrient foramina in human long bones. Ann Anat 2007;189:87-95.
13. Laing PG. The blood supply of the femoral shaft. J. Bone Jt. Surg 1953;35:462-66.
14. Langer K. (1876). Uber das Gefässsystem der Röhrenknochen, mit Beiträgen zur Kenntnis des Baues und der Entwicklung des Knochengewebes. Denkschr. Akad. Wiss. Wien 36:1-40.
15. Lewis OJ. The blood supply of developing long bones with special reference to the metaphyses.

- J. Bone Jt. Surg 1956;38:928-33.
16. Longia GS, Ajmani M., Saxena SK, et al. Study of diaphyseal nutrient foramina in human long bones. *Acta Anat. (Basel)* 1980;107:399-406.
 17. Lutken P. Investigation into the position of the nutrient foramina and the direction of the vessel canals in the shafts of the humerus and femur in man. *Acta anat* 1950;9:57-68.
 18. McKee NH, Haw P, Vettese T. Anatomic study of the nutrient foramen in the shaft of the fibula. *Clin. Orthop. Rel. Res* 1984;184:141-44.
 19. Mysorekar VR. Diaphysial nutrient foramina in human long bones. *J Anat* 1967;101:813-22.
 20. Nagel A. The clinical significance of the nutrient artery. *Orthop. Rev* 1993;22:557-61.
 21. Patake SM, Mysorekar VR. Diaphysial nutrient foramina in human metacarpals and metatarsals. *J. Anat* 1977;124:299-304.
 22. Schwalbe G. Über die Ernährungskanäle und das Knochenwachstum. *Zeitschr F. Anat. U. Entwgesch* 1:307-52.
 23. Sendemir E, Cimen A. Nutrient foramina in the shafts of lower limb long bones: situation and number. *Surg. Radiol. Anat* 1991;13:105-08.
 24. Trueta J. Blood supply and the rate of healing of tibial fractures. *Clin. Orthop. Rel. Res* 1974;105:11-26.
-
-