

## Cauda Equina Syndrome and the Adolescent Patient with Low Back Pain: A Case Report

Farzin Vajifdar<sup>1</sup>, Renaldo Pavrey<sup>2</sup>

### How to cite this article:

Farzin Vajifdar, Renaldo Pavrey/Cauda Equina Syndrome and the Adolescent Patient with Low Back Pain: A Case Report /Indian J Emerg Med 2023;9(3): 135 - 138.

### Abstract

Low back pain is a common complaint in adults of all ages, and is being increasingly seen in children and adolescents. The lifetime occurrence of low back pain is around 59%.<sup>1</sup>

Mechanical low back pain is globally one of the most common presentations seen by the Emergency Physician.<sup>14</sup> Most cases of low back pain treated in the Emergency Department (ED) are not true emergencies, a notable exception being the Cauda Equina Syndrome (CES).

Owing to the low occurrence and low index of suspicion in the pediatric/adolescent age group, there may be a significant delay in diagnosis of Cauda Equina Syndrome. This is concerning, because delay in diagnosis and there by treatment, runs the risk of permanent neurological damage and disability. Unequivocally, the most common predictor of a favourable outcome in CES is early diagnosis.<sup>2</sup>

We present the case of a 16-year-old male who presented to the ED on three separate occasions complaining of low back pain. The patient had red flag signs during the second visit; however, the relevant history and clinical findings were not elicited at the time. On the third ED visit, a clinical diagnosis of CES was made and urgent magnetic resonance imaging of the lumbo-sacral spine revealed a large right para-central herniation of the L4-L5 disc indenting the right L5 nerve root.

Our aim in highlighting this case is two fold:

1. To make the Emergency Physician aware of the rare diagnosis of CES in this uncommon age group.
2. To stress the importance of early recognition of red flag signs in CES which will lead to an early diagnosis, and thereby a favourable outcome.

**Keywords:** Cauda Equina Syndrome; Lumbar Disc Herniation; Adolescent Back Pain.

**Author's Affiliation:** <sup>1</sup>Consultant, Department of Emergency Medicine, Holy Family Hospital, Mumbai 400050, Maharashtra, India, <sup>2</sup>Senior Consultant, Emergency Medicine, Nanavati Max Centre for Accident & Emergency Medicine, NMSSH Mumbai 400056, Maharashtra, India.

**Corresponding Author:** Renaldo Pavrey, Senior Consultant, Emergency Medicine, Nanavati Max Centre for Accident & Emergency Medicine, NMSSH Mumbai 400056, Maharashtra, India.

**E-mail:** [renaldo.pavrey@gmail.com](mailto:renaldo.pavrey@gmail.com)

**Received on:** 17-04-2023 **Accepted on:** 18-05-2023

### INTRODUCTION

The vertebral column is a series of 33 bones called vertebrae, which are separated by intervertebral discs that permit flexibility of the spine and act as shock absorbers.

Lumbar intervertebral discs are complex structures that undergo significant axial loading as well as flexion extension, lateral bending, and rotational forces. Owing to the biomechanical demands placed on these structures, as well as their

inability to remodel due to their avascular nature, lumbar disc herniation are common.

Herniation of an intervertebral disc occurs when the nucleus pulposus ruptures, breaking through the annulus pulposus. The rupture usually occurs in a postero-lateral direction, following which the nucleus pulposus can irritate the nearby spinal nerves, resulting in a variety of muscular and neurological symptoms. Cauda Equina Syndrome occurs when the lumbar nerve roots are compressed, variably affecting the sensory and motor function, as well as bladder and bowel control.

Ninety percent of lumbar disc herniation occur either at the level of L4-L5 or L5-S1 vertebrae.<sup>3</sup> The reported incidence of Cauda Equina resulting from herniated lumbar discs varies from 1 - 15 %.<sup>4</sup> Cauda Equina can be a challenging diagnosis, especially when seen in the paediatric age group. History is a crucial aspect of examination, especially in early presentations. The combination of recent loss of bladder and bowel control is known to have a specificity of 97.4% in the clinical diagnosis of Cauda Equina.<sup>13</sup>

Cauda Equina Syndrome is a true surgical emergency. The prognosis for complete recovery in Cauda Equina is dependent on many factors, the most important being the severity and duration of nerve compression. As a rule of thumb, the longer the time before surgical decompression of the impinged/compressed nerves, the greater the damage. This highlights the importance of early recognition of red flag signs in low back pain for early detection of CES.

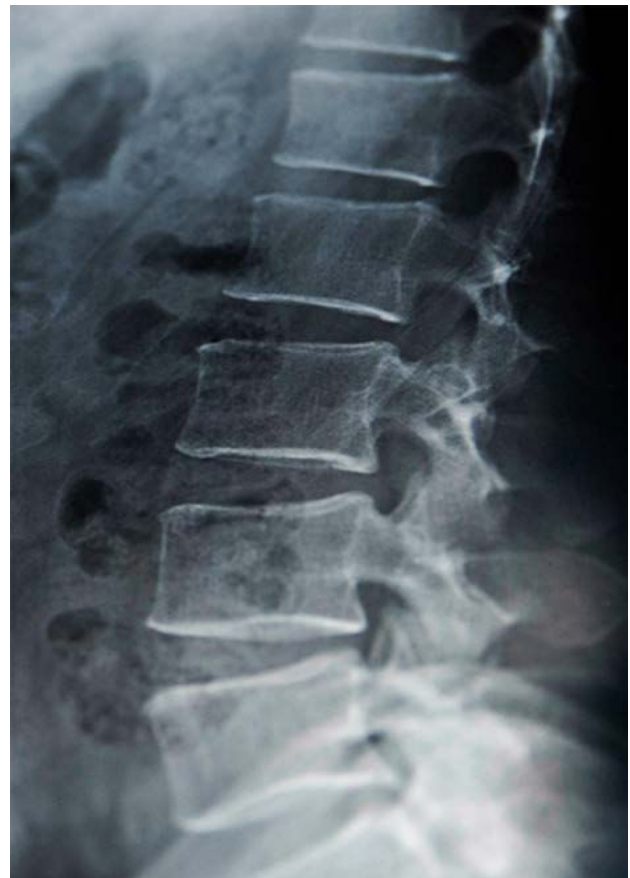## CASE PRESENTATION

A 16-year-old male with no co-morbid conditions and normal body mass index, presented to the Emergency Department (ED) with complaints of low back pain. On the primary visit, the patient had no red flag signs in history or clinical examination, with no radiculopathy or neurological deficit. The patient was discharged on oral analgesics, with advice to follow up in case of persistent pain.

The patient revisited the ED after 10 weeks with a history of worsening lower back pain over the last 2 months, with no relief from physiotherapy, which he was undergoing on the advice of a general practitioner. The pain had significantly aggravated over the last 5 - 7 days. This time, the patient also complained of increased pain while walking for the past one week, with low back pain radiating to both legs below the knee, but more on the right side. The patient was allegedly ambulatory, and denied any history of a fall or trauma, heavy weight lifting,

fever, weight loss or night sweats. The patient was given intravenous analgesia, which led to partial resolution of pain in the ED. A plain radiograph of the lumbosacral spine (Fig. 1) was done, which was unremarkable except for loss of lumbar lordosis. The patient was discharged on oral analgesics with advice to follow up with the physiotherapist.

The patient revisited the ED within 12 hours, complaining of excruciating low back pain radiating to both legs, and difficulty in micturition. Physical examination was notable for a positive Straight Leg Raise (SLR) test in the right leg, with right foot drop, and diminished



**Fig. 1:** lateral x-ray of the lumbo-sacral spine showing straightening (loss of natural lumbar lordosis).

sensation in the right leg below the level of the knee (corresponding to L3 level of dermatome). Sensation was also diminished to a lesser extent in the left leg, also corresponding to the L3 dermatome. There was no saddle anaesthesia, and rectal tone was preserved. The urinary bladder was palpable and 600 ml of urine was drained on Foley's catheterization.

A clinical diagnosis of Cauda Equina Syndrome was made, and an urgent magnetic resonance imaging of the lumbo-sacral spine was performed (Fig. 2, 3) which revealed a large right para-central herniation of the L4-L5 disc indenting the right L5

nerve root, and sacralisation of the L5 vertebra. An urgent neurosurgical consult was sought in the ED, and the patient was advised urgent surgical decompression.

### Differential Diagnosis

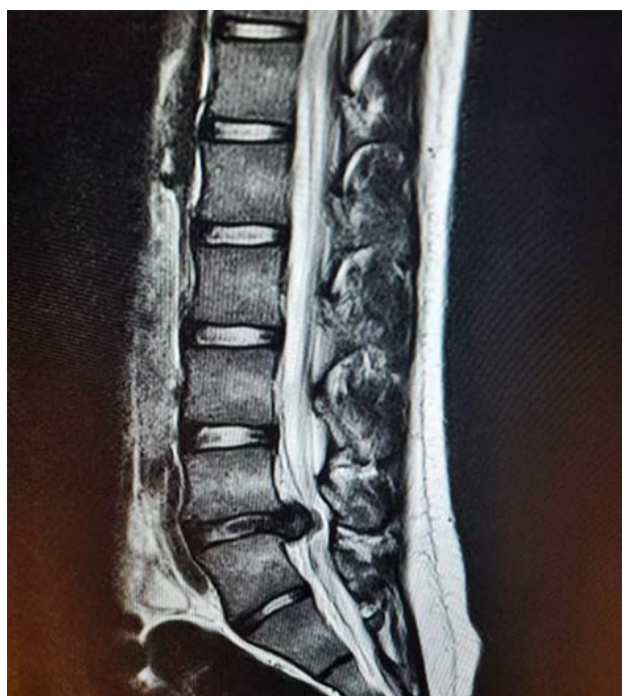Cauda Equina Syndrome, with varying etiology as below:

- Infection (Pott's spine)
- Malignancy (multiple myeloma or spinal metastasis)
- Spinal epidural hematoma/abscess
- Spinal canal stenosis

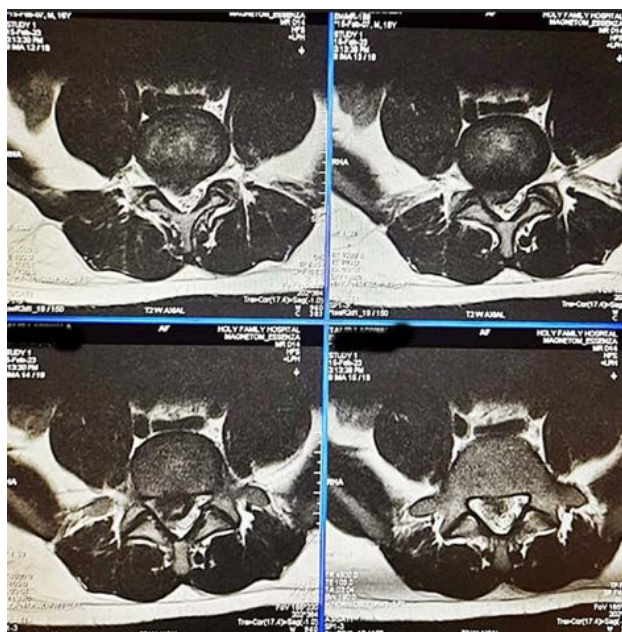
### Treatment and Outcome

The patient underwent urgent surgical decompression with laminectomy and discectomy the same evening, and had a favourable outcome with full neurological recovery.

A rapid diagnosis by the Emergency Physician, and prompt surgical decompression by the Neurosurgeon saved the day for this adolescent.



**Fig. 2:** T1 weighted mid-sagittal view of the lumbo-sacral spine showing L4-L5 disc herniation resulting in spinal cord compression. Sacralisation of L5 vertebra is also noted.



**Fig. 3:** T2-weighted axial view showing a large right paracentral disc herniation at L4-L5 indenting the right L5 nerve root.

## DISCUSSION

Low back pain is a common complaint in adults of all ages, and is now being increasingly seen in adolescents and children.<sup>6</sup> The etiology of low back pain is either muscular, bone related or discogenic.

Disc herniation is a common disorder in adults with degenerated intervertebral discs, with a lifetime occurrence as high as 40%.<sup>7</sup> However, its occurrence in adolescence is much less frequent at 3-8 %<sup>8</sup>, as adolescents tend to have a healthier lumbar spine.<sup>9,10</sup>

The most common cause of back pain in adolescents is muscular.<sup>11</sup> Muscular pain tends to be localised to the paraspinal muscles of the thoracic or lumbar region than over the spine itself. This type of pain is mostly related to overuse (example: lifting a heavy rucksack, improper positioning of a bicycle seat), although there may be a history of acute injury.

Bony pain tends to occur at the centre of the spine, and tends to be exacerbated with extension of the spine, although this finding is not specific. Causes include spondylolysis, spondylolysis thesis, adolescent idiopathic scoliosis, juvenile kyphosis.

Disc-related pain is generally exacerbated by flexion, and may be radiating in nature. Discogenic back pain may be due to disc herniation, degenerative disease, trauma, or sports activities. Approximately 10% of persistent back pain in adolescents is disc related.<sup>12</sup>

Cauda Equina Syndrome is seen in about 0.08% cases of low back pain presenting to primary care,<sup>5</sup> making it an extremely uncommon diagnosis. Low back pain in adolescents is itself not a common presentation in the ED, and when present, is generally benign in nature (most often muscular). Moreover, lumbar vertebrae herniation is extremely uncommon in the paediatric/adolescent



age group, and Cauda Equina as a consequence of it, is even rarer. This is what makes the diagnosis of Cauda Equina in adolescents so challenging, and often leads to a delay in diagnosis, which can lead to significant morbidity.

It is therefore of paramount importance that the Emergency Physician be aware of red flag signs in low back pain, such as night pain, persistent back pain beyond 6 weeks, pain associated with fever or weight loss, pain associated with radiculopathy with bladder or bowel involvement. History is a crucial aspect of examination, especially in early presentations. It has been noted that a combination of recent loss of bladder control and recent loss of bowel control has a specificity of 97.4%<sup>13</sup> in the diagnosis of CES.

Early surgical decompression tends to have a favourable outcome. However, outcome largely depends on the severity and duration of nerve compression prior to surgery. The most common factor identified as a predictor of favourable outcome in Cauda Equina Syndrome was early diagnosis,<sup>2</sup> which reinforces the role of the Emergency Physician in picking up the pathology.

## CONCLUSION

Most cases of low back pain seen in adolescents are benign, although a few can have a serious underlying pathology. Cauda Equina Syndrome, though quite uncommon in the adolescent age group, requires a high index of suspicion to ensure prompt diagnosis in order to prevent lasting neurological deficits.

In our case, the history was negative for red flag signs, except for the persistence of pain beyond 6 weeks. However, the clinical findings were classical, and should have alerted the Emergency Physician sooner. The laxity in examination may be attributed to an extent to the low index of suspicion for a serious underlying pathology. This case reinforces the belief that history and through clinical examination in the ED are indispensable in reaching a diagnosis, and that Emergency Physicians should be well versed with uncommon sequelae of common presentations.

## REFERENCES

1. GP online. 2008. Red flag symptoms: Back pain–Musculo skeletal Disorders.
2. Kennedy JG, Soffe KE, McGrath A, Stephens MM, Walsh MG, McManus F. Predictors of outcome in caudaequina syndrome. *European Spine Journal*. 1999 Aug 1; 8(4):317-22.
3. Shapiro S. Caudaequina syndrome secondary to lumbar disc herniation. *Neurosurgery*. 1993 May. 32(5):743-6; discussion 746-7.
4. Kostuik JP, Harrington I, Alexander D, Rand W, Evans D. Caudaequina syndrome and lumbar disc herniation. *J Bone Joint Surg Am*. 1986 Mar. 68(3):386-91.
5. Hoeritzauer I, Wood M, Copley PC, Demetriades AK, Woodfield J. What is the incidence of caudaequina syndrome? A systematic review. *J Neurosurg Spine*. 2020 Feb 14:1-10.
6. Pellisé F, Balagué F, Rajmil L, Cedraschi C, Aguirre M, Fontecha C *et al*. Prevalence of Low Back Pain and Its Effect on Health-Related Quality of Life in Adolescents. *Archives of Pediatrics & Adolescent Medicine*. 2009; 163(1):65.
7. Frymoyer JW, Pope MH, Clements JH, Wilder DG, MacPherson B, Ashikaga T. Risk factors in low-back pain. An epidemiological survey. *J Bone Joint Surg Am*. 1983; 65:213–218.
8. Kumar R, Kumar V, Das N, Behari S, Mahapatra A. Adolescent lumbar disc disease: findings and outcome. *Childs Nerv Syst*. 2007; 23(11):1295-1299.
9. Dang L, Liu Z. A review of current treatment for lumbar disc herniation in children and adolescents. *European Spine Journal*. 2009; 19(2):205-214.
10. Haidar R, Ghanem I, Saad S, Uthman I. Lumbar disc herniation in young children. *Acta Paediatrica*. 2009.
11. Kim H, Green D. Adolescent back pain. *Current Opinion in Pediatrics*. 2008; 20(1):37-45.
12. Micheli L. Back Pain in Young Athletes. *Archives of Pediatrics; Adolescent Medicine*. 1995; 149(1):15.
13. Premkumar A, Godfrey W, Gottschalk MB, Boden SD. Red flags for low Back pain are not always really red: a prospective evaluation of the clinical utility of commonly used screening questions for low Back pain. *JBJS*. 2018 Mar 7; 100(5):368-74.
14. Hoy, D., Bain, C., Williams, G., March, L., Brooks, P., Blyth, F., Woolf, A., Vos, T. and Buchbinder, R. (2012), A systematic review of the global prevalence of low back pain. *Arthritis & Rheumatism*, 64: 2028-2037.