

0.5% Lignocaine vs 0.5% Lignocaine with Dexmedetomidine for Bier's Block: A Comparative Study

Vikas Joshi¹, Mohammed Yahya²

Author's Affiliation: ¹Assistant Professor, ²Associate Professor, Department of Anesthesiology, Mahadevappa Rampure Medical College, Kalaburagi, Karnataka 585105, India.

Corresponding Author: Mohammed Yahya, Associate Professor, Department of Anesthesiology, Mahadevappa Rampure Medical College, Kalaburagi, Karnataka 585105, India.

E-mail: dr.yahya.imran@gmail.com

How to cite this article:

Vikas Joshi, Mohammed Yahya. 0.5% Lignocaine vs 0.5% Lignocaine with Dexmedetomidine for Bier's Block: A Comparative Study. *Indian J Anesth Analg.* 2020;7(6):1259-1264.

Abstract

Background: Intravenous regional anesthesia (IVRA) was introduced into clinical practice by August Bier in 1908. This form of analgesia is ideally suited for emergencies, where patient is with full stomach or suffering from other diseases that contraindicates general anaesthesia, moreover the feasibility and simplicity of execution of this method, its effectiveness and its lack of any side effects have been gratifying. IVRA is particularly suitable for day care surgeries as it requires minimal preparation and premedication. Dexmedetomidine, a stereoisomer of medetomidine is a highly selective alpha 2 adrenergic agonist and has been shown to decrease anesthetic requirements by upto 90% and to induce analgesia in rats, volunteers and patients. The present study was designed to evaluate the quality, onset and recovery of IVRA with 0.5mcg/kg dexmedetomidine added to 3mg/kg of 0.5% lignocaine.

Methods: After institutional approval and informed consent, 60 ASA 1 and 2 volunteers, were taken into the study. In Group A 30 patients were randomly allocated to receive IVRA for upper limb with 3mg/kg for 0.5% lignocaine; in Group B 30 patients randomly received IVRA of upper limb with 3mg/kg of 0.5% lignocaine with 0.5mcg/kg Dexmedetomidine. The onset and recovery of sensory block were tested in six sites of the forearm and hand, determined by pin prick, touch and cold. The cuff was released after 45 minutes. The onset of complete motor block was also assessed and any symptoms after cuff deflation were recorded. Usual haemodynamic monitoring was used.

Results: The speed of onset of sensory and motor block was higher in Group B than in Group A ($p < 0.05$). The recovery of sensory and motor block was prolonged in Group B than in Group A ($p < 0.05$). The tourniquet pain occurred significantly later in Group B as compared to Group A. There were few incidence of bradycardia in Group B.

Conclusion: Addition of 0.5mcg/kg of Dexmedetomidine as an adjuvant to Bier's Block effectively enhances the anesthesia and post-operative analgesia obtained with lignocaine. The low dose of Dexmedetomidine was effective and did not cause any major side-effects.

Keywords: Bier's block; Intravenous Regional Anesthesia; Local Anesthetic: Lignocaine Hydrochloride; α -2 agonist: Dexmedetomidine.

Introduction

Dexmedetomidine is a new generation highly selective α 2-adrenergic receptor (α 2-AR) agonist that is associated with sedative and analgesic

sparing effects, reduced delirium and agitation, perioperative sympatholysis, cardiovascular stabilizing effects, and preservation of respiratory function.^{1,2} It has been used successfully in combination with local anaesthetics for procedures



like spinal, epidural and brachial blocks.³ The present study was designed to evaluate the quality, onset and recovery of IVRA with 0.5mcg/kg Dexmedetomidine added to 3mg/kg of 0.5% lignocaine.

Materials and Methods

The present study was designed to compare and evaluate the quality and onset of intravenous regional anaesthesia in the upper limb with dexmedetomidine added to lignocaine. Based on the findings of previous studies by M Bala Muruganet al⁴, Esha et al⁵ and Nitin Purohit et al⁶, sample size of 60 patients was taken belonging to either sex and age between 18 and 65 years. All the patients belonged to ASA (American Society of Anesthesiologist) grade 1 or 2. Computer based Randomisation was done and divided into two groups of 30 patients each:

Group A: 0.5% lignocaine 3mg/kg

Group B: 0.5% lignocaine 3mg/kg + dexmedetomidine 0.5mcg/kg.

Detailed history was taken and complete clinical examination was done to exclude patients with history of epilepsy, hypersensitivity to local anesthetics, neurological, cardiac and hemolytic diseases. Routine investigations like blood grouping, haemoglobin, blood urea and blood sugar were done. ECG whenever indicated was undertaken to rule out the presence of any cardiac disease. Pre-operative temperature, pulse rate, respiratory rate, blood pressure and condition of heart and lungs noted. Patient's weight was recorded.

Written and informed consent was taken prior to scheduled operation. Patients were explained about the procedure of intravenous regional anesthesia. Patients with Raynauds disease, sickle cell anemia were excluded from the study.

An 18 G intravenous cannula was inserted into a vein of the non-operated limb for the purpose of administering fluids or drugs. Another 22 G cannula was inserted into suitable vein on dorsum of hand that was to be operated as distally as possible and firmly secured.

Tourniquet: Cotton padding was placed on the proximal part of the limb to be operated. Double tourniquets were set up and connected to pneumatic pressure gauge.

The occlusion pressure i.e the pressure at which pulse disappears was noted for each tourniquet.

Exsanguinating the extremity: The arm to be operated is elevated to 90° angle from the body above the level of heart for 5 minutes to drain the blood from the limb. Esmarch bandage was wrapped tightly around the arm from the most distal part to near the pneumatic tourniquet to further exsanguinate. The proximal cuff was inflated to 100mmHg higher than the occlusion pressure and esmarch bandage removed.

Injecting the anesthetic solution: The limb was placed horizontally and local anesthetic was injected steadily.

Group A patients received solution containing 0.5% lignocaine 3mg/kg.

Group B patients received solution containing 0.5% lignocaine 3mg/kg and dexmedetomidine 0.5mcg/kg.

After injection IV cannula was removed and pressure was applied to venepuncture site for some time till bleeding stops. The following parameters were observed and recorded continuously throughout the surgical procedure: Pulse rate, Blood pressure, Respiratory rate, Level of consciousness.

The following parameters were noted: Tourniquet time, Grade of analgesia, Complications arising intraoperatively and postoperatively.

Assessment of block: Six areas supplied by radial, median and ulnar nerves were tested in sequence with the patient unable to observe testing. At 90 second intervals after administration, the sensory block was assessed by using a 24 G needle. The patient reported verbally the sensation as pin prick, touch or absent.

Cold sensation was assessed using a cube of ice placed in sterile test tubes. Motor function was assessed by asking the patient to flex and extend his wrist and fingers.

Complete motor block was considered when no voluntary movement was possible.

Tourniquet pain: Proximal tourniquet deflated after inflating distal tourniquet once patient complains of discomfort. Then distal cuff was inflated to 250 mmHg and proximal cuff was deflated.

Tourniquet release: At the end of case/after 45mins the tourniquet was deflated using deflation and inflation technique before the cuff was let down permanently.

Monitoring after tourniquet release: The patients were monitored for any change in pulse rate, blood pressure, loss of consciousness and for any signs of

systemic toxicity like twitching, convulsions and ECG abnormalities.

Sensory assessment was continued until full recovery occurred at all six sites.

Grading of Analgesia: Method adopted was one given by R J Ware.

Grading of analgesia and muscle relaxation.

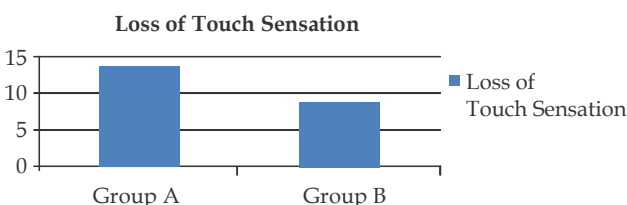
| Grade | Description |
|----------------|--|
| 1. (Excellent) | Complete analgesia and motor loss as evidenced by inability to move fingers. |
| 2. (Good) | Complete analgesia but no motor paralysis. |
| 3. (Fair) | Loss of pain sensation but discomfort to deep pressure still present. |
| 4. (Partial) | Only partial and patchy analgesia, requiring supplementation. |
| 5. (Poor) | No analgesia at all, requiring general anesthesia. |

Descriptive and inferential statistical analysis has been carried out in the present study. The results were analysed by using SPSS version 18 (IBM Corporation, SPSS Inc., Chicago, IL, USA). Results on continuous measurements were presented on Mean±SD (Min-Max). Significance was assessed at 5% level of significance. Normality of the data was assessed using Shapiro Wilk test. Independent t test and Chi- square test were used to find the significant difference of study parameters between the groups.

Results

There was no significant difference in age and gender distribution between the groups i.e both the groups were homogeneous.

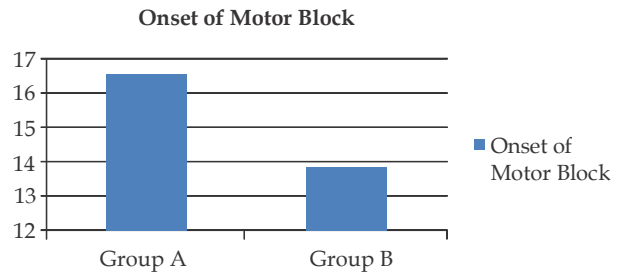
There is statistically significant difference between the groups with Group A having higher values (14.1±2.9 min vs 8.8±1.2 min) (Graph 1).



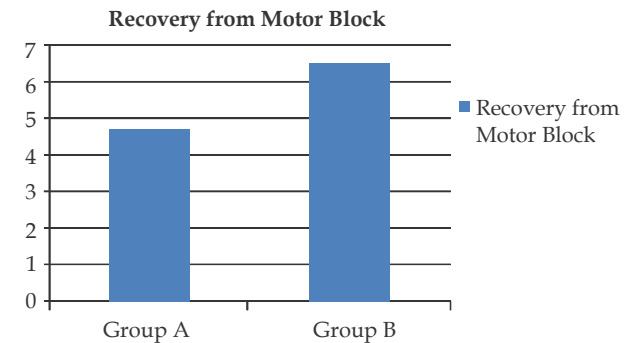
Graph 1: Loss of touch sensation.

There is statistically significant difference between the groups with Group A having higher values (16.6±2.1 min vs 13.9±1.9 min) (Graph 2).

There is statistically significant difference between the groups with Group B having higher values (4.8±0.9 min vs 6.4±1.2 min) (Graph 3).

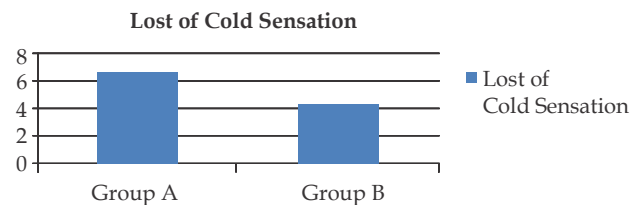


Graph 2: Onset of motor block.



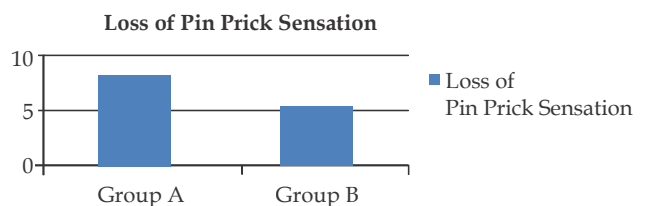
Graph 3: Recovery from motor block.

There was statistically significant difference between the groups with Group A having higher values (6.6±1.4 min vs 4.3±0.9 min) (Graph 4).



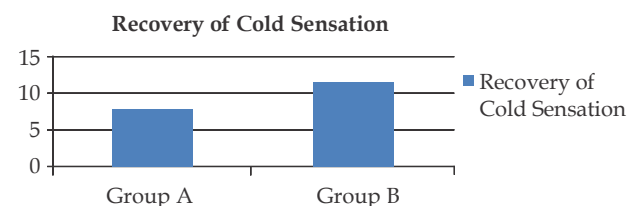
Graph 4: Loss of cold sensation.

There is statistically significant difference between the groups with Group A having higher values (8.5±1.5 min vs 5.4±1.2 min) (Graph 5).



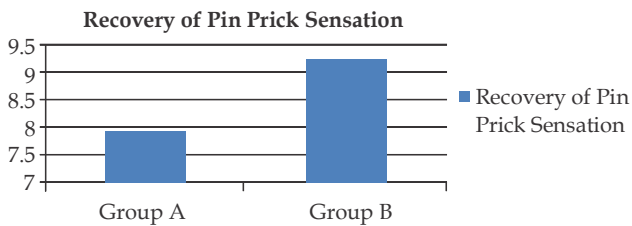
Graph 5: Loss of pin prick sensation.

There is statistically significant difference between the groups with Group B having higher values (8.3±1.4 min vs 11.4±1.4 min) (Graph 6).



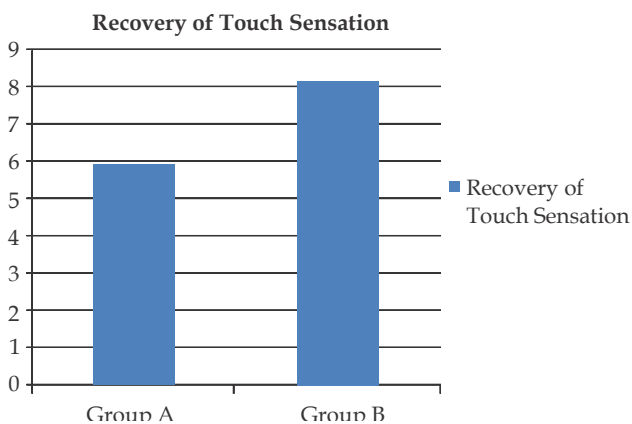
Graph 6: Recovery of cold sensation.

There is statistically significant difference between the groups with Group B having higher values (7.9 ± 1.2 min vs 9.3 ± 1.4 min) (Graph 7).



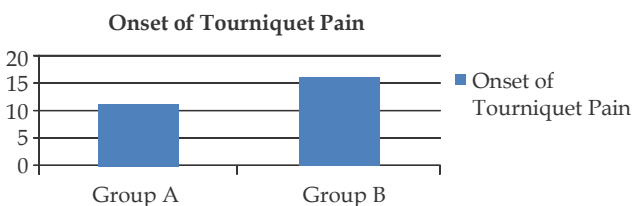
Graph 7: Recovery of pin prick sensation.

There was statistically significant difference between the groups with Group B having higher values (5.9 ± 1.4 min vs 8.2 ± 0.9 min) (Graph 8).



Graph 8: Recovery of touch sensation.

There is statistically significant difference between the groups with Group B having higher values (11.3 ± 3.5 min vs 16.9 ± 2.8 min) (Graph 9).



Graph 9: Onset of tourniquet pain.

Discussion

IVRA technique is widely used for surgery on arms. IVRA is safe and problems are few. The advantages of IVRA are high indices of reliability, rapid onset of analgesia within 5–10 minutes and good muscular relaxation. The disadvantage of IVRA is the application of a tourniquet, which must remain inflated continuously throughout the procedure. The duration of surgery is limited by the time during which the arterial tourniquet could be kept safely inflated. Tourniquet pain, which is described as a dull and aching pain sensation, is a well-known

limitation of IVRA. Skin compression, tourniquet size, and inflation pressure have been implicated as factors involved in tourniquet pain. Another drawback with this technique is the absence of postoperative analgesia. In several studies it was tried to find a local anesthesia mixture that allows relief from tourniquet pain and prolonged duration of analgesia after tourniquet release. Non-steroidal anti-inflammatory drugs, opioids, and combination of opioid and muscle relaxant have been used without demonstrating clear advantage.⁷

Dexmedetomidine is approximately eight times more selective toward the α_2 -adrenoceptors than clonidine.⁸ Centrally active α -adrenergic agonists exert powerful analgesic action that probably is transduced at several levels. Dexmedetomidine has been shown to enhance the local anesthetic action of lignocaine via α_2A adrenoceptor.⁹ Perioperative dexmedetomidine administration decreases the requirements for opioid or non-opioid analgesics both intra and postoperatively.¹⁰

Addition of dexmedetomidine to prilocaine in IVRA decreases pain scores, improves anesthesia quality, decreases analgesic requirement, shortens sensory block onset time, and prolongs sensory block recovery time.^{2,11,12} Addition of dexmedetomidine to lignocaine in IVRA also improves the quality of anesthesia and decreases the analgesic requirements but has no effect on the sensory and motor block onset and regression time.² Our study demonstrated that the addition of dexmedetomidine, in dose of 0.5mcg/kg of body weight, to lignocaine for IVRA not only improved quality of anesthesia and postoperative analgesia without causing significant side effects but also shortened the onset of sensory and motor block as compared to placebo.

Memis et al¹² in the year 2004 achieved IVRA using 0.5% lignocaine 3mg/kg with saline in control group and 0.5% lignocaine 3mg/kg with 0.5mcg/kg dexmedetomidine in study group. Based on this we used 0.5mcg/kg dexmedetomidine with lignocaine in the present study.

Exsanguination: John Mabee et al¹³ showed that while esmarch was most effective exsanguination method, arm elevation or arterial compression also were effective. Hence in our study, first gravitational drainage was done followed by esmarch bandage application.

Dose Selection: In our study, Group A received 0.5% lignocaine 3mg/kg and Group B received 0.5% lignocaine 3mg/kg with dexmedetomidine 0.5mcg/kg.

Similarly Dilek Memiset al⁴ used 0.5% lignocaine 3mg/kg diluted to 40 ml in lignocaine group and 0.5% lignocaine 3mg/kg with dexmedetomidine 0.5mcg/kg diluted to 40 ml in dexmedetomidine group. The present study showed significant reduction of onset of sensory and motor block in Group B. Sensory and motor block recovery times were also statistically prolonged in this group (p<0.05), compared to Group A.

| | Dilek Memis et al ⁴ | This study |
|----------------------------------|--------------------------------|------------|
| Sensory block onset time (min) | 5± 2 | 5.4 |
| Sensory block recovery time(min) | 7±3 | 8.2 |
| Motor block onset time(min) | 10±4 | 13.9 |
| Motor block recovery time(min) | 8±3 | 6.4 |
| Initial time of tourniquet pain | 53±10 | 16.9 |

Toxicity Reaction: The complications of IVRA usually are caused by the systemic toxicity of the agent used. Brown and coworkers¹⁴ in their 20 years experience described IVRA without mortality and morbidity.

Dunbar and Mazze found no arrhythmias and only a slight drop in blood pressure or slight bradycardia on release of the tourniquet.¹⁵

Kennedy and co workers in their patients found a 15% incidence of ECG changes and recorded one cardiac arrest that was preceded by bradycardia.¹⁶ They felt that smaller the dose and greater the injection release interval, the chances of toxic reactions were rare.

In our study there were no significant changes in heart rate or ECG. Mild transient giddiness occurred in 2 patients of either Group.

Blood Levels: Mazze and co-workers reported a blood level of 1.5mcg/ml following 3mg/kg of 0.5% lignocaine.¹⁵

Hargrove and co-workers found that maximum levels of local anesthetic in venous blood from other arm did not exceed 2mcg/ml.¹⁷

In our study we could not estimate blood levels due to lack of facilities.

Complications related to the use of tourniquet: A study reviewed an estimated 6,30,000 tourniquet application found an incidence of peripheral nerve damage of 1 in 80,000. The incidence was higher in procedures involving the upper limb than in those involving lower limb. The tourniquet time varied from 20 minutes to 2½ hours.

Dilek Memiset al¹² found that addition of dexmedetomidine found significant reduction in tourniquet and post-operative pain during IVRA.

In our study there were no complications related to the use of tourniquet and also it was found that addition of dexmedetomidine reduced tourniquet pain during IVRA.

Conclusion

Addition of 0.5mcg/kg of Dexmedetomidine as an adjuvant to IVRA effectively enhances the anaesthesia and post-operative analgesia.

Conflict of interests: Nil

References

- Gorgias NK, Maidatsi PG, Kyriakidis AM, Karakoulas KA, Alvanos DN, Giala MM. Clonidine versus ketamine to prevent tourniquet pain during intravenous regional anaesthesia with lignocaine. *Reg Anesth Pain Med* 2001;26:512-7.
- Manpreet kaur and P. M. Singh. *Anesth Essays Res.* 2011 Jul-Dec; 5(2): 128-133:447-51.
- Esmaoglu A, Mizrak A, Akin A, Turk Y, Boyaci A. Addition of dexmedetomidine to lignocaine for intravenous regional anaesthesia 1. 2005, June;22(6) 3 Current role of dexmedetomidine in clinical anesthesia and intensive care.
- Balamurugan M, Shanmugasundaram M, Kavitha R. Comparison between 0.5 µg/kg Dexmedetomidine with 0.5% Lignocaine and 0.5% Lignocaine Alone in Intravenous Regional Anesthesia for Forearm Surgeries: A Randomized Controlled Study. *Int J Sci Stud* 2016;4(3):1-5.
- Esha Nilekani et al., A Study on the Efficacy of the Addition of Low Dose Dexmedetomidine as an Adjuvant to Lignocaine in IVRA. *Journal of Clinical and Diagnostic Research.* 2016 Oct, Vol-10(10).
- Purohit N, Patil P, Mishra M et. al. To compare the effects of lignocaine versus lignocaine with dexmedetomidine in bier's block: a prospective double blinded study. *Int J Health Sci Res.* 2015; 5(3):75-81.
- Choyce A, Peng P. A systematic review of adjuncts for intravenous regional anesthesia for surgical procedures. *Can J Anaesth* 2002;49:32-45.
- Kalso EA, Po'yhia R, Rosenberg PH. Spinal antinociception by dexmedetomidine, a highly selective α2-adrenergic agonist. *Pharmacol Toxicol* 1991;68:140-3.
- Yoshitomi T, Kohjitani A. Dexmedetomidine enhances the Local Anesthetic action of Lignocaine via an α2A adrenoceptor. *Anesth Analg* 2008;107: 96-101.
- Mizrak A, Gul R, Erkutlu I, Alptekin M, Oner U. Premedication with Dexmedetomidine alone or

- together with 0.5% Lignocaine for IVRA. *J Surg Res.*2010;164:242-7.
11. Scheinin H, Jaakola ML, Sjövall S, Ali-Melkkilä T, Kaukinen S, Turunen J, et al. Intramuscular dexmedetomidine as premedication for general anesthesia. *Anesthesiology* 1993;78:1065-75.
 12. Memis D, Turan A, Karamanlioglu B, et al. Adding dexmedetomidine to lignocaine for intravenous regional anaesthesia *Anesth Analg* 2004;98(3): 835-40.
 13. John Mabee, Michael Orlinsky. A volumetric omparison and venous pressure study. *Academic emergency medicine* 2000;7:105-113.
 14. Brown EM, Mcgriff JT, Maliinowski RW. Intravenous regional anaesthesia (Bier block): review of 20 years' experience. *Can J Anaesth* 1989;36(3 Pt 1):307-10.
 15. Mazze RL, Dunbar RW. Plasma lidocaine concentrations after caudal, lumbar epidural, axillary block and intravenous regional anaesthesia. *Anaesthesiology* 1966;27(5):574-9.
 16. Kennedy BR, Dutthie AM, Parbrook GD, et al. Intravenous regional anaesthesia: an appraisal. *Br Med J* 1965;1(5440):954-7.
 17. Hargrove RL, Hoyle JR, Parker JB, et al. Blood lignocaine level following intravenous regional analgesia. *Anaesthesiology* 1966;21(1):37-41.
-
-