

## Malignant Intracerebral Nerve Sheath Tumor: A Rare Case Report

Sarthak Moharir<sup>1</sup>, Shashank Singh<sup>2</sup>, Virendra Bhandari<sup>3</sup>, Anil Sarolkar<sup>4</sup>

**Author's Affiliation:** <sup>1</sup>Registrar, <sup>2</sup>Professor, <sup>3</sup>Associate Professor, Department of Radiation Oncology, Sri Aurobindo Medical College & PG Institute, Indore, Madhya Pradesh 453555, India.

**Corresponding Author:** Virendra Bhandari, Professor, Department of Radiation Oncology, Sri Aurobindo Medical College & PG Institute, Indore, Madhya Pradesh 453555, India.

**E-mail:** [virencancer@yahoo.co.in](mailto:virencancer@yahoo.co.in)

**Received on** 29.04.2019, **Accepted on** 20.06.2019

### Abstract

Malignant peripheral nerve sheath tumours are very uncommon and can be found associated with neurofibromatosis Type I. Their prognosis is poor and surgery remains the treatment of choice. Radiotherapy and chemotherapy are second and third line of treatment. The diagnosis is based on clinical, radiological, histological and immunohistochemical tests. Malignant peripheral nerve sheath tumour have a very high potential of local recurrence and can even metastasize. They often occur in extremities but rarely can occur in brain. Very few cases have been reported in brain till date in the literature. We present here a case report of such a patient confirmed histologically and who had a residual disease post treatment.

**Keywords:** Intracerebral tumor; Rare case.

### How to cite this article:

Sarthak Moharir, Shashank Singh, Virendra Bhandari, *et al.* Malignant Intracerebral Nerve Sheath Tumor: A Rare Case Report. Indian J Canc Educ Res. 2019;7(2):113-116.

### Case Report

A 36 year old male developed headache sudden in onset and throbbing in nature. A contrast-enhanced MRI Brain was done which revealed a 5.3 × 7.4 × 6.2 cm mixed solid-cystic mass lesion in right parieto-occipital lobe, the solid component was of lesion appears mildly hyperintense on T-2 and Flair, isointense on T1W1 and shows mild diffusion restriction. The cystic component appears hyperintense on T2 with partial suppression of signals on FLAIR and presence of thick internal septa. On post-contrast study the lesion shows heterogeneous enhancement. The lesion is abutting the posterior aspect of superior sagittal sinus without invasion. Mild perilesional edema is noted adjacent to the lesion, with mass affect over the left posterior interhemispheric fissure, compression of left lateral ventricle and midline shift of 1cm towards the left with descending transtentorial

herniation suggestive of low grade astrocytoma or oligodendrioglioma in the right parieto-occipital lobes (Fig. 1 & 2). Patient underwent right parieto-occipital craniotomy with excision of parietal SOL with occipital SOL with duroplasty, the post operative period was uneventful, and there were no post op neurological deficits. Histopathological examination of the operated spicemen showed proliferation of elongated to spindly tumor cells with indistinct cytoplasmic border. The tumor is hypercellular, forming fascicles and nested pattern. The nuclei are pale and elongated with moderate nuclear pleomorphism. Some of the cells have foamy/xanthomatous cytoplasm, while at places they show perinuclear vacuolated appearances. There are presence of pleomorphic mono or multinucleated cells with nuclear inclusion and occasional cytoplasmic xanthomatous change. Perivascular lymphocytic cuffing is seen, the mitosis seen are upto 5/10 high power field, there is no evidence of microvascular proliferation/



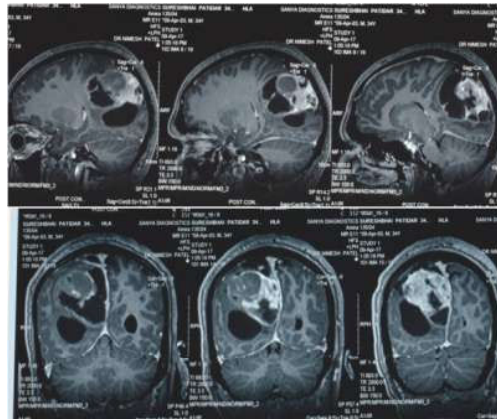


Fig. 1:

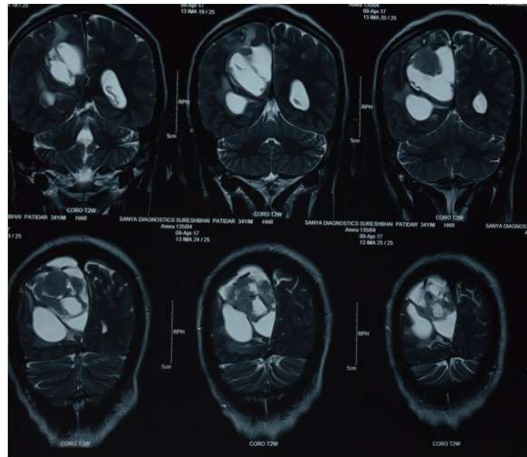


Fig. 2:

necrosis in tumor. The tissue was reported as a glial tumor, showing features suggestive of Pleomorphic Xanthoastrocytoma with some anaplastic features (WHO Grade II). The specimen was subjected to immunohistochemistry examination in which the section shows the structure of a high grade malignant tumour with epitheloid and spindle cell morphology. The tumor cells are arranged in irregular fascicles. The epitheloid component showed nesting pattern. Capillary sized blood vessels and larger vessels with hyalinization are plentiful in the lesion. Focal areas of coagulative necrosis are identified. There is increased mitotic activity, up to 15 per 10 high power field, there is marked cytological atypia. Focal deposits of eosinophilic hyaline material is noted, occasional areas show palisading tumour cells which are diffusely and intensely express S100, very few cells express EMA in much weaker fashion, occasional cells express GFAP, tumour cells do not express CD-34. The described features are those

of an epitheloid malignant peripheral nerve sheath tumour (MPNST). It is high grade sarcoma with nerve sheath differentiation (Fig. 3).

After surgery, patient received radiotherapy on Linear accelerator with 6 MV Photons by 3 DCRT technique to a total dose of 54 Gy in 30 fractions in 5 weeks. The three months post treatment MRI scan was suggestive of a heterogeneously enhancing mass, extra-axial and parafalcine in origin.  $2.1 \times 5 \times 4.0$  cm. Appears inseparable with superior sagittal sinus posteriorly without luminal invasion. Marked vasogenic edema and mass effect extending upto the suprasplenic parenchyma. Non enhancing eccentrically placed paramedian cystic lesion approx. 2 cms in diameter with small perifocal gliosis with no enhancement on post contrast scan. Focal left thickening and enhancement is seen in right temporoparietal region appreciated on T1 and FLAIR images. This showed residual tumor. He was advised further chemotherapy but was then lost to follow up.

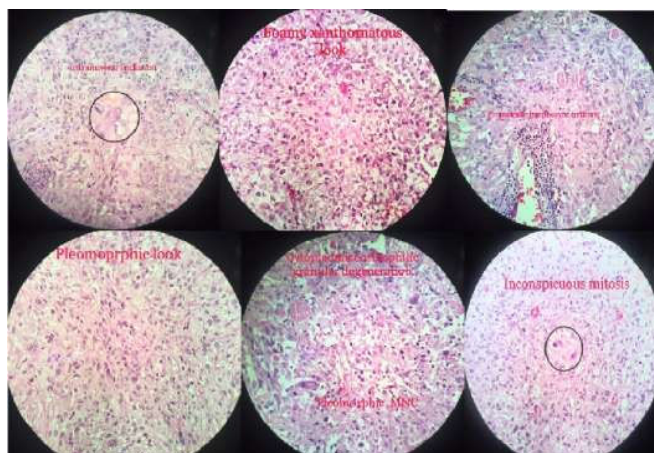


Fig. 3:

### Discussion

Nerve sheath tumors within the neuraxis is uncommon. Cellular origin is uncertain. Some authors suggest schwann cells of perivascular nerves, others, pleuripotent mesenchymal cells.<sup>1,2</sup> Finding them within the cerebral parenchyma is rarer. Macroscopically these tumors are well circumscribed with cystic component in them. Histologically features included marked cellular pleomorphism with giant cells, bizarre nuclei, variable cytoplasmic lipidization. The diagnosis of MINST can be difficult and necessitates a thorough investigation of clinical findings, imaging features, and histopathology along with IHC.<sup>3</sup> Termed, Malignant Intracerebral nerve sheath tumours (MINST), these tumours are classified as WHO grade II brain tumours.<sup>4</sup> They are uncommon in the general population, but their incidence is 8-13% in NF1 patients. It is also common in patients previously exposed to ionizing radiation. MINST has replaced the term malignant schwannomas, as schwannomas have no propensity for malignant change. These tumours frequently recur, and are aggressive malignant tumours with infiltrative capacity, presenting as ICSOLs can mimic gliomas. Survival influenced by: tumour location, size and association with NF1.<sup>5</sup> Survival remains poor, due to their invasive nature and ability to metastasize to other organs. Sharma *et al.* point out that the earlier the first recurrence, the worse the overall survival.<sup>6</sup> Only 15 documented cases of MINST exist in literature. Although definite guidelines do not exist, the standard of care is Gross total resection, followed by radiation therapy±chemotherapy.<sup>7</sup> Close and frequent follow-up is required to detect

recurrences. Awareness of this tumour, extensive surgical extirpation and thorough histopathological examination serve as essential components in management. The following case further highlights the importance and relevance of the 2016 update of WHO classification of CNS malignancies, where IHC studies are essential and indispensable part of setting up the diagnosis of a CNS malignancy.

### Conclusion

Malignant peripheral nerve sheath tumours are very uncommon tumor. Surgery remains the primary treatment. The survival remains poor as the chances of recurrence are very high. So a continuous monitoring is a must and this diagnosis should be kept in mind if a patient is suffering from neurofibromatosis.

Sources of support: NIL

Ethical Issues: NIL

Conflicting Interest: NIL

### References

1. Beauchesne P, Mosnier JF, Schmitt T. Malignant nerve sheath tumor of the right cerebral peduncle: case report. *Neurosurgery*. 2004;54(2):500-504.
2. Hirose T, Sumitomo M, Kudo E. Malignant peripheral nerve sheath tumor (MPNST) showing perineurial cell differentiation. *American Journal of Surgical Pathology*. 1989;13(7):613-620.

3. Le Fevre C, Castelli J, Perrin C, *et al.* Malignant intracerebral nerve sheath tumours: Two case reports and complete review of the literature cases. *Cancer Radiotherapie.* 2016;20(2):119-132.
  4. Louis DN, Perry A, Reifenberger G, *et al.* The 2016 World Health Organization Classification of Tumors of the Central Nervous System: a summary. *Acta Neuropathol.* 2016;131(6):803-20.
  5. Tanaka M, Shibui S, Nomura K, *et al.* Malignant intracerebral nerve sheath tumor with intratumoral calcification. Case report. *Journal of Neurosurgery.* 2000;92(2):338-341.
  6. Sharma S, Abbott RI, Zagzag D. Malignant intracerebral nerve sheath tumor: a case report and review of the literature. *Cancer.* 1998;82(3):545-552.
  7. Barnard ZR, Agarwalla PK, Jeyaretna DS. Sporadic primary malignant intracerebral nerve sheath tumors: case report and literature review. *Journal of Neuro-Oncology.* 2011;104(2):605-610.
-