

Is it Really Seizure Disorder: Myasthenia Gravis Presenting as Seizure

Shebin Althaf Ali¹, Priya Govil², Aishwariya Walia³, Kishalay Datta⁴

How to cite this article:

Shebin Althaf Ali, Priya Govil, Aishwariya Walia, *et al.*/Is it Really Seizure Disorder: Myasthenia Gravis Presenting as Seizure/
Indian J Emerg Med 2023;9(2):101-103.

Abstract

The risk for seizure disorder increased in multiple autoimmune disorder. The raised pro-inflammatory cytokines and auto antibodies against the neuronal antigen may contribute in the pathogenesis of the seizure disorder. In this case report, we will discuss about a young adult presenting to the ER with seizure disorder and later found to have underlying autoimmune disease.

Keywords: Seizure; Myasthenia Gravis; Anticholinesterase enzyme; Anti-musk antibodies.

INTRODUCTION

Seizure disorder is defined as uncontrolled, abnormal electrical activity of the brain that may cause changes in the level of consciousness, behaviour, memory, or feelings.¹ Recent evidence suggests that systemic auto-immune disorders are often co-morbid with epilepsy.² There are acute symptomatic as well as unprovoked seizures reported in people with autoimmune disorders. Most seizures reported are either convulsions or focal in nature.^{3,4}

Author's Affiliation: ¹Post Graduate Trainee, ²Senior Consultant, ³Resident, ⁴Director and HOD, Emergency Medicine, Max Superspeciality Hospital, Shalimar Bagh, Delhi 110088, India.

Corresponding Author: Shebin Althaf, Post Graduate Trainee, Department of Emergency Medicine, Max Super Speciality Hospital, Shalimar Bagh, Delhi 110088, India.

E-mail: drshebinp@gmail.com

Received on: 13-02-2023

Accepted on: 08-03-2023

Myasthenia Gravis is usually characterized by muscle weakness caused by auto-antibodies against the proteins of the neuromuscular junction. The association between MG and seizure occurrence is still controversial. One study has reported that nearly about 3% of people with myasthenia gravis have epilepsy episodes during lifetime.⁵ One population based study has shown that the risk of seizure disorder in myasthenia gravis was 5-fold greater than expected.⁶ The main pathogenesis is associated with high levels of cytokines^{6,7} leading to damage to the protein structure at the neuromuscular junction, but evidence is lacking whether these changes predispose to epilepsy. Alternatively, hypoxia due to respiratory failure causing CNS dysfunction or lesions may also play a vital role in the pathogenesis.

CASE

A 53 year old male patient was brought the ER with active generalized seizure disorder. Patient was managed in ER as per guidelines (seizure



This work is licensed under a Creative Commons Attribution-NonCommercial-ShareAlike 4.0.

protocol as per AHA). Patient was admitted under the care of neurologist in the critical care room. All routine lab investigations and imaging studies were done. MRI brain was done to find the cause of seizure but, failed to detect any specific changes within the cranial cavity. Patient was having recurrent seizure episodes during the stay in critical care unit (at least 1 episode per day) even when he was on antiepileptic. Laboratory investigations were done which was within normal limit. Patient had no family history of any seizure disorder or autoimmune disorder. Patient was noticed to have lethargy and weakness by the day end (before and after seizure episodes), making it difficult to find if patient was in post-ictal state or any other disorder.

Patient blood samples were sent for Anticholinesterase enzyme study, which came to be positive for *Anti-musk antibody positive*. The patient was diagnosed with Myasthenia gravis having presented with multiple seizure episodes.

Patient was started on cholinesterase inhibitor Tab Pyridostigmine and anticonvulsants were continued. Patient condition rapidly improved with setting of the seizure episodes. Patient was discharged with cholinesterase enzyme inhibitor medications and anticonvulsant.

During the follow up, patient was found to be having seizure free lifestyle and his general health also improved (subsiding of lethargy and weakness).

DISCUSSION

Myasthenia gravis presenting with seizure is very rare finding. There are very few patients presenting with seizure episode in the ER with underlying Myasthenia gravis disease. Myasthenia gravis is an autoimmune disorder in which, auto-antibodies in the body act against the acetylcholine receptor on the neuromuscular junction.

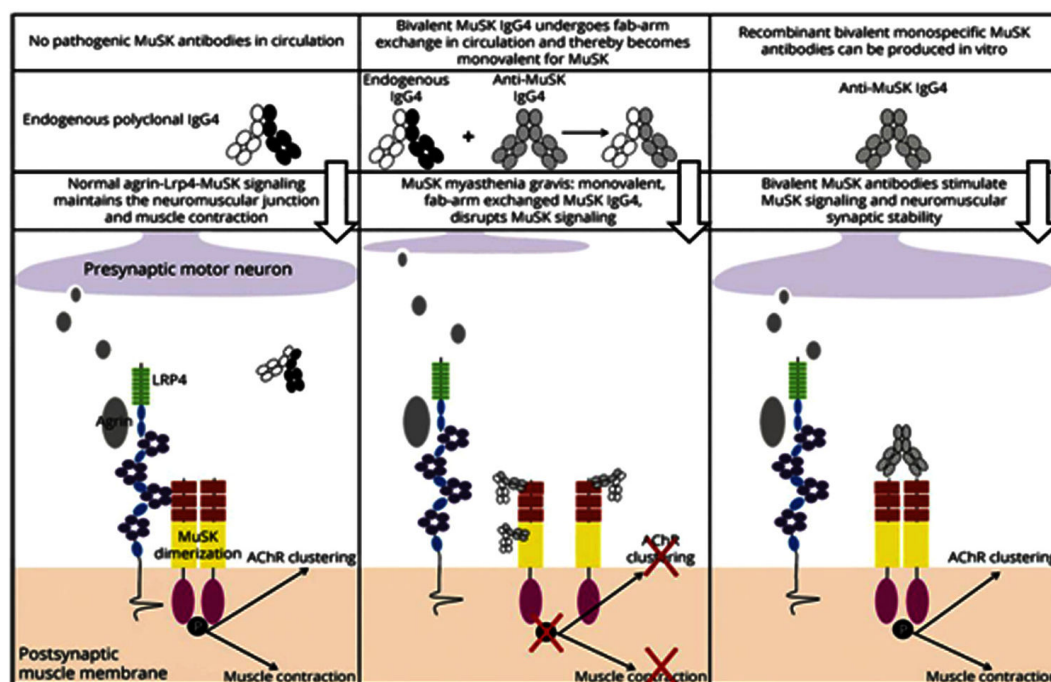


Image 1:

(Image source: Google web browser)

The cause of seizure in Myasthenia gravis is not properly understood but, it is postulated that the auto-antibodies in MG generate high levels of circulating cytokines in the patient body, leading to damage to neuronal structures of the central as well as peripheral nervous system.

Cytokines are proteins with a major role in cell signalling in the immune system. They can have both inflammatory and anti-inflammatory effects.

Interferon (IFN) α , β and γ , tumour necrosis factor (TNF) α , and high mobility group box (HMGB)¹ are examples of cytokines with pro-inflammatory effects, while fibroblast growth factor (FGF), interleukin (IL)1ra and IL10 are anti-inflammatory.⁸

In this case, the patient was managed with Anticonvulsants, Anticholinesterase enzyme inhibitors and anti-inflammatory drugs (steroids). The management of patients with seizure in

Myasthenia gravis widely depends on patient presenting illness. There are few studies in literature highlighting the treatment of seizure in myasthenia gravis. Two patients were treated with antiepileptics, one was treated with lobectomy (surgical intervention) and few others were started on anticholinesterase medications.⁹ All the treatment modalities were successful in the preventing seizure activities in MG patients. This presentation (seizure in MG) is rare entity and thus, proper guidelines as not available for treatment for the management.

CONCLUSION

Seizure presenting with underlying myasthenia gravis disorder is a rare entity and not easily diagnosed by both, Emergency physician and Neurologist. All possible causes for seizure disorder must be ruled out before performing higher special investigations for diagnosis autoimmune disease (like Myasthenia gravis). There is not proper guideline for the management, all patients must be managed with anticholinesterase enzymes inhibitors, anticonvulsants, anti-inflammatory enzymes. More literature articles are required further knowledge in this aspect of medicine.

REFERENCES

1. Fisher RS, Acevedo C, Arzimanoglou A, Bogacz A, Cross JH, Elger CE, Engel J, Forsgren L, French JA, Glynn M, Hesdorffer DC, Lee BI, Mathern GW, Moshé SL, Perucca E, Scheffer IE, Tomson T, Watanabe M, Wiebe S. ILAE official report: a practical clinical definition of epilepsy. *Epilepsia*. 2014 Apr;55(4):475-82.
2. M.R. Keezer, S.M. Sisodiya, J.W. Sander. Comorbidities of epilepsy: current concepts and future perspectives. *Lancet Neurol*, 15 (2016), pp. 106-115
3. A. González-Duarte, C.G. Cantú-Brito, L. Ruano-Calderón, G. García-Ramos. Clinical description of seizures in patients with systemic lupus erythematosus. *Eur Neurol*, 59 (2008), pp. 320-323
4. H. Bashiri, D. Afshari, N. Babaei, M.R. Ghadami. Celiac disease and epilepsy: the effect of gluten-free diet on seizure control. *Adv Clin Exp Med*, 25 (2016), pp. 751-754
5. P.J. Lorenzoni, R.D. Ducci, T.S. Tensini, G. Dalledone, C.S. Kay, L. de Paola, et al. Treatment of epilepsy in patients with myasthenia gravis: Is really harder than it looks? - *J Clin Neurosci*, 44 (2017), pp. 353-356
6. M.S. Ong, I.S. Kohane, T. Cai, M.P. Gorman, K.D. Mandl. Population-level evidence for an autoimmune etiology of epilepsy. *JAMA Neurol*, 71 (2014), pp. 569-574
7. A. Uzawa, N. Kawaguchi, K. Himuro, T. Kanai, S. Kuwabara. Serum cytokine and chemokine profiles in patients with myasthenia gravis. *Clin Exp Immunol*, 176 (2014), pp. 232-237
8. V. Iori, F. Frigerio, A. Vezzani. Modulation of neuronal excitability by immune mediators in epilepsy. *Curr Opin Pharmacol*, 26 (2016), pp. 118-123
9. Lorenzoni P.J. Ducci R.D.-P. Tensini T.S. Dalledone G. Kay C.S.K. de Paola L. et al. Treatment of epilepsy in patients with myasthenia gravis: is really harder than it looks?. *J Clin Neurosci*. 2017; 44: 353-356