

# A Study Coracoid Process of Scapula and its Clinical Significance

Viren Sharadkumar Sawant<sup>1</sup>, Sharadkumar Pralhad Sawant<sup>2</sup>, Shaheen Rizvi<sup>3</sup>

## How to cite this article:

Viren Sharadkumar Sawant, Sharadkumar Pralhad Sawant et. al./A Study Coracoid Process of Scapula and its Clinical Significance/Indian J Anat. 2022;11(4):121-127.

## Abstract

The coracoid process is aptly defined as the “light house of the shoulder” since an important principle of shoulder surgery is to board an approach which is lateral to the coracoid process. This is done to evade the neurovascular structures passing medially; besides, many important tendinous and ligamentous attachments are anchored here. Loss or damage of any of the structures could lead to alterations in the structure of coracoid process. Therefore, a more comprehensive study of the morphology of coracoid process is needed.

**Aim:** To study the coracoid process of scapula and its clinical significance.

**Material and Methods:** The present study was conducted on 100 dry human scapulae. Coracoglenoid shape was examined and classified into Type I - round bracket, Type II - square bracket and Type III fish hook. Morphometric parameters such as length, breadth, thickness and height, acromiocracoid and coracoglenoid distance were measured and statistical analysis was carried out.

**Results:** Type I Coracoglenoid shape was observed in maximum number of specimens. Differences observed in the morphometric parameters observed on right and left side were statistically insignificant.

**Clinical Significance:** The coracoid is involved in many surgical interventions on the glenohumeral joint, hence variant dimensions of the coracoid process are of importance for Radiologists and Orthopaedic surgeons for planning reparative procedures on the shoulder and is also useful in Forensics for gender determination.

**Conclusion:** The outcomes of the present study establish the proportions of the coracoid process which can aid in finding the suitable approaches for repair of a coracoid fracture.

**Keywords:** Coracoid Process; Scapula; Coracoglenoid Shape; Glenohumeral Joint; Radiologists; Orthopedic Surgeons; Forensics; Gender Determination; Coracoid Fracture.

**Author's Affiliation:** <sup>1</sup>Student, Volgograd State Medical University, Volgograd, Oblast 400131, Russia, <sup>2</sup>Professor and Head, <sup>3</sup>Assistant Lecturer, Department of Anatomy, K.J. Somaiya Medical College, Somaiya Ayurvihar, Eastern Express Highway, Sion, Mumbai 400022, Maharashtra, India.

**Corresponding Author: Sharadkumar Pralhad Sawant,** Student, Department of Anatomy, Volgograd State Medical University, Volgograd, Oblast, Russia 400131.

**E-mail:** virensawant46@gmail.com

**Received on:** 22.06.2022 **Accepted on:** 25.07.2022

## INTRODUCTION

The shoulder blade is called scapula but the name scapula is limited to the dorsal aspect of the bone. The ventral part of the shoulder blade is called the coracoid bone. The scapula and the coracoid bone join at the epiphyses lying superior to the glenoid fossa. The scapula proper and coracoid correspond to the ilium and ischium of the pelvic girdle while pubis corresponds a tiny bone called precoracoid which ossifies separately at the

tip of the coracoid process; it takes no part in the formation of shoulder joint. The coracoid process is a hook shaped structure project forwards and slightly laterally from the superior part of the neck of the scapula. It is often denoted as the 'lighthouse of the shoulder' by orthopaedic surgeons as many tendinous and ligamentous attachments are anchored here. The coracoacromial anatomy includes acromion, coracoacromial ligament and tip of coracoid process. The glenohumeral joint is the most mobile and unstable joint in the human body and hence the most commonly dislocated joint.<sup>1</sup> Patients with a significant glenoid bone loss remain to have a high failure rate after Bankart repair for shoulder dislocation.<sup>2</sup> A number of investigations have described glenoid reconstruction procedures using the coracoid process out of which Latarjet procedure (Coracoid transfer to the anterior glenoid) is the most common reconstruction procedure used for anteroinferior shoulder instability.<sup>3</sup> The coracoid increases the surface area of the glenoid but is inadequate in patients with bone loss of >33% of the glenoid width.<sup>4</sup> A complete morphometry is valuable in traumatic cases, surgical interventions and replacement surgeries in the shoulder region and is also useful in Forensics for gender determination. Not many studies have been conducted to record various morphometric parameters of the coracoid process.

**Aim:** To study the coracoid process of scapula and its clinical significance.

## MATERIAL AND METHODS

The present study was conducted on 100 dry human scapulae. 55 pairs belonged to male and 45 pairs belonged to female. The scapulae included in this study were free from damage and scapulae with broken edges and degenerative changes of coracoid process were excluded from the study. Coraco-glenoid space was examined and classified according to its shape into - Type I (round bracket), II (square bracket) and III (fish hook) as advocated by Gallino et al.<sup>5</sup> A digital vernier calipers with accuracy up to 0.01 mm was used to measure other morphometric parameters such as length, breadth, thickness and height, acromio coracoid and coracoglenoid distance.

The distance from anterolateral end to posteromedial end of coracoid process was taken as the maximum length.

The distance from lateral border to medial border of coracoid process was taken as the maximum breadth.

The Maximum thickness was measured in the supero-inferior direction 1cm posterior to tip of coracoid process.

The distance between supraglenoid tubercle to undersurface of coracoid process was taken as the maximum height.

The distance between supraglenoid tubercle to top of ascending portion of coracoid process was taken as the Coracoglenoid distance.

The distance between tip of the acromion process and tip of the coracoid process was taken as the Acromiocracoid distance.

Data obtained was analysed using SPSS 20 software. The Independent t-test was employed in the assessment of size and gender differences. p-value  $\leq 0.05$  was considered significant.

## RESULTS

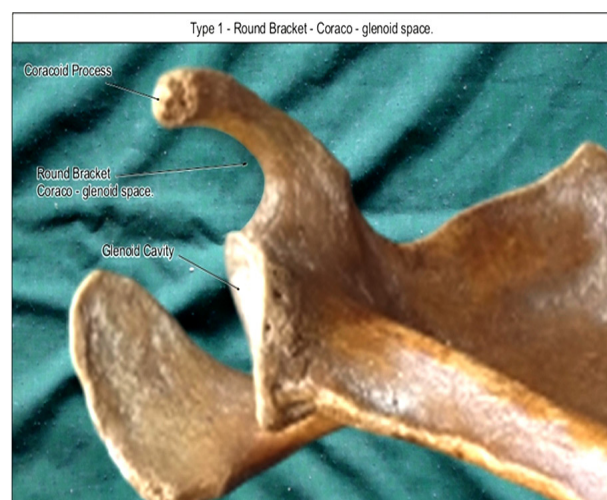Coraco-glenoid space observed were as follows

- Type I-round bracket was seen in 47specimens.
- Type II- square bracket was 33 specimens.
- Type III- fish hook was 20 specimens.

Type I was observed in maximum number of specimens followed by Type II and Type III comprised the least number

## DISCUSSION

The coracoid process is aptly defined by Matsen et al as the "lighthouse of the shoulder" since an important principle of shoulder surgery is to board an approach which is lateral to the coracoid



**Fig. 1:** showing photographic presentation of Type I - round bracket Coraco-glenoid space seen in 47specimens.

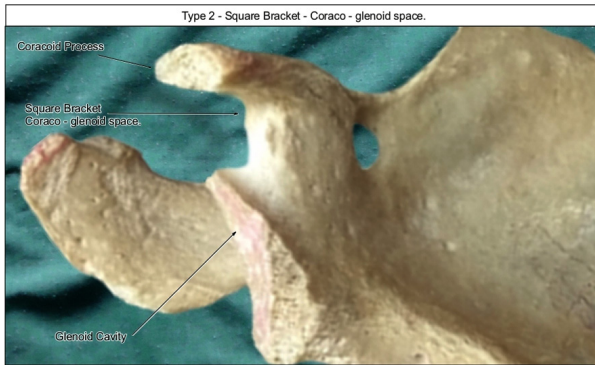


Fig. 2: showing photographic presentation of Type II - square bracket Coraco-glenoid space seen in 33specimens.

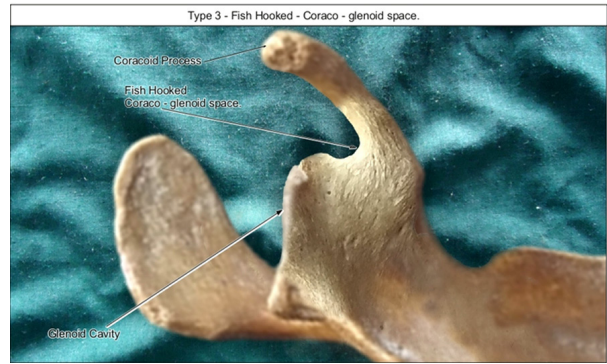


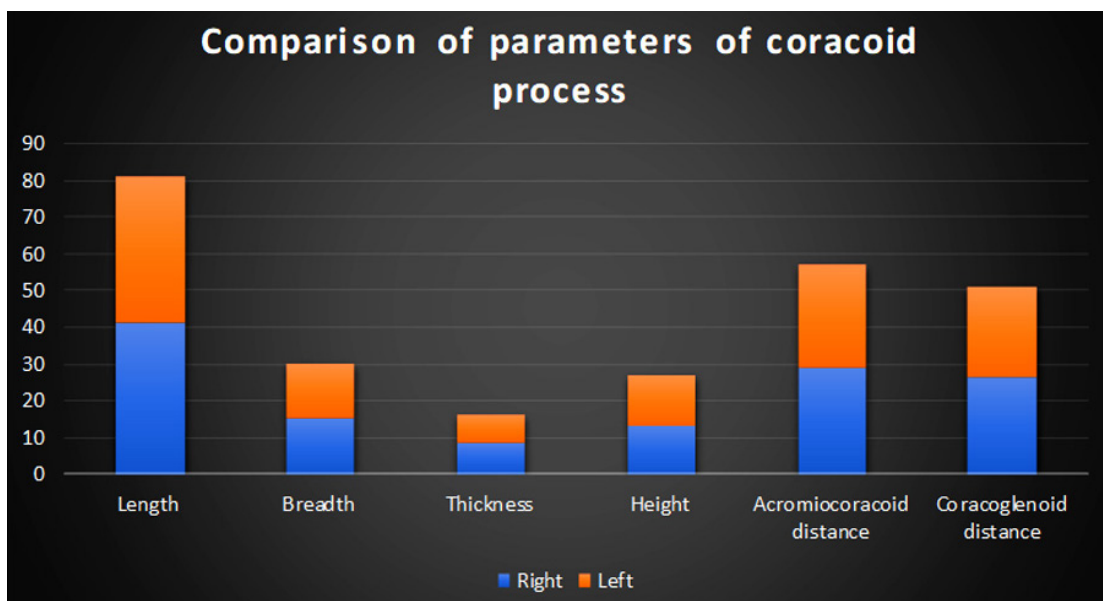
Fig. 3: showing photographic presentation of Type III - fish hook Coraco-glenoid space seen in 20 specimens.

Table 1: Comparison of Shape of Coraco-glenoid space between right and left sides.

Shape of Coraco-glenoid space	Right	Left
round bracket (n=47)	25	23
square bracket (n=33)	16	17
fish hook (n=20)	10	10

Table 2: Comparison of all the parameters between right and left sides in both males and females.

Parameter	Mean ± S. D		p-value
	Right (mm)	Left (mm)	
Length	41.21± 3.57	40.01± 3.75	0.209
Breadth	15.34 ± 1.52	14.90 ± 1.25	0.992
Thickness	8.35 ± 1.35	8.12 ± 0.87	0.506
Height	13.27±1.53	13.65±1.31	0.923
Acromiocracoid distance	28.85± 4.70	28.46± 3.62	0.872
Coracoglenoid distance	26.55 ± 3.24	24.35± 3.20	0.255






Fig. 4: showing photographic presentation of measurement of length of coracoid process.

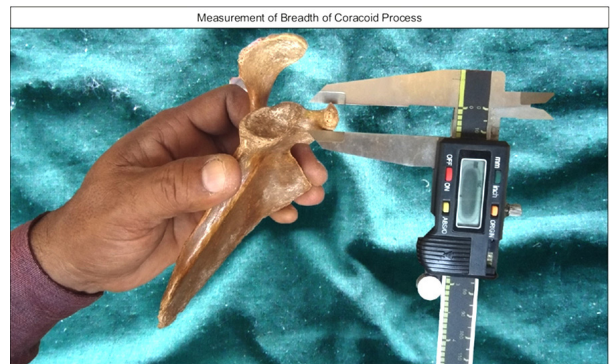

Fig. 5: showing photographic presentation of measurement of breadth of coracoid process.

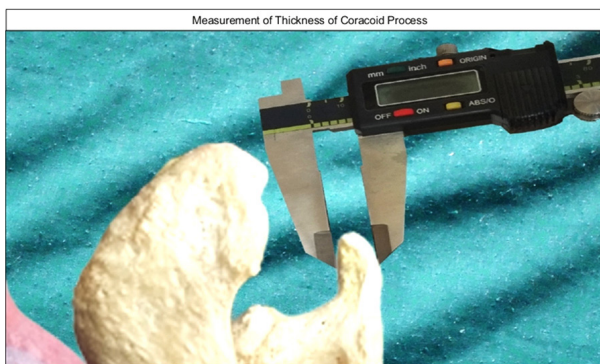


Fig. 6: showing photographic presentation of measurement of thickness of coracoid process.

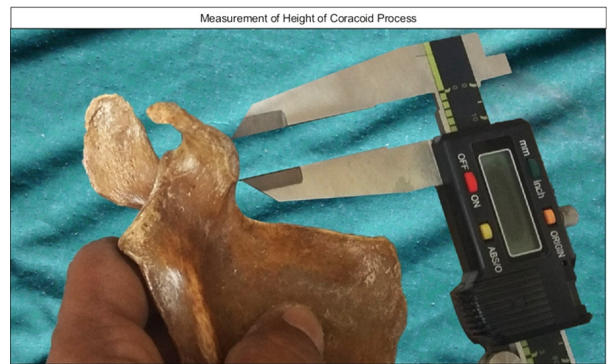

Fig. 7: showing photographic presentation of measurement of height of coracoid process.

Table 3: Comparison of parameters of coracoid process in various studies<sup>5-17</sup>

Authors	Length (mm)	Breadth (mm)	Thickness (mm)	Height (mm)
Gallino et al 1998 <sup>[5]</sup>	41.10	-	-	-
Gumina et al 1999 <sup>[6]</sup>	38.15	-	-	-
Piyawinijwong et al 2004 <sup>[7]</sup>	37.50	13.50	6.6	-
Kavita et al 2013 <sup>[8]</sup>	40.9	14.1	-	-
Pahuja and Singh 2014 <sup>[9]</sup>	41.00	-	7.40	-
Rajan et al 2014 <sup>[10]</sup>	40.43	13.77	7.03	-
Karla et al 2016 <sup>[11]</sup>	40.4	-	-	-
Fathi et al 2017 <sup>[12]</sup>	43.44	13.68	-	15.94
Verma U et al 2017 <sup>[13]</sup>	35.54	14.5	7.95	20.10
Kumar V et al 2018 <sup>[14]</sup>	40.94	13.59	8.3	-
Das SR et al 2020 <sup>[15]</sup>	39.91	14.8	8.32	22.87
Khan R et al 2020 <sup>[16]</sup>	40.94	13.59	8.3	-
Raviprasanna et al.2022 <sup>[17]</sup>	39.47	13.9	8.24	19.13
Present study	39.35	14.0	7.95	13.27

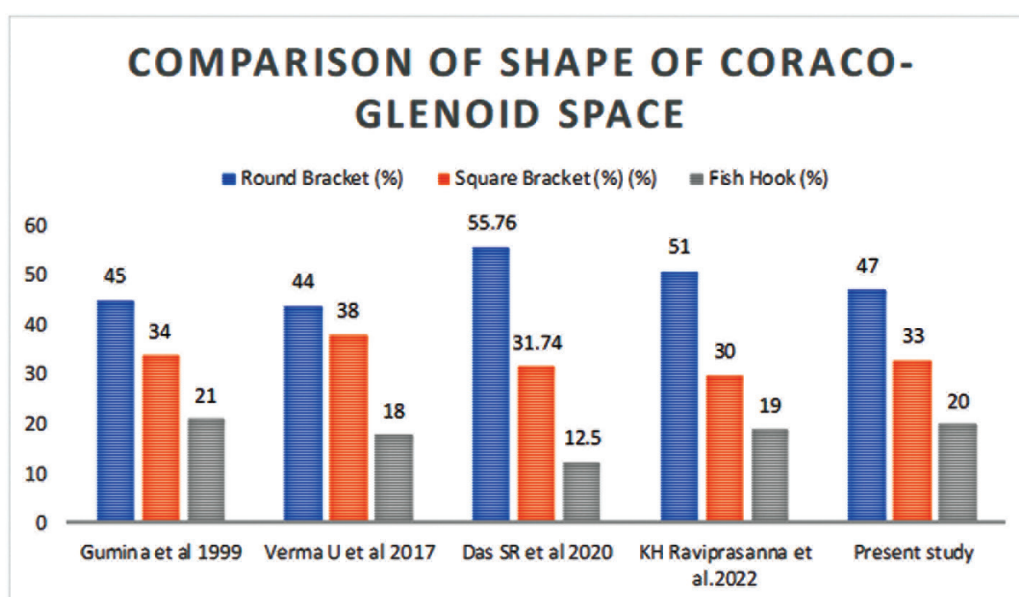
Table 3: Comparison of Coracoglenoid distance and Acromiocracoid distance in various Studies

Authors	Coracoglenoid distance (mm)	Acromiocracoid distance (mm)
Kavita et al 2013 <sup>[8]</sup>	23.3	23.3
Rajan et al 2014 <sup>[10]</sup>	22.9	27.53
El din et al 2015 <sup>[18]</sup>	31.3	-

Gosavi et al 2015 <sup>[19]</sup>	-	26.9
Kumar V et al 2018 <sup>[14]</sup>	26.23	-
Raviprasanna et al.2022 <sup>[17]</sup>	27.19	
Present study	25.34	28.65

**Table 4:** Comparison of shape of Coraco-glenoid space as seen documented in literature<sup>6,13,15,17</sup>

Author	Round Bracket (%)	Square Bracket (%)	Fish Hook (%)
Gumina et al 1999 <sup>[6]</sup>	45	34	21
Verma U et al 2017 <sup>[13]</sup>	44	38	18
Das SR et al 2020 <sup>[15]</sup>	55.76	31.74	12.5
Raviprasanna et al.2022 <sup>[17]</sup>	51	30	19
Present study	47	33	20



process. This is done to evade the neurovascular structures passing medially, such as the brachial plexus and axillary vessels. Besides, many important tendinous and ligamentous attachments are anchored here like tendons of the pectoralis minor, coracobrachialis, and short head of the biceps brachii muscles, and the coracoclavicular, coracohumeral, coracoacromial, and transverse scapular ligaments. Loss or damage of any of the above structures could lead to alterations in the structure of coracoid process.<sup>20</sup> Therefore, a more comprehensive study of the morphology of coracoid process is needed. Coracoid process is vital for functioning of scapula. It is like a control through which the muscles like biceps, coracobrachialis, and pectoralis minor employ a force over the glenoid. Although glenohumeral joint has the highest incidence of dislocation, injury of the coracoid process is quite infrequent. Hence

such injuries present a challenge for restoration by orthopaedic surgeons.<sup>21</sup> The incidence of coracoid process fracture is between 3% and 13% among all scapular fractures. The base of the coracoid is most commonly fractured. Arthroscopy of the shoulder or open surgery of the shoulder region involves the coracoid process. So, its morphometry is of pivotal importance in surgeries of the shoulder joint.<sup>22</sup> The outcomes of the present study establish the proportions of the coracoid process which can aid in finding the suitable approaches for repair of a coracoid fracture. The present morphometric study was carried out to assess the measurements of the coracoid process as well as Coracoglenoid distance and Acromiocracoid distance (Table 2). The difference in data between the right and left side was also documented so as to supplement as an anatomical reference for radiologists, orthopaedic surgeons, clinicians and researchers. The parameters

were also compared to that of other researchers (Table 3). The present study was consistent with previous data. The few discrepancies observed could be due to regional and racial differences. Although all parameters observed were higher on the right side compared to the left side, the differences were statistically insignificant. The length of the coracoid process ranged between 37 to 44 mm while the breadth ranged from 13.5 mm to 15.5 mm which was consistent with that observed in literature. The coracoglenoid distance in the present study ranged between 23 to 27.5 mm, although the maximum Coracoglenoid distance has been observed to be 31.3 by El din et al. The acromiocracoid distance ranged between 25.5 mm to 31.3 mm which was slightly higher than that seen in literature. Thus, it is apparent that the dimensions of the coracoid process in the present study show similarities with the earlier studies. As observed in literature and collaborated with our studies as well, shape of Coraco-glenoid space was found to be Type I - Round bracket in maximum cases followed by type II - Square bracket and low incidence of Type III - Fish hook (Table 1 & 4). The data will help the orthopaedic surgeons to comprehend aetiopathogenesis of subcoracoid impingement syndrome and its management. It will also be useful in medicolegal, anthropological and archaeological studies.<sup>23</sup>

### *Clinical Significance*

The coracoid process is an important element of the scapular glenoid construct. Variations in height and length of the coracoid process are assumed to be accountable for modification in the shape of the space between coracoacromial arch and rotator cuff. Knowledge of dimensions of the coracoid process is vital in cases of trauma, surgical interventions, replacement surgeries well as for diagnosis of various pathological conditions in the shoulder region.<sup>24,25</sup> The coracoid is involved in many surgical interventions on the glenohumeral joint, hence variant dimensions of the coracoid process are of importance for Radiologists and Orthopaedic surgeons for planning reparative procedures on the shoulder. The coracoacromial, coracoglenoid and acromioglenoid distances when precisely measured with palpable osseous landmarks become useful for portal placement during shoulder arthroscopic procedures.<sup>26</sup> While considering a etiology of shoulder pain, it is vital to bear in mind the Coracoacromial distance. A narrow gap is a risk factor for rotator cuff rupture.

Congenital variations and iatrogenic causes increase susceptibility to subcoracoid dislocation.<sup>27</sup>

## CONCLUSION

The outcomes of the present study establish the proportions of the coracoid process which can aid in finding the suitable approaches for repair of a coracoid fracture. Knowledge of dimensions of the coracoid process is vital in cases of trauma, surgical interventions, replacement surgeries well as for diagnosis of various pathological conditions in the shoulder region.

### *Authors' contributions*

VSS drafted the manuscript, SPS performed the literature review & SR assisted with writing the paper.

**Disclosure Statement:** There is no financial support for this research work from the funding agency.

**Conflict of interest:** None declared

**Ethical approval:** Not required

**Data and materials availability:** The data and materials used and analyzed during the current study are available from the corresponding author on reasonable request.

## ACKNOWLEDGEMENT

Authors are thankful to Dean Dr. Varsha Phadke Madam and teaching and non-teaching staff for their support and encouragement. Authors acknowledge the immense help received from the scholars whose articles are cited and included in references of this manuscript. The authors are also grateful to authors/editors/publishers of all those articles, journals and books from where the literature for this article has been reviewed and discussed.

## REFERENCES

1. Standring S. Gray's Anatomy: The Anatomical basis of clinical practice. Fortieth edition. London: Elsevier Ltd; 2008. p. 777-790.
2. Burkhart, S.S.; De Beer, J.F. Traumatic glenohumeral bone defects and their relationship to failure of arthroscopic Bankart repairs: Significance of the inverted-pear glenoid and the humeral engaging Hill-Sachs lesion. *Arthroscopy* 2000, 16, 677-694.
3. Latarjet, M. Treatment of recurrent dislocation of

- the shoulder. *Lyon Chir.* 1954, 49, 994-999.
4. Edwards, T.B.; Boulahia, A.; Walch, G. Radiographic analysis of bone defects in chronic anterior shoulder instability. *Arthroscopy* 2003, 19, 732-739.
  5. Gallino M, Santamaria E, Doro T. Anthropometry of the scapula: Clinical and surgical consideration. *J Should Elb Surg.* 1998;7(3):284-91.
  6. Gumina S, Postacchini F, Orsina L. The morphometry of the coracoid process- it's etiologic role in subcoracoid impingement syndrome. *Int Orthop.* 1999;23(4):198-201.
  7. Piyawinijwong S, Sirisathira N, Chuncharunee A. The Scapula: Osseous Dimensions and Gender Dimorphism in Thais. *Siriraj Hosp Gaz.* 2004; 56(7):356-65.
  8. Kavita P, Singh J, Morphology of Coracoid process and Glenoid cavity in adult human Scapulae. *Int J Analytical, Pharm Biomed Sci* 2013; 2(2): 19- 22.
  9. Pahuja K, Singh J. Morphology of coracoid process and glenoid cavity in adult human scapulae. *Int J Analytical Pharmaceutical and Biomedical Sci.* 2014;2(2):19-22.
  10. Rajan S, Ritika S, Kumar SR, Tripta S. Role of coracoid morphometry in subcoracoid impingement syndrome. *The Internet J Orthopedic Surg.* 2014;22(1):1-7.
  11. Kalra S, Thamke S. Morphometric analysis and surgical anatomy of coracoid process and glenoid cavity, *J Anatomical Soc of India* 2016;65: 114-117/19.
  12. Fathi M, Cheah PS, Ahmad U, et al. Anatomic Variation in Morphometry of Human Coracoid Process among Asian Population. *Biomed Res Int.* 2017; 2017:6307019.
  13. Verma U, Singroha R, Malik P, Kantha Rathee S. A study on morphometry of Coracoid process of Scapula in North Indian population. *Int J Res Med Sci.*2017;5(11):4970-74.
  14. Kumar V, Kohli M, Mehta V, Suri RK. Osteometric assessment of coracoid process of scapula- Clinical implications. *Journal of Surgical Academia.* 2018;8(2):03-10.
  15. Das SR, Champatray S, Nayak G, Panda S. Morphometric analysis of coracoid process in adult human scapula in eastern Odisha population. *Indian Journal of Forensic Medicine and Toxicology.* 2020;14(4):8476-81.
  16. Khan R, Satyapal KS, Lazarus L, Naidoo N. An anthropometric evaluation of the Scapula, with emphasis on the coracoid process and glenoid fossa in a South African population. *Heliyon.* 2020;6(1).
  17. Raviprasanna et al., Morphometry of Coracoid Process of Scapula, *International Journal of Anatomy, Radiology and Surgery.* 2022 Apr, Vol-11(2).
  18. El-Din WA, Ali MH. A Morphometric Study of the Patterns and Variations of the Acromion and Glenoid Cavity of the Scapulae in Egyptian Population. *J Clin Diagn Res.* 2015; 9(8).
  19. Gosavi S, Jadhav S, Garud R. Morphometry of acromion process: A study of Indian scapulae. *Int J Pharma Res Health Sci.* 2015;3(5):831-5.
  20. Matsen FA, Thomas SC, Rockwood CA. Anterior glenohumeral instability. In: *The shoulder.* Rockwood CA, Matsen FA, editors. Philadelphia. WB Saunders; 1990. p. 336-67.
  21. Coskun N, Karaali K, Cevikol C, Demirel BN, Sindel M. Anatomical basics and variations of the scapula in Turkish adults. *Saudi Med J.* 2006;27(9): 1320-5.
  22. Bhatia DN, de Beer JF, du Toit DF. Coracoid process anatomy: implications in radiographic imaging and surgery. *Clin Anat.* 2007;20(7):774-84.
  23. Salzmänn, G.M.; Paul, J.; Sandmann, G.H.; Imhoff, A.B.; Schöttle, P.B. The coracoid insertion of the coracoclavicular ligaments: An anatomic study. *Am. J. Sports Med.* 2008, 36, 2392-2397.
  24. Ji, J.H.; Kwak, D.S.; Yang, P.S.; Kwon, M.J.; Han, S.H.; Jeong, J.J. Comparisons of glenoid bony defects between normal cadaveric specimens and patients with recurrent shoulder dislocation: An anatomic study. *J. Shoulder Elbow Surg.* 2012, 21, 822-827.
  25. Bhatia, S.; Frank, R.M.; Ghodadra, N.S.; Hsu, A.R.; Romeo, A.A.; Bach, B.R., Jr.; Boileau, P.; Provencher, M.T. The outcomes and surgical techniques of the Latarjet procedure. *Arthroscopy* 2014, 30, 227-235.
  26. Kraus, T.M.; Martetschläger, F.; Graveleau, N.; Klouche, S.; Freude, T.; Stöckle, U.; Hardy, P. CT-based quantitative assessment of the surface size and en-face position of the coracoid block post-Latarjet procedure. *Arch. Orthop. Trauma Surg.* 2013, 133, 1543-1548.
  27. Edelson JG, Taitz C. Anatomy of the coracoacromial arch. Relation to degeneration of the acromion. *J Bone Joint Surg Br.* 1992; 74: 589-94.
- 
-